

# Shift in skin microbiota of children with atopic dermatitis after topical gentian violet application

Joanna Krzysiek<sup>1</sup>, Joanna Żurawska-Olszewska<sup>2</sup>, Izabela Szczerba<sup>2</sup>, Aleksandra Lesiak<sup>1</sup>,  
Dorota Pastuszek-Lewandoska<sup>2</sup>, Janina Grzegorzczak<sup>2</sup>, Magdalena Ciężyńska<sup>1,2</sup>, Joanna Narbutt<sup>1</sup>

<sup>1</sup>Department of Dermatology, Pediatric and Oncology Dermatology, Medical University of Lodz, Lodz, Poland

<sup>2</sup>Microbiology and Laboratory Medical Immunology, Medical University of Lodz, Lodz, Poland

Adv Dermatol Allergol 2023; XL (2): 308–314

DOI: <https://doi.org/10.5114/ada.2023.126534>

## Abstract

**Introduction:** Increasing usage of antimicrobial agents may contribute to bacterial resistance in atopic dermatitis (AD). In this case an alternative topical treatment might be gentian violet (GV), suggested for its antibacterial and antifungal properties.

**Aim:** To assess the microbial composition of lesional skin in children with AD and a control group aged 2–12 years, before and after 3 days of 2% aqueous GV application.

**Material and methods:** Skin samples were taken from 30 AD patients and 30 healthy controls aged 2–12 years. The procedure was done two times – before and after 3 days of 2% aqueous GV application. The material was collected from skin lesions in the cubital fossa using 25 cm<sup>2</sup> impression plates, containing CHROMagar Staph aureus and CHROMagar Malassezia. After the incubation period, the grown colonies were counted and identified by the Phoenix BD testing system.

**Results:** The results revealed a statistically significant reduction in total counts of bacteria in both groups of children after GV application ( $p < 0.05$ ). The significant decrease in the number was seen in *Staphylococcus* spp. (*S. aureus*, *S. capitis*, *S. haemolyticus*, *S. cohnii*) in AD patients. The number of *Staphylococcus* spp. was comparable in patients with AD after GV treatment and healthy patients before GV exposure ( $p = 1.000$ ).

**Conclusions:** Our study results show that GV does not damage the skin surface ecosystem and allows the reduction of excessive bacterial counts on eczematous lesions to a ‘safe’ level, similar to that of healthy children.

**Key words:** atopic dermatitis, microbiome, gentian violet.

## Introduction

Atopic dermatitis (AD) is a condition which highly affects the children presenting with chronic and recurrent skin lesions with pruritus. These lesions highlight clinically several pillars of its pathogenesis such as the loss of skin barrier integrity, microbiome dysbiosis, changes in the innate and adaptive immune responses [1]. The damage in the skin barrier is caused by changes in stratum corneum lipid composition, loss-of-function mutation in the filaggrin gene and additionally, disruption of host microbiota.

The contribution of microbiota to human health and disease still remains entirely unexplored. It is known that microorganisms creating the human microbiome are necessary for the proper functioning, including maintaining the immune status of the macroorganism [2, 3]. Current-

ly, the term “microbiota” means all of the microorganisms, i.e. bacteria, fungi, viruses and archaea, inhabiting ecological niche [4]. Overall, microbiota can form functionally complex structures, capable of communicating with each other and with the host.

The microbiome is altered in AD. During flares there is an increased count of *Staphylococcus aureus* (*S. aureus*) and reduced microbiome diversity. The most known pathogen aggravating inflammatory lesions is *S. aureus*. Its colonization on both lesional and non-lesional skin prove importance in severity of AD [5]. *S. aureus* expresses molecules including  $\delta$ -toxin,  $\alpha$ -toxin, protein A, superantigens and lipoproteins that may cause direct cell damage triggering inflammatory response [6].

The inhibition in production of antimicrobial peptides in the defected AD skin can lead not only to bacterial but also viral and fungal infections [7]. Lately, a possible

---

**Address for correspondence:** Prof Joanna Narbutt, Department of Dermatology, Pediatric and Oncology Dermatology, Medical University of Lodz, Poland, phone: +48 603 756 804, e-mail: [joanna.narbutt@umed.lodz.pl](mailto:joanna.narbutt@umed.lodz.pl)

**Received:** 22.11.2022, **accepted:** 9.12.2022.

This is an Open Access article distributed under the terms of the Creative Commons Attribution-NonCommercial-ShareAlike 4.0 International (CC BY-NC-SA 4.0) License (<http://creativecommons.org/licenses/by-nc-sa/4.0/>)

role of *Malassezia* species has been suggested in exacerbation of skin lesions. These fungi activate Th2 immune response in the disrupted epidermal barrier via human dendritic cells or keratinocytes, which exacerbate skin lesions in AD [8]. It is recommended to use antifungal agents in the coexisting fungal infection on AD skin. On the other hand, bacterial infection is managed with both antibiotics and antiseptics. Due to the growing problem with bacterial resistance to antibiotics, antiseptics seem to be a safer alternative in therapy. Topical use of dyes could be an interesting option for antimicrobial measures. One of the substances that has been used since the 19<sup>th</sup> century is gentian violet (GV). It is known for its antibacterial, antifungal, antihelminthic, antitrypanosomal and antiviral activities. Claims of GV efficacy have been widely visible in treatment of many diseases especially in dermatology for example in impetigo [9], wound healing [10], paronychia, thrush, angular cheilitis or umbilical infection [11]. However, some of the data show evidence of genotoxic and carcinogenic mode of action in the mouse and rat studies [12]. Lately, the Food and Drug Administration (FDA) has prohibited to use GV in animal feed [13]. The FDA has issued alerts for domestic and imported seafood for GV content from a number of countries. Nevertheless, human testing on the mutagenic effect of gentian violet is sparse. The clinical practice has shown long-time observation of its effectiveness in topical use of 1–2% solution of this dye. This study aims to evaluate the influence of 2% GV aqueous solution on the selected bacteria and fungi on AD skin.

### Aim

The aim of this study was to assess changes of skin microbiome after topical 2% aqueous GV use in patients with atopic dermatitis and the control group. We also analysed microbial composition in AD subjects before the treatment.

### Material and methods

All parents or guardians of the subjects gave written informed consent prior to participation. For the study, 60 participants (2–12 years old) were voluntarily recruited. Recruitment of the patients with atopic dermatitis took place in the Department of Dermatology, Paediatric and Oncologic Dermatology, Lodz Medical University. The first 30 patients were hospitalized at the ward due to AD. The other 30 controls (healthy subjects) were selected randomly during the same period as AD patients and matched for age, gender and ethnicity. Exclusion criteria were the same as those applied to patients with AD. Subjects were excluded from study participation if they used topical or systemic glucocorticosteroids for 2 weeks, topical or oral antibiotics for 2 weeks or any immunosuppressive and immunomodulatory treatment prior to

the study. Patients with neoplasms or active infectious disease were excluded as well.

Thirty patients with AD were diagnosed according to the criteria of Hanifin and Rajka. Clinical evaluation of severity of the atopic eczema was measured with the Scoring Atopic Dermatitis (SCORAD), Eczema Area and Severity Index (EASI) and Investigator Global Assessment (IGA) index. The patients were screened regarding the onset age, duration of disease, and the number of exacerbations during the year.

The material for microbiological testing was collected from eczematous skin lesions on antecubital fossae by using 25 cm<sup>2</sup> impression plates. The agar surface was pressed against the designated lesions with the same pressure. The impression plates have convex surfaces that adhere closely to the tested skin area. Furthermore, 2% aqueous GV was applied on the decubital fossa. The dye was used twice daily for the same area. No emollients were applied on the examined skin area during the study. After 3 days, the impression plate adherence was repeated for the same region. Two types of plates were used: CHROMagar Staph aureus and CHROMagar Malassezia. The first chromogenic medium determined the count and initial identification of aerobic Gram-positive cocci. CHROMagar Malassezia enabled the occurrence and isolation of fungi. Both types of media were incubated according to the manufacturer's instructions and microbiological standards: 48 h at 35.5°C. The media detecting fungi were analysed, followed by prolonged incubation for another 48 h in case of absent strains. On the basis of the pigmented phenotype, both bacterial and fungal colonies grown were counted. Numbers were expressed as CFU (colony forming unit) per 25 cm<sup>2</sup>.

The Phoenix BD apparatus was used for the identification of cultured microorganisms.

### Statistical analysis

For statistical purposes, 60 patients in the study were divided into four subgroups as follows:

- Subgroup 1: AD patients before the application of 2% aqueous GV,
- Subgroup 2: AD patients after the application of 2% aqueous GV,
- Subgroup 3: control group before the application of 2% aqueous GV,
- Subgroup 4: control group after the application of 2% aqueous GV.

The Shapiro-Wilk test was used for the evaluation of normality. The differences between the groups were assessed using Mann-Whitney *U* test. Statistically significant differences between the subgroups were presented graphically in the charts. The Kruskal-Wallis test was carried out to check the differences between the four study subgroups. If the result of the Kruskal-Wallis test was statistically valid, the Dunn test was additionally performed. Spearman's correlation was used to find

relationships between the number of bacteria and other continuous variables. Significance levels for all analyses conducted were  $p < 0.05$ . The Statistica software (v.6.0 Statsoft, Tulsa, OK, USA) was used for statistical analyses.

## Results

Sixty patients (30 with AD, 30 control group) aged from 2 to 12 years, were enrolled in the study (51.67% were boys). The median age of AD patients was 6.8 years and in the control group 8.7 years ( $p > 0.05$ ). The median AD duration was 2.95 months. All patients at the time of enrolment had moderate skin symptoms; the

median IGA score was 3 (2–4), EASI was 11.4 (3.4–26.5) and SCORAD was 45.9 (19.3–68.6). Low-potency corticosteroid medicinal products prepared on the basis of a magistral formula were commonly used in 83.33% of cases as initial therapy on all eczematous areas at least 2 weeks prior to the study enrolment. The most common medicinal product applied by the patients was 1% hydrocortisone ointment.

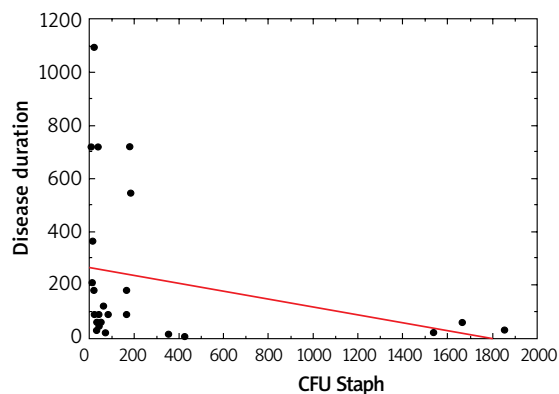
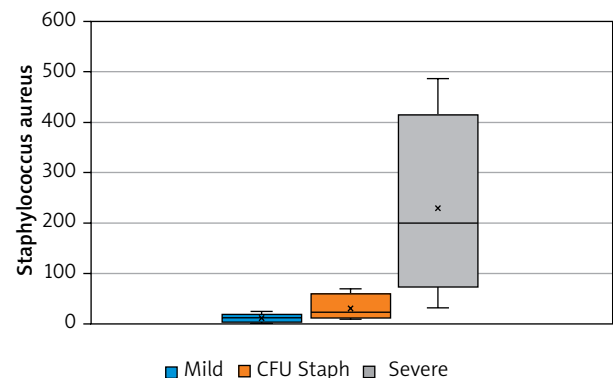
In all 60 patients we have identified bacterial species such as *Staphylococcus* spp., *Micrococcus* spp. and bacteria of the Gram-positive family (Tables 1 and 2). In both groups *Malassezia* spp. and *Staphylococcus* spp. were present on the skin. However, in the AD group there was a noticeable diversity in strains of *Staphylococcus* spp.

**Table 1.** Skin microbiota changes before and after application of the gentian violet in AD patients

Genus of bacteria	Concentration of bacteria (number/25 cm <sup>2</sup> ) on AD skin before GV application (subgroup 1) Median (25–75%)	Concentration of bacteria (number/25 cm <sup>2</sup> ) on AD skin after GV application (subgroup 2) Median (25–75%)	Wilcoxon test* P-value*
Total count	98.0 (51.0–225.0)	28.0 (18.0–50.0)	< 0.0001
CFU <i>Staphylococcus</i>	41.0 (17.0–165.0)	11.5 (5.0–25.0)	< 0.0001
CFU <i>Micrococcus</i>	13.5 (3.0–60.0)	9.0 (3.0–19.0)	< 0.0001
<i>Micrococcus</i> spp.	14.5 (3.0–60.0)	9.0 (3.0–19.0)	< 0.0001
<i>M. luteus</i>	3.0 (0.0–17.0)	9.0 (4.0–19.0)	< 0.0001
<i>M. lylae</i>	1.5 (0.0–19.5)	9.5 (4.0–19.0)	0.0002
<i>Kocuria varians</i>	2.0 (2.0–2.0)	3.0 (3.0–3.0)	0.2249
<i>Dermacoccus nishinomiyaensis</i>	4.0 (0.0–8.0)	1.0 (1.0–1.0)	0.2626
<i>S. aureus</i>	11.0 (0.0–61.0)	9.0 (3.0–29.0)	< 0.0001
<i>S. warneri</i>	0.0 (0.0–3.0)	3.0 (2.0–9.0)	0.0574
<i>S. capitis</i>	3.0 (0.0–10.0)	4.0 (3.0–11.0)	< 0.0001
<i>S. haemolyticus</i>	30.0 (7.0–232.0)	6.0 (2.0–16.0)	0.0001
<i>S. cohnii</i>	3.0 (1.0–1.0)	1.0 (1.0–1.0)	0.0464
<i>S. simulans</i>	11.0 (6.0–16.0)	4.5 (2.0–7.0)	0.1159
<i>S. equorum</i>	10.0 (10.0–10.0)	3.0 (3.0–3.0)	0.1797
<i>S. pasteurii</i>	6.0 (5.0–7.0)	5.0 (5.0–5.0)	0.0007
<i>S. epidermidis</i>	11.0 (5.0–7.0)	5.0 (3.0–8.0)	0.0033
<i>S. lugdunensis</i>	60.0 (60.0–60.0)	1.0 (1.0–1.0)	1.0000
<i>Staphylococcus</i> spp. without <i>S. aureus</i>	16.5 (8.0–52.0)	1.0 (1.0–1.0)	0.0000
Rest of Gram-positive <i>Staphylococcus</i> spp.	0.0 (0.0–0.0)	5.5 (2.0–16.0)	0.1462
<i>Lactococcus garvieae</i>	3.0 (3.0–3.0)	0.0 (0.0–0.0)	0.1115
Gram-positive bacteria	0.0 (0.0–1.0)	3.0 (3.0–3.0)	0.2536
<i>Leifsonia aquatica</i>	12.0 (1.0–23.0)	21.0 (21.0–21.0)	0.1797
<i>Brevibacterium</i> spp.	1.0 (1.0–1.0)	0.0 (0.0–1.0)	0.0000
<i>Corynebacterium urealyticum</i>	1.0 (1.0–1.0)	4.0 (2.0–15.0)	< 0.0001
<i>Cellulosimicrobium cellulans</i>	152.0 (152.0–152.0)	17.0 (13.0–21.0)	0.1088
<i>Malassezia</i> spp.	1.5 (1.0–4.0)	4.0 (4.0–4.0)	0.8336

**Table 2.** Skin microbiota changes before and after application of the gentian violet in the control group

Genus of bacteria	Concentration of bacteria (number/25 cm <sup>2</sup> ) in the control group before GV application (subgroup 3)	Concentration of bacteria (number/25 cm <sup>2</sup> ) in the control group after GV application (subgroup 4)	Wilcoxon test* P-value*
	Median (25–75%)	Median (25–75%)	
Total count	52.5 (24.0–87.0)	41.0 (12.0–137.0)	< 0.0001
CFU <i>Staphylococcus</i>	24.5 (4.0–50.0)	9.5 (3.0–32.0)	< 0.0001
CFU <i>Micrococcus</i>	6.5 (3.0–49.0)	9.5 (0.0–35.0)	< 0.0001
<i>Micrococcus</i> spp.	18.0 (4.0–49.0)	11.5 (4.0–64.0)	< 0.0001
<i>M. luteus</i>	18.0 (4.0–60.0)	13.5 (9.0–85.5)	< 0.0001
<i>M. lylae</i>	24.0 (24.0–24.0)	2.0 (2.0–2.0)	0.0002
<i>Kocuria varians</i>	9.5 (1.0–18.0)	8.5 (4.0–13.0)	0.2249
<i>Dermaococcus nishinomiyaensis</i>	40.0 (40.0–40.0)	64.0 (64.0–64.0)	0.2626
<i>S. aureus</i>	5.0 (3.0–30.0)	1.0 (1.0–1.0)	< 0.0001
<i>S. warneri</i>	8.0 (1.0–16.0)	1.5 (1.0–3.5)	0.0574
<i>S. capitis</i>	5.0 (3.0–30.0)	5.0 (2.0–9.0)	< 0.0001
<i>S. haemolyticus</i>	2.0 (1.0–40.0)	15.0 (3.0–45.0)	0.0001
<i>S. kloosii</i>	2.0 (2.0–2.0)	5.0 (3.0–11.5)	0.0464
<i>S. pettenkoferi</i>	7.0 (5.0–30.0)	1.0 (1.0–1.0)	0.1380
Other Gram-positive <i>Staphylococcus</i> spp.	1.0 (1.0–1.0)	1.0 (1.0–1.0)	0.1462
<i>Lactococcus garvieae</i>	24.5 (4.0–50.0)	3.0 (1.0–5.0)	0.1115
<i>Brevibacterium</i> spp.	0.0 (0.0–0.0)	0.0 (0.0–0.0)	< 0.0001
<i>Corynebacterium urealyticum</i>	2.5 (2.0–3.0)	0.0 (0.0–0.0)	< 0.0001
<i>Malassezia</i> spp.	1.0 (0.0–2.0)	0.0 (0.0–0.0)	< 0.0001

**Figure 1.** The correlation between CFU Staph and disease duration in AD children ( $p < 0.05$ )**Figure 2.** Relationship between the severity of the disease (according to scoring systems – IGA, EASI, and SCORAD) and the number of *Staphylococcus aureus* CFU ( $p < 0.05$ )

Moreover, *Staphylococcus* spp. was associated with the duration of disease ( $p > 0.05$ , Figure 1). The number of *S. aureus* on lesional skin positively correlated with the severity of disease according to validated scoring systems such as IGA, EASI, SCORAD ( $p < 0.05$ , Figure 2). However, there was no relation between *S. aureus* count, severity of disease and age ( $p > 0.05$ ).

Total bacteria counts were statistically decreased after GV treatment in both groups ( $p < 0.05$ ). The significant reduction in the number was seen in *Micrococcus* spp. (*M. luteus*, *M. lylae*), *Staphylococcus* spp. (*S. aureus*, *S. capitis*, *S. haemolyticus*, *S. cohnii*) in AD patients. The Kruskal-Wallis global test was used in all 4 study subgroups to determine the differences in the number of

**Table 3.** Correlation between CFU of *Staphylococcus* spp. in 4 study groups (*p*-values)

	Subgroup 11	Subgroup 22	Subgroup 33	Subgroup 44
Subgroup 11		0.3225	0.0132	0.0042
Subgroup 22	0.3225		1.0000	0.8685
Subgroup 33	0.0132	1.0000		0.8859
Subgroup 44	0.0042	0.8685	0.8859	

<sup>1</sup>AD patients before the application of GV, <sup>2</sup>AD patients after 3 days of application of GV, <sup>3</sup>Control group before the application of GV, <sup>4</sup>Control group after 3 days of application of GV.

each bacterium. It was observed that the *Staphylococcus* spp. population was decreased in the all subgroups ( $p < 0.0089$ ). Dunn's test pinpointed a statistically significant difference in the number between subgroup 1 and 3 ( $p < 0.0132$ ), while the *Staphylococcus* spp. count was maintained in subgroup 2 and 3 ( $p = 1.000$ ) (Table 3).

All the subjects included in the study tolerated the treatment very well. There were no side effects observed.

## Discussion

GV as a triphenylmethane rosaniline dye has been known for decades. The pioneer study evaluating its bactericidal and fungicidal property was reported in 1912 by Churchman [14]. In animals, GV has been used for treatment of fungal and parasitic infections in fish and topically for eye infection in livestock [15]. The antimycotic properties were also proven in several studies. It has been demonstrated that GV lowers the adherence of *Candida* spp. to the catheters [16]. A randomized unblinded study on the treatment of oropharyngeal and oesophageal candidiasis that was conducted among 141 patients with AIDS and oropharyngeal candidiasis showed comparable effectiveness of GV to ketoconazole [17]. Even though numerous studies were conducted, there were no data of its influence on *Malassezia* spp. This genus of yeasts is attributed with both commensal and pathogenic role in AD. Jensen-Jarolim *et al.* isolated these yeasts from eczematous lesions on the neck and head [18]. The reason why these yeast were present on eczematous lesions might be their overexpression of phospholipases and lipases [19]. They could damage the epidermal barrier in AD patients inducing a pro-inflammatory immune response by the skin and immune cells. In spite of natural attraction towards seborrheic areas and skin folds, our study showed limited strains of *Malassezia* spp. in decubital fossa but it was below a statistical significance threshold. The condition could find the reason in excessive dryness of the skin lesions and bacterial flora domination. Our experiment shows that after GV exposure there was no growth of the *Malassezia* population on AD skin, with a reduction in the number of colonies in the control group. A small number

of patients included in our study and single colonies isolated from eczematous lesions do not allow to draw unequivocal conclusions about the antifungal activity of GV on *Malassezia* spp.

The antibacterial action of GV has been more acquainted [20]. The most common hypothesis suggests the inhibition of bacterial cell wall formation, glutamine synthesis suppression by blocking glutamic acid metabolism in the pathogens, protein synthesis blockade due to the dye binding to ribosomes, alteration of the redox potential or targeting NADPH oxidase and thioredoxin reductase 2 in microbial cells [21]. In the literature there are several studies describing positive bactericidal properties of the dye. Brockow *et al.* showed the reduction of *S. aureus* density after applying 0.3% aqueous gentian violet in AD patients [22]. The results of this study are in accordance with the authors' observation that faster clearance of AD is achieved, when GV is added to a potent topical corticosteroid. This combination might be helpful in minimizing side effects of steroids. In our study, we discovered a significant *S. aureus* reduction after 3 days of 2% aqueous GV application.

It has been demonstrated that the microbial composition of AD skin dominates in *S. aureus* in comparison to healthy skin [23]. Our investigation confirmed that before GV application, there was a significant number of *S. aureus* on AD skin. *S. aureus* was positively associated with disease severity. Moreover, there was an inverse correlation between the *S. aureus* number and the length of disease. This may contribute to enhancement of flare development and skin barrier impairment progression caused by *S. aureus* in the early AD phase. In contrast, Totte *et al.* noticed no relation between *S. aureus* and AD severity in children aged 0–18 years [24]. The sites of flares in AD children vary, depending on age, which could inflict the differences in the results of the study. Our AD population comprised only 30 subjects aged 2–12 years, yet the samples were collected from decubital fossa, the most common affected site for this age group. Next to severity, age of the AD patients did not show any correlation with the number of *S. aureus*. There was a number of studies investigating the skin microbiome in AD in different age groups. Meylan *et al.* discovered *S. aureus* density remarkably greater on axillary and decubital fossa at the time of diagnosis in AD children under the age of 2. However, it was significantly lower than in older AD population [25]. On the contrary, Zheng *et al.* found similar bacterial microbiome on the same area in infants with AD and age-matched healthy controls [26]. A more consistent study in anatomical site sampling is needed on a larger population to estimate the age-specific risk factor for *S. aureus* in AD.

It has been described that the *S. aureus* virulence is enhanced by the native and commensal microbiome of the skin and individual species acting as “pro-infective agents” [27]. The bacteria which were considered to be the per-

manent microbiome of the skin are *Micrococcus* spp. [28, 29]. In 2018 Boldock *et al.* showed that *Micrococcus luteus* (*M. luteus*) [27] enhanced the activity of *S. aureus* in a mouse model [30]. The study proved that commensal bacteria may actually help pathogens evade the immune system. This discovery prompted scientists to investigate components of the *M. luteus* cell wall, such as peptidoglycan, for their ability to influence hosts' immunity. In an animal model, the authors showed that the polymer also exacerbated infection with both drug-resistant and drug-sensitive strains of *S. aureus*. The researchers also found that *M. luteus* secreted a small resuscitation-promoting factor (RPF) protein, which stimulated the growth of bacteria such as *Staphylococcus* spp. An "extended infection" hypothesis was formulated to define the role of resident environmental microflora in disease caused by an invasive pathogen. In the light of the above, we believe that under the specific conditions in damaged AD skin, multi-species biofilm may appear. We suggest that under these circumstances *M. luteus* can protect *S. aureus* by "hiding" it from the effects of targeted drugs or bacterial factors. In our study GV decreased the number of Gram-positive bacteria and resulted in the bacteria reduction to the level in which the biofilm was either destroyed or significantly damaged. To confirm this hypothesis, it is necessary to conduct a study on a larger group of patients who would be repeatedly tested both microbiologically and immunologically [30].

The population of *Staphylococcus* spp. includes at least 40 species that inhabit both healthy skin and AD skin. Our study revealed a significant diversity in staphylococcal composition in comparison to healthy subjects. We noticed *S. aureus*, *S. warneri*, *S. capitis*, *S. haemolyticus*, *S. cohnii*, *S. simulans*, *S. equorum*, *S. pasteurii*, *S. epidermidis* and *S. lugdunensis* on the antecubital area of the AD skin. Many studies show the possible bactericidal role of *Staphylococcus epidermidis*, *S. lugdunensis* and *S. hominis* in limiting the number of the *S. aureus* in AD [31, 32]. Moreover, a recent paper of Cau *et al.* suggested that *S. epidermidis* can damage the skin similarly to *S. aureus* by production of cysteine protease [32]. Another study group observed co-colonization of *S. capitis* and *S. lugdunensis* in the decubital crease of adult AD skin, correlation with the disease severity and proportional reduction in the number of *S. hominis* and *S. cohnii* [33]. The number of bacteria in this study was estimated in adult population, which can differ from paediatric patients.

Our results indicated a decrease in the count of not only *S. aureus* but also *S. capitis*, *S. haemolyticus*, *S. cohnii* and *S. kloosii* in AD patients after GV exposure. Additionally, we have discovered a comparable number of *Staphylococcus* spp. between the AD group after the GV treatment and the control group before the GV treatment. This may suggest that GV does not damage the skin surface ecosystem and allows the reduction of excessive bacte-

rial counts to a "safe" level, i.e. close to that of healthy children. Disruption of the resident microbiota of the skin is often seen after the use of antibiotics. SanMiguel *et al.* have stated that topical antibiotics elicit shifts to resident skin bacterial communities and reduce colonization by *S. aureus* competitors [34]. They found that both antiseptics and antibiotics decrease colonization by commensal *Staphylococcus* spp. However, antiseptics elicited only minor changes to skin bacterial populations, with few changes to the underlying microbiota. A similar effect was represented by GV in our study.

GV is normally used in concentrations ranging from 0.5% to 2%. The toxicity of the dyes in higher concentrations (1% or 2%) was observed in the literature [35]. No side effect after GV use was observed in either of our studied groups. The GV is available in two forms: aqueous and spirit solution. In our research we used a concentration of 2% in aqueous solutions. However, it should be applied with care on skin folds, preferably in a lower concentration due to the risk of necrotic reactions [36]. GV-induced toxicity including carcinogenicity and genotoxicity has been documented in the scientific literature [15]. But only one of the published studies was conducted using the topical route of exposure. In a prospective study analysing the effects of methylene blue and violet gentian in dressings for the treatment of chronic wounds and local infections it was found that the use of Hydrofera Blue Dressing did not increase the risk of developing cancer [37]. The intensity of the carcinogenic effect in animals, induced by GV, has been noted as dose-dependent [38]. When the dye is applied topically on large surface areas and muco-cutaneous lesions, systemic absorption may occur. In the light of the above, we suggest avoiding oral exposure to the substance and not using it on a large body surface. Our research aimed to screen the mechanism of GV action towards skin microbiome representatives such as *Staphylococcus* spp., *Micrococcus* spp., and *Malassezia* spp., not for its mutagenic activities. As for many new therapeutic options in AD, GV may be used as an alternative antibiotic-sparing therapy but with caution.

## Acknowledgments

The protocol was approved by the ethics committee of the Medical University of Lodz (Lodz, Poland).

This investigation was supported by the Medical University of Lodz (Poland) grant (number 502-03/5-064-01/502-54-180).

## Conflict of interest

The authors declare no conflict of interest.

## References

1. Bieber T, Akdis C, Lauener R, et al. Global Allergy Forum and 3rd Davos Declaration 2015: Atopic dermatitis/Eczema: challenges and opportunities toward precision medicine. *Allergy* 2016; 71: 588-92.
2. Adamiak M, Sliwa-Dominiak J, Bak K, et al. Commensal bacteria and immunity of the gastrointestinal, respiratory and genitourinary tracts. *Adv Hyg Exp Med* 2016; 70: 599-609.
3. Duerkop BA, Hooper LV. Resident viruses and their interactions with the immune system. *Nat Immunol* 2013; 14: 654-9.
4. Rakowska M, Lichosik M, Kacik J, Kalicki B. Wpływ mikrobioty na zdrowie człowieka. *Pediatr Med Rodz* 2016; 12: 404-12.
5. Leung D. Role of *Staphylococcus aureus* in atopic dermatitis. In: *Atopic Dermatitis*. Vol. 1. Bieber TL (ed.). Marcel Dekker, New York 2002; 401-18.
6. Geoghegan JA, Irvine AD, Foster TJ. *Staphylococcus aureus* and atopic dermatitis: a complex and evolving relationship. *Trends Microbiol* 2018; 26: 484-97.
7. Ong PY, Ohtake T, Brandt C, et al. Endogenous antimicrobial peptides and skin infections in atopic dermatitis. *N Engl J Med* 2002; 347: 1151-60.
8. Thammahong A, Kiatsurayanon C, Edwards SW, et al. The clinical significance of fungi in atopic dermatitis. *Int J Dermatol* 2020; 59: 926-35.
9. Peterkin GAG, Jones EC. Impetigo in the services. *Br Med J* 1943; 318: 14.
10. Stiff KM, Glines KR, Muse ME, et al. Gentian violet for pyoderma gangrenosum: a retrospective chart review. *Dermatol Online J* 2020; 26: 13030/qt3sm8q75w.
11. Balabanova M, popova L, Tchipeva R. Dyes in dermatology. *Clin Dermatol* 2003; 21: 2-6.
12. The Office of Environmental Health Hazard Assessment (OEHH) California Environmental Protection Agency. Evidence on the Carcinogenicity of Gentian Violet. 2018; 65: 1-117.
13. U.S. The Food and Drug Administration. Sec. 589.1000 Gentian violet. CFR - Code of Federal Regulations Title 21. Department of Health and Human Services. 2022: part 589.
14. Churchman JW, Howard Michael W. The selective action of gentian violet on closely related bacterial strains. *J Exp Med* 1912; 16: 822-30.
15. JECFA. Toxicological Evaluation of certain veterinary drug residues in food. 78<sup>th</sup> meeting of the joint FAO/WHO expert committee of food additives. 2014: 1-237.
16. Chaiban G, Hanna H, Dvorak T, et al. A rapid method of impregnating endotracheal tubes and urinary catheters with gendine: a novel antiseptic agent. *J Antimicrob Chemother* 2005; 55: 51-6.
17. Nyst MJ, Perriens JH, Kimputu L, et al. Gentian violet, ketoconazole and nystatin in oropharyngeal and esophageal candidiasis in Zairian AIDS patients. *Ann Soc Belg Med Trop* 1992; 72: 45-52.
18. Jensen-Jarolim E, Poulsen LK, With H, et al. Atopic dermatitis of the face, scalp, and neck: type I reaction to the yeast *Pityrosporum ovale*? *J Allergy Clin Immunol* 1992; 89: 44-51.
19. Nowicka N, Nawrot U. Contribution of *Malassezia* spp. to the development of atopic dermatitis. *Mycoses* 2019; 62: 588-96.
20. Docampo R, Moreno SNJ. The metabolism and mode of action of gentian violet. *Drug Metab Rev* 1990; 22: 161-6.
21. Maley AM, Arbiser JL. Gentian violet: a 19th century drug re-emerges in the 21st century. *Exp Dermatol* 2013; 22: 775-80.
22. Brockow K, Grabenhorst P, Abeck D, et al. Effect of gentian violet, corticosteroid and tar preparations in *Staphylococcus aureus*-colonized atopic eczema. *Dermatology* 1999; 199: 231-6.
23. Edslev SM, Agner T, Andersen PS. Skin microbiome in atopic dermatitis. *Acta Derm Venereol* 2020; 100: adv00164.
24. Totte JE, van der Feltz WT, Hennekam M, et al. Prevalence and odds of *Staphylococcus aureus* carriage in atopic dermatitis: a systematic review and meta-analysis. *Br J Dermatol* 2016; 175: 687-95.
25. Meylan P, Lang C, Mermoud S, et al. Skin colonization by *staphylococcus aureus* precedes the clinical diagnosis of atopic dermatitis in infancy. *J Invest Dermatol* 2017; 137: 2497-504.
26. Zheng Y, Wang Q, Ma L, et al. Alterations in the skin microbiome are associated with disease severity and treatment in the perioral zone of the skin of infants with atopic dermatitis. *Eur J Clin Microbiol Infect Dis* 2019; 38: 1677-85.
27. Boldock E, Surewaard BGJ, Szamara D, et al. Human skin commensals augment *Staphylococcus aureus* pathogenesis. *Nat Microbiol* 2018; 3: 881-90.
28. Szczerba I. Występowanie i liczebność bakterii z rodzajów *Micorococcus*, *Kocuria*, *Nesterenkonina*, *Kytococcus* i *Derma-coccus* na skórze i błonach śluzowych u ludzi. *Med Dośw Mikrobiol* 2003; 55: 67-74.
29. Szczerba I. Mikrokokki jako czynnik zakażeń oportunistycznych. *Przegl Epidemiol* 2000; 54: 385-92.
30. Nakatsuji T, Chen TH, Narala S, et al. Antimicrobials from human skin commensal bacteria protect against *Staphylococcus aureus* and are deficient in atopic dermatitis. *Sci Transl Med* 2017; 9: eaah4680.
31. Zipperer A, Konnerth MC, Laux C, et al. Human commensals producing a novel antibiotic impair pathogen colonization. *Nature* 2016; 535: 511-6.
32. Cau L, Williams MR, Butcher AM, et al. *Staphylococcus epidermidis* protease EcpA can be a deleterious component of the skin microbiome in atopic dermatitis. *J Allergy Clin Immunol* 2021; 147: 955-66.
33. Edslev SM, Olesen CM, Nørreslet LB, et al. *Staphylococcal* communities on skin are associated with atopic dermatitis and disease severity. *Microorganisms* 2021; 9: 432.
34. SanMiguel AJ, Meisel JS, Horwinski J, et al. Topical antimicrobial treatments can elicit shifts to resident skin bacterial communities and reduce colonization by *Staphylococcus aureus* competitors. *Antimicrob Agents Chemother* 2017; 61: e00774-17.
35. Meurer M, Konz B. Hautnekrosen nach Anwendung 2%iger Pyoaktinlösung. *Hautarzt* 1977; 28: 94-5.
36. Rogers SF, Borrows D, Neill D. Percutaneous absorption of phenol and methyl alcohol in Magenta Paint BPC. *Br J Dermatol* 1978; 98: 559-60.
37. Woo KY, Heil J. A prospective evaluation of methylene blue and gentian violet dressing for management of chronic wounds with local infection. *Int Wound J* 2017; 14: 1029-35.
38. Littlefield NA, Gaylor DW, Blackwell BN, Allen RR. Chronic toxicity/carcinogenicity studies of gentian violet in Fischer 344 rats: two-generation exposure. *Food Chem Toxicol* 1989; 27: 239-47.