

# Spitz nevus and melanoma: evaluation with dermoscopy and reflectance confocal microscopy

Anna Pogorzelska-Antkowiak<sup>1</sup>, Monika Slowinska<sup>2</sup>, Eleonora Farinazzo<sup>3</sup>, Claudio Conforti<sup>3</sup>, Marina Agozzino<sup>3</sup>

<sup>1</sup>EsteDerm Private Dermatology Clinic, Tychy, Poland

<sup>2</sup>Military Hospital, Warsaw, Poland

<sup>3</sup>Department of Dermatology, University of Trieste, Trieste, Italy

Adv Dermatol Allergol

DOI: <https://doi.org/10.5114/ada.2023.125968>

## Abstract

**Introduction:** Spitz nevi (SN) include a wide range of benign melanocytic nevi, which are controversial due to their morphologic resemblance to melanoma (MM).

**Aim:** To describe dermoscopic and reflectance confocal microscopic (RCM) features of SN compared to MM and assess the RCM utility in the differential diagnosis.

**Material and methods:** We performed a multicentre retrospective analysis of MM and SN evaluated with dermoscopy and reflectance confocal microscopy. Three RCM mosaics were obtained for each lesion. Nine dermoscopic and twenty-one microscopic features were assessed for each lesion.

**Results:** A total of 26 lesions (15 SN and 11 MM) were included. Dermoscopically, most SN showed a “starburst” pattern. Asymmetry was marked in 8 MM. There were 6 dermoscopic features significantly more prevalent in MM than in SN. RCM showed that an atypical honeycomb pattern, atypical infiltration, and disarray of the epidermis were significant for MM. SN mostly revealed a typical honeycomb pattern. At the DEJ, most of SN had a meshwork pattern; MM revealed an atypical meshwork pattern. Atypical cells and sheet-like structures were observed in most MM.

**Conclusions:** A combined approach using dermoscopy and RCM supports the differential diagnosis of SN and MM. Although our study showed some significant differences between SN and MM in RCM, further research on a larger group should be considered.

**Key words:** melanoma, dermoscopy, reflectance confocal microscopy, Spitz nevus.

## Introduction

Spitz nevi (SN) include a wide range of benign nevi first described by Sophie Spitz in 1948 [1, 2]. SN are diagnostically ambiguous due to their clinical similarity to melanoma (MM). Dermoscopy has contributed significantly to improving the clinical diagnosis of pigmented and non-pigmented SN. More recently, reflectance Confocal Microscopy (RCM) has contributed substantially to improving a differential diagnosis between SN and melanoma [3]. SN occurs mainly in children and adolescents. MM is more frequent in the middle age and past the age of forty than among younger patients [1, 2, 4]. The dermoscopic patterns most commonly associated with SN are starburst, negative network, non-specific and homogenous. Johr and Stolz described in total six dermoscopic patterns of SN. In addition to the four patterns mentioned above, they also included lesions with black pigment network and pink lesions [5–7].

In some cases, their presentation overlaps with the clinical features of malignant melanoma. The differential diagnosis of such lesions can be challenging. However, histopathological evaluation of SN reveals distinct patterns of genetic aberrations compared to melanoma and common nevi [7–9].

Many attempts have been made to determine dermoscopic diagnostic criteria of SN [10, 11]. RCM is a promising and useful tool in differentiating SN from MM and other melanocytic proliferations.

A non-invasive approach could open the possibility of a more precise pre-histological diagnosis with the reduction of surgical excision of SN.

## Aim

This study aimed to describe dermoscopic and RCM features of SN compared to MM and assess the RCM usefulness in the final differential diagnosis.

---

**Address for correspondence:** Anna Pogorzelska-Antkowiak MD, PhD, EsteDerm Private Dermatology Clinic, Aleja Bielska 135b/17, Tychy, Poland, e-mail: [annapogorzelska03@wp.pl](mailto:annapogorzelska03@wp.pl)

**Received:** 16.01.2023, **accepted:** 11.02.2023.

*This is an Open Access article distributed under the terms of the Creative Commons Attribution-NonCommercial-ShareAlike 4.0 International (CC BY-NC-SA 4.0) License (<http://creativecommons.org/licenses/by-nc-sa/4.0/>)*

**Material and methods**

A retrospective study including 26 melanocytic lesions was performed in three dermatologic centres (Private Dermatology Clinic in Tychy, Poland, between January 2016 and December 2020, Department of Dermatology at the University of Trieste, Italy from October 2017 to January 2020 and Military Institute of Medicine in Warsaw, Department of Dermatology, between January 2018 and January 2020).

Patients with a histopathological diagnosis of SN and MM who underwent RCM and dermoscopic evaluation were included in the study. Four SN regarding children under 12 years old were clearly benign in dermoscopy, with no biopsy, since the lesions were stable clinically and dermoscopically.

All images were analysed by certified dermatologists. The dermoscopic diagnosis was performed using standard terminology to qualify four dermoscopic patterns of SN:

**Table 1.** Confocal features of the epidermis and dermo-epidermal junction in Spitz nevus and melanoma

Feature	Spitz nevus (n = 15)	Melanoma (n = 11)	P-value
<b>Epidermis:</b>			
Typical honeycombed pattern	6	0	0.017
Atypical honeycombed pattern	7	11	0.004
Typical cobblestone pattern	6	2	NS
Atypical cobblestone pattern	0	0	–
Dendritic cells	7	9	NS
Atypical roundish cells	9	11	0.017
Atypical infiltration	0	5	0.004
Acanthosis	8	4	NS
Disarray of the epidermis	0	5	0.004
<b>Dermo-epidermal junction:</b>			
Meshwork pattern	11	2	0.006
Edged papillae	2	0	NS
Atypical meshwork	1	10	< 0.001
Non-edged papillae	12	10	NS
Atypical nests (dense)	6	5	NS
Atypical nests (sparse)	2	2	NS
Atypical cells	0	5	0.039
Dendritic	3	7	0.023
Inflammatory cells	4	0	NS
Pleomorphic atypical cells (huge, some with dendrites, fusiform etc.)	4	3	NS
Cerebriform nests	0	6	0.01
Sheet-like structure	5	9	0.013

NS – non-significant.

starburst, negative network, and homogenous or non-specific pattern. Dermoscopic images were analysed by A.P.A., C.C., and E.F. Confocal imaging was performed with a reflectance confocal microscope in vivo (Vivascope1500; Lucid Inc., Rochester, NY, USA). For each lesion, a minimum of three mosaics were available for re-evaluation: one at the level of the superficial epidermis (stratum granulosum/spinosum), one at the level of the dermo-epidermal junction (DEJ), and one from the upper dermis.

RCM features assessed at the epidermis level and DEJ are reported in Table 1. The RCM examinations blinded to histology have been re-evaluated by two experts (A.P.A. and M.S.).

The study was conducted in compliance with the Declaration of Helsinki. For each evaluation, written informed consent was obtained.

**Statistical analysis**

To assess the differences in the presence of a given feature between patients diagnosed with MM or SN, a proportion test was performed for two independent trials. Statistica 13.1 software (StatSoft Polska, Krakow, Poland) was used for all statistical analyses. Values were considered statistically significant at  $p < 0.05$ .

**Results**

**Study group characteristics**

A total of 26 lesions (15 SN and 11 MM) were included. The mean age of the participants was 24.3 years (range: 5–43) in the SN group and 51.9 years (range: 36–73) in the MM group. The mean thickness of MM was 0.43. Two MM were in situ; all were superficial. Three MM were located on the limbs, while 8 on the trunk. Eight SN were located on the trunk and 7 on the skin of limbs.


**Dermoscopic features**

Dermoscopic data are presented in detail in Table 2. Thirteen Spitz nevi showed a “starburst” pattern (Fig-

**Table 1.** Dermoscopic features of evaluated lesions

Feature	Spitz nevus (n = 15)	Melanoma (n = 11)	P-value
Asymmetry	0	8	< 0.001
Whitish veil	0	7	0.001
Atypical globules	0	11	< 0.001
Atypical network	1	7	0.002
Polymorphic vessels	0	7	0.001
More than 1 colour	1	7	0.002
Atrophy	0	3	NS
Pseudopodia	13	8	NS
“Peppering”	0	2	NS

NS – non-significant.



**Figure 1.** A – Spitz nevus with a starburst pattern. B – RCM image showing atypical cells (arrows) at the level of the epidermis

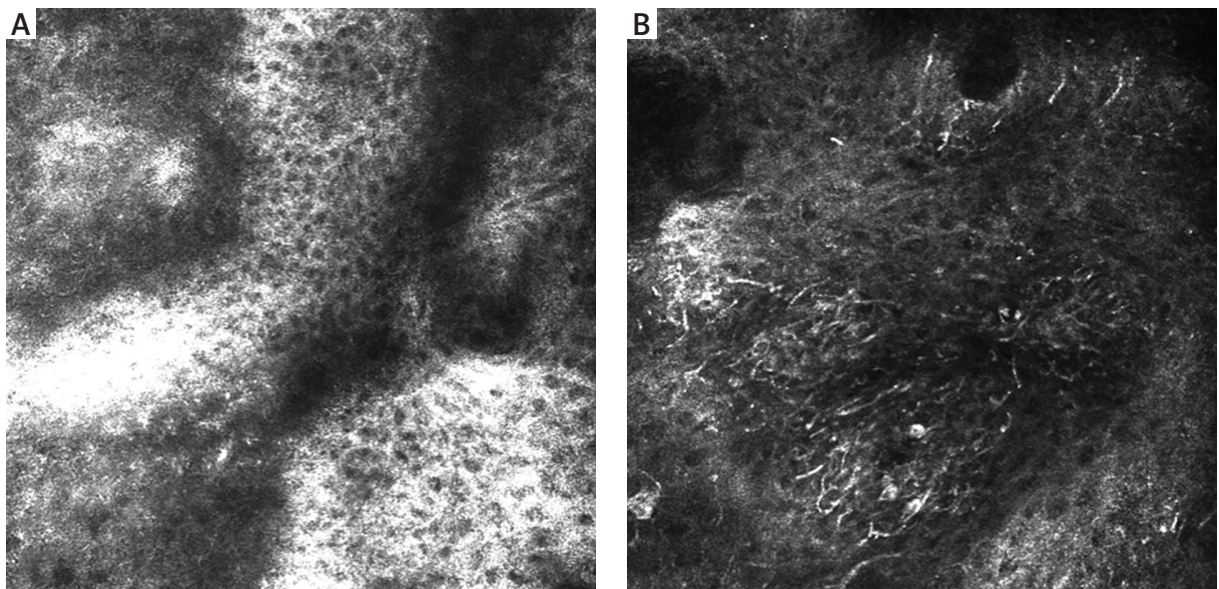
re 1 A). One was homogenous, and one had a negative network. Eleven MM dermoscopically revealed atypical globules. Polymorphic vessels, atypical network, and blue-whitish veil were observed in 7 melanomas. Asymmetry was clearly marked in 8 MM. Asymmetry, whitish veil, atypical globules, atypical network, polymorphic vessels, and the presence of more than 1 colour were significantly more prevalent in melanomas than in Spitz nevi (Table 2).

#### RCM features

RCM features of the epidermis are presented in Table 1. Nine RCM features at the level of the epidermis were assessed. A typical honeycomb pattern was observed in 6 SN with statistical significance ( $p < 0.05$ ), while 7

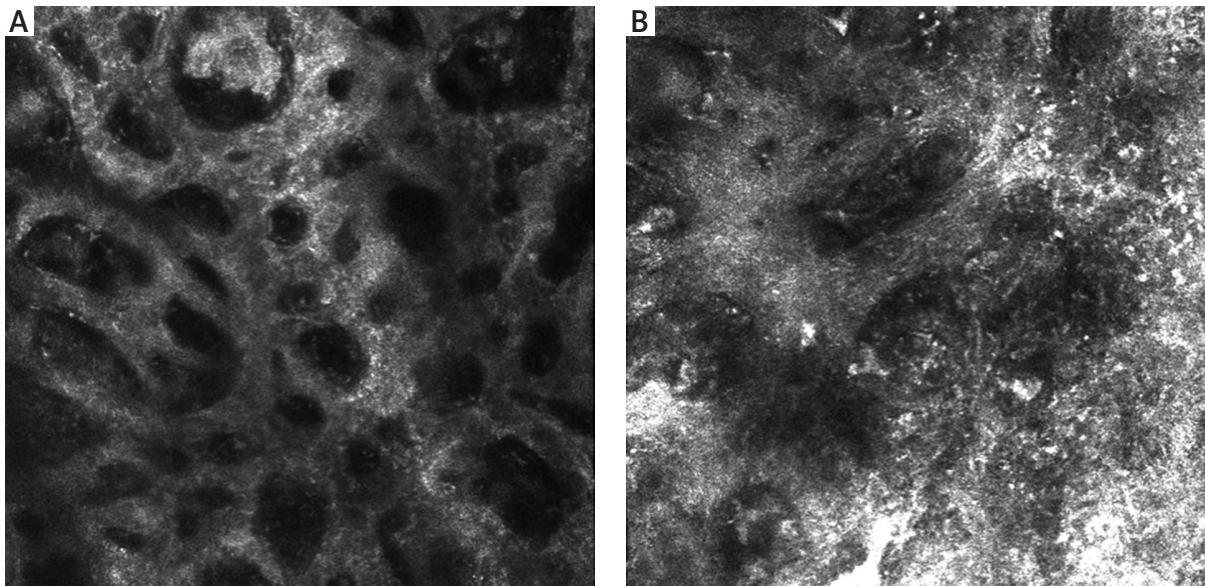
revealed an atypical honeycomb pattern (Figure 2 A, B). Six SN also partially revealed a cobblestone pattern due to higher pigmentation of lesions. 9 SN presented pagetoid cells in the epidermis (Figure 1 B). A significant feature of the epidermis in melanoma cases was atypical infiltration and disarray of the epidermis ( $p < 0.05$ ).

RCM features of the DEJ are presented in Table 1. At the DEJ, six features were statistically significant. SN mostly revealed the meshwork pattern at the DEJ (Figure 3 A). In our study, 11 SN showed a meshwork pattern with statistical significance ( $p < 0.05$ ), while 10 MM revealed an atypical meshwork pattern with statistical significance ( $p < 0.05$ ) (Figure 3 B). Atypical pagetoid cells were visible in 5 MM ( $p < 0.05$ ). Cerebriform nests and

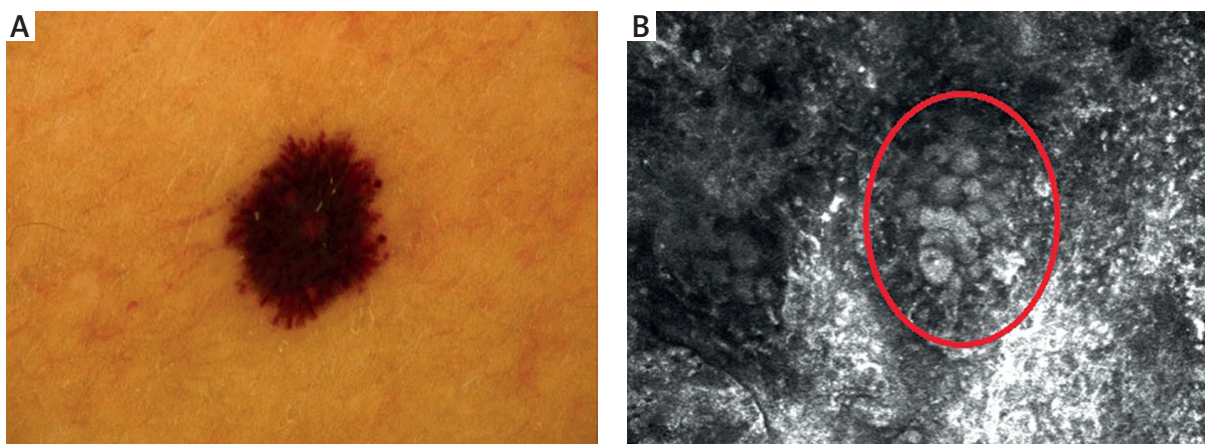


**Figure 2.** A – A typical honeycomb pattern in SN. B – An atypical honeycomb pattern with numerous atypical cells in MM





**Figure 3. A** – A typical meshwork pattern at the DEJ of SN. **B** – SN presenting an atypical meshwork pattern at the DEJ



**Figure 4. A** – Dermoscopy of melanoma. **B** – RCM at the DEJ revealing a sheet-like structure (circle)

sheet-like structures, essential features of malignancy, were observed in 9 MM ( $p < 0.05$ ) (Figure 4 B).

### Discussion

SN are benign melanocytic lesions mostly identified by characteristic clinical and dermoscopic features. Although histopathological and dermoscopic criteria of SN have been considerably described, differential diagnosis of SN and MM is challenging [12–14]. In our study, most SN and MM in dermoscopy presented a “starburst” type of architecture (Figure 4 A). Dermoscopic features differed between MM and SN, with six of them reaching statistical significance. In symmetric and well-demarcated cases, differential diagnosis with melanoma is easier. The difficulties may occur in lesions with non-

specific dermoscopic patterns [15–18]. Especially when blue colour within the lesion is observed. Pellacani *et al.* [19] described the most common features of SN in RCM. There were cut-off, dense junctional, and plump, bright cell nests. A broadened honeycomb pattern of the epidermis, disarranged epidermal pattern, and the presence of small pagetoid cells were more likely correlated with a melanoma diagnosis. Non-edged papillae were significant for MM diagnosis, while dense junctional nests were more common in SN [12, 18]. Previous studies showed different RCM epidermal features between MM and SN; a correlation between striking cells pleomorphism and melanoma was found [20]. Carrera and Marghoob [21] highlighted the importance of the distribution of epidermal pagetoid cells within SN. In SN, pagetoid cells are rare, distributed in the suprabasal layers, and mostly

clustered toward the lesion centre. In melanoma, pagetoid cells are located randomly in a rather diffuse manner. However, both MM and SN can manifest architectural disarray and cytologic atypia. In our study, there were significant differences in the architecture of the epidermis between melanoma and Spitz nevi. MM showed an atypical honeycomb pattern, while most SN revealed typical epidermal architecture. The DEJ also showed significant differences between MM and SN. Most SN revealed a meshwork pattern, whereas melanoma had an atypical meshwork pattern. Cerebriform nests and sheet-like structures proved to be essential diagnostic features as they may have a significant role in melanoma recognition. It is worth mentioning that no study to date has shown the relevance of sheet-like structure presence in the differential diagnosis between MM and SN in RCM. This significant feature presents as clusters of atypical cells in the histopathological evaluation.

## Conclusions

A combined approach using dermoscopy and RCM improves the differential diagnosis of SN and MM. The main limitation of our study was a small group of patients. Although our study showed some significant differences between SN and MM in RCM, further research on a larger group should be considered.

## Acknowledgments

Research was conducted in EsteDerm, Private Dermatology Clinic, Aleja Bielska 135b/17, Tychy, Poland.

## Conflict of interest

The authors declare no conflict of interest.

## References

- Menezes FD, Mooi WJ. Spitz tumors of the skin. *Surg Pathol Clin* 2017; 10: 281-98.
- Abboud J, Stein M, Ramien M, Malic C. The diagnosis and management of the Spitz nevus in the pediatric population: a systematic review and meta-analysis protocol. *Syst Rev* 2017; 6: 81.
- Ring C, Cox N, Lee JB. Dermatoscopy. *Clin Dermatol* 2021; 39: 635-42.
- Stefanaki C, Stefanaki K, Chardalias L, et al. Differential diagnosis of Spitzoid melanocytic neoplasms. *J Eur Acad Dermatol Venereol* 2016; 30: 1269-77.
- Pollock JL. Dermoscopic patterns of Spitz nevi. *JAMA* 2018; 319: 194.
- Ferrara G, Gianotti R, Cavicchini S, et al. Spitz nevus, Spitz tumor, and spitzoid melanoma: a comprehensive clinicopathologic overview. *Dermatol Clin* 2013; 31: 589-98.
- Kerner M, Jaimes N, Scope A, Marghoob AA. Spitz nevi: a bridge between dermoscopic morphology and histopathology. *Dermatol Clin* 2013; 31: 327-35.
- Wiesner T, Kutzner H, Cerroni L, et al. Genomic aberrations in spitzoid melanocytic tumours and their implications for diagnosis, prognosis and therapy. *Pathology* 2016; 48: 113-31.
- Ferrara G, Cavicchini S, Corradin MT. Hypopigmented atypical Spitzoid neoplasms (atypical Spitz nevi, atypical Spitz tumors, Spitzoid melanoma): a clinicopathological update. *Dermatol Pract Concept* 2015; 5: 45-52.
- Lallas A, Apalla Z, Ioannides D, et al. Update on dermoscopy of Spitz/Reed naevi and management guidelines by the International Dermoscopy Society. *Br J Dermatol* 2017; 177: 645-55.
- Urso C. Time to reconsider Spitzoid neoplasms. *Dermatol Pract Concept* 2016; 6: 43-8.
- Jing Y, Shen CB, Xue K, et al. Reflectance confocal microscopy characteristics for melanocytic nevi. *Chin Med J* 2019; 132: 2510-1.
- Ritter A, Tronnier M, Vaske B, Mitteldorf C. Reevaluation of established and new criteria in differential diagnosis of Spitz nevus and melanoma. *Arch Dermatol Res* 2018; 310: 329-42.
- Bär M. Spitz and Reed nevi: acquired or congenital. *Dermatol Pract Concept* 2012; 2: 0203a05.
- Bär M, Tschandl P, Kittler H. Differentiation of pigmented Spitz nevi and Reed nevi by integration of dermatopathologic and dermoscopic findings. *Dermatol Pract Concept* 2012; 2: 13-24.
- Argenziano G, Agozzino M, Bonifazi E, et al. Natural evolution of Spitz nevi. *Dermatology* 2011; 222: 256-60.
- Zedek DC, McCalmont TH. Spitz nevi, atypical spitzoid neoplasms, and spitzoid melanoma. *Surg Pathol Clin* 2009; 2: 497-510.
- Pogorzelska-Antkowiak A, Calik J. Mimics of melanoma in reflectance confocal microscopy. *Int J Dermatol* 2021; 60: 540-6.
- Pellacani G, Longo C, Ferrara G, et al. Spitz nevi: in vivo confocal microscopic features, dermoscopic aspects, histopathologic correlates, and diagnostic significance. *J Am Acad Dermatol* 2009; 60: 236-47.
- Guida S, Pellacani G, Cesinaro AM, et al. Spitz naevi and melanomas with similar dermoscopic patterns: can confocal microscopy differentiate? *Br J Dermatol* 2016; 174: 610-6.
- Carrera C, Marghoob AA. Discriminating nevi from melanomas: clues and pitfalls. *Dermatol Clin* 2016; 34: 395-409.