

# Radiation retinopathy following episcleral brachytherapy for intraocular tumors: Current treatment options

Weronika Mularska, MD<sup>1</sup>, Adam Chicheł, MD, PhD<sup>2</sup>, Iwona Rospond-Kubiak, MD, PhD<sup>1</sup>

<sup>1</sup>Department of Ophthalmology, Poznań University of Medical Sciences, Poznań, Poland, <sup>2</sup>Brachytherapy Department, Greater Poland Cancer Center, Poznań, Poland

## Abstract

Radiation retinopathy (RR) and radiation maculopathy (RM) can occur as a result of uveal melanoma radiation treatment and after irradiation of other head and neck extraocular tumors, even with precise targeting techniques, such as stereotactic or proton beam radiotherapy.

This review provides an overview of the current understanding of potential radiation damage to ocular tissues, and how recent developments in ophthalmic multimodal imaging techniques and treatment modalities have improved managing options.

Several treatment strategies have been employed so far for the management of RR, including laser photocoagulation, intravitreal injections of anti-vascular endothelial growth factor (VEGF) agents or glucocorticosteroids and surgery. The use of intravitreal anti-VEGFs or dexamethasone implants have significantly altered the final visual outcome for uveal melanoma patients. As a prophylaxis, a few different strategies were proposed, but still there is a lack of large randomized clinical trials supporting these approaches and clear clinical guidelines for daily practice.

Early detection and proper treatment are crucial in preventing or reducing vision loss, and improving patients' quality of life. Close monitoring and timely intervention are essential for successful management.

*J Contemp Brachytherapy* 2023; 15, 5: 372–382

DOI: <https://doi.org/10.5114/jcb.2023.132398>

**Key words:** radiation retinopathy, multimodal imaging, plaque brachytherapy, radiation maculopathy, choroidopathy, ocular tumors.

## Purpose

Ocular treatment aiming at preserving an eye with a useful vision is now a standard of care in current management of uveal melanoma. Most patients are treated with radiotherapy, and the radiation is delivered by the means of episcleral brachytherapy plaques, proton beam, or stereotactic radiotherapy (SRT). Plaque radiotherapy combined with transpupillary thermotherapy can provide intraocular tumor control, with local tumor recurrence of only 3% at 5-year follow-up [1]. However, potential ocular complications of plaque brachytherapy treatment include radiation retinopathy (RR) or radiation maculopathy (RM), radiation-induced cataract, radiation neuropathy, secondary glaucoma, vitreous hemorrhage, retinal detachment or even scleral necrosis, strabismus and toxic tumor syndrome [2, 3].

Unfortunately, radiation also damages healthy chorioretinal tissue, leading to maculopathy and/or optic

disc edema that may compromise patients' vision years after successful local treatment. Radiation maculopathy clinically can be observed as chronic macular edema (ME). Until now, several preventive strategies have been developed; however, the effective RM treatment still remains challenging.

This review summarizes the current understanding of potential radiation damage to the ocular tissues, clinical features of RR, and recent developments in ophthalmic multimodal imaging techniques. Highlights the newest treatment strategies and some promising prophylactic options used by ophthalmologists in the management of RM after episcleral brachytherapy (BT).

Radiation retinopathy is a chronic, progressive vasculopathy that develops after exposure to any type of radiation. It is a broad term that refers to all retinal vascular changes caused by radiation, and includes both non-proliferative and proliferative retinopathy and/or macular edema. Most frequently, it occurs after a treatment of intraocular tumors (e.g., uveal melanomas), but also after

**Address for correspondence:** Iwona Rospond-Kubiak, Ocular Oncology Service, Department of Ophthalmology, Poznań University of Medical Sciences, 84/82 Szamarzewskiego St., 60-592 Poznań, Poland, ✉ e-mail: [irospondkubiak@ump.edu.pl](mailto:irospondkubiak@ump.edu.pl)

Received: 29.06.2023

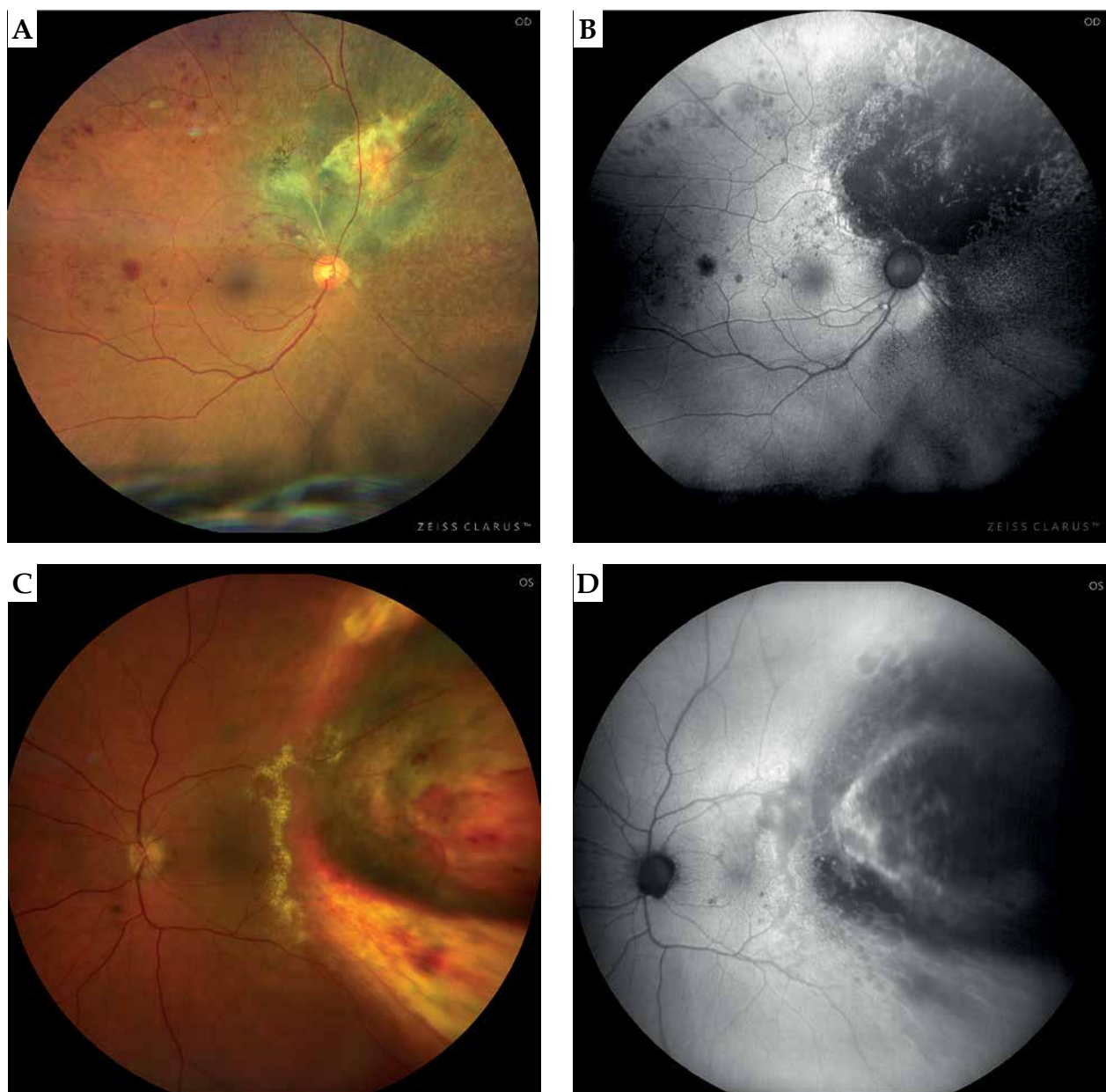
Accepted: 04.10.2023

Published: 26.10.2023

treatment of other tumors of the head and neck region (i.e., nasopharynx, sinuses, and central nervous system) [4]. The radiation damage leads to chronic ischemia in the irradiated area, which results in vascular changes, such as those observed in diabetic retinopathy. Clinically, it would manifest with retinal microaneurysms, telangiectasias, hard exudates, cotton wool spots, and retinal hemorrhages, as shown in Figure 1. Chronic retinal ischemia may lead to neovascularization of the optic nerve disc (NVD) or retina (NVR), which can contribute to vision-threatening complications, such as vitreous hemorrhage and neovascular glaucoma. These changes may be accompanied by choroidal vessels damage (chorioidopathy) or atrophy of the retinal pigment epithelium (RPE) [2, 5].

### *Epidemiology*

Radiation retinopathy can start several months to several years after ocular treatment, affecting about 20-53% of patients after BT, depending on the location of tumor and radionuclide used [6, 7]. Radiation maculopathy was reported as the most common radiation complication after ruthenium BT, occurring in 24.2% of patients [8]. After SRT, RR occurred in 27.7-42% (Cyber Knife) to 34.5% (Gamma Knife) of patients, depending on a study, with a median onset of 13.7 months [9-11]. The RR risk following proton beam irradiation has been reported even more frequently, ranging to 85-90%, but proton beam-irradiated tumors normally are located more posteriorly [12].



**Fig. 1.** Radiation retinopathy following ruthenium-106 plaque brachytherapy in two patients: color (A, C) and autofluorescence imaging (B, D) of the retinal fundus (Zeiss Clarus 500 Fundus Camera)

### Etiology

Ionizing radiation acts directly by disrupting chemical bonds in molecules and damaging DNA in dividing cells. It also indirectly interacts with organic matter by producing free radicals that cause extensive damage to cellular structures, and are cytotoxic. Both mechanisms result in damaging tumor cells, but also surrounding tissues.

Vascular endothelial cells are particularly susceptible to radiation damage affecting cell loss and vascular wall weakening [16]. Over time, the damaged capillaries occlude and provide retinal ischemia and neovascularization. Moreover, histopathology studies on irradiated lesions from enucleated eyes after BT have demonstrated less mitotic activity and more inflammation and macrophages infiltration compared with primary tumor tissue [13]. One of the hypotheses emphasizes the importance of inflammatory component in the development of radiation damage, which may be observed as small, hyperreflective retinal foci on OCT scans. These may represent aggregates of activated microglial cells [14, 15].

The irradiated RPE may lose melanin, accumulate lipofuscin, or develop atrophy or hyperplasia [16].

More recently, Platt *et al.* investigated 26 eyes that had undergone plaque BT because of uveal melanoma prior to enucleation. The authors conducted a histopathologic analysis of all 26 eyes with special emphasis on the choroidal changes. Out of these 26 eyes, 18 demonstrated evidence of radiation-induced vasculopathy, 55% had RR, and 89% had radiation choroidal vasculopathy [17].

### Risk factors

Risk factors of developing BT-induced RR include total radiation dose, tumor thickness (more than 4 mm), and tumor location next to functionally important structures, such as fovea and optic disc [18].

With regards to teletherapy used for uveal melanoma treatment, according to some authors, the size of tumor base, tumor thickness, and location of tumor have predictive values for RR, and eyes with larger basal diameter are more likely to develop RR after gamma knife radiosurgery [19]. Other authors report that RR is not significantly associated with the mean radiation dose to the tumor, tumor thickness or tumor its distance from the fovea [20]. Co-existing diabetes and increased risk of RR are supported only by case series reports [21, 22].

Shields *et al.* reported poor visual outcome ( $\leq 20/200$ ) at 5 years in 30% of patients with medium-sized melanoma, and 64% with large melanoma [23]. In the Collaborative Ocular Melanoma Study (COMS), patients were followed for 3 years after brachytherapy and 43% had a final visual acuity (VA) of 20/200 or less [24]. Recently published investigations presented new normograms that could predict the visual outcome post radiation treatment, and included the use of post-operative anti-VEGF agents as a standard of care [25, 26].

### Imaging

Multimodal imaging is crucial in proper diagnosis and timely implementation of treatment. Presymptoma-

tic detection of RM allows for identifying the onset of RR on time. Such a complex imaging approach has been applied to several retinal diseases so far and it's still developing in RR. Depending on the type of imaging used, different classification of RM or RR were proposed, as shown in detail in Table 1.

Fluorescein angiography (FA) shows microvascular features of RR. Classification of RR with combination of ophthalmoscopic and FA findings includes the identification of non-ischemic and ischemic RM, focal, diffuse, and mixed radiation-induced macular edema (ME) [27].

Indocyanine green angiography detects associated damage of choroidal vasculature (atrophy or remodeling of vessels). Early changes can indicate peritumoral atrophy of RPE and irregular closure of choriocapillaris, arterioles and venules [28], which are particularly useful in guiding retinal photocoagulation.

Enhanced depth imaging optical coherence tomography (EDI-OCT) allows for further investigation of post-irradiation choroidal damage [28]. OCT-based grading scheme is ideal for early identification of radiation-induced ME, and helps in assessing the severity of maculopathy. Horgan *et al.* proposed a five-point OCT-based grading scale for RM, depending on localization of intraretinal cysts, as shown in Table 1 [5, 29]. Patients with early or mild RR may be asymptomatic while some changes in OCT or optical coherence tomography angiography (OCTA) are clearly visible. In their study on 135 patients after iodine ( $^{125}\text{I}$ ) brachytherapy, ME occurred on average 12 months after radiotherapy, but at the earliest even after 4 months. 33% of patients did not have symptoms of RR, so the ME visible in OCT preceded clinical symptoms of RR by 5 months, and made the OCT an important tool in diagnosis and monitoring [29].

OCT-A is very sensitive in the detection of the earliest manifestations of RM showing parafoveal capillary network abnormalities. The enlargement of foveal avascular zone (FAZ) and decreased parafoveal capillary density of both superficial and deep capillary plexus in eyes after brachytherapy of choroidal melanoma with no clinical evidence of RR were demonstrated [30-33].

Finally, Parrozani and Midena proposed a classification of RM based on features detectable with multimodal imaging, as shown in Table 1. According to the authors, some parameters as macular cysts are biomarkers related to VA [34, 35]. The OCT and OCT-A symptoms of RR are discussed in Figure 2.

### Treatment

Treatment of RR remains challenging due to the lack of large randomized clinical trials and clear clinical guidelines. Treatment options comprise laser photocoagulation, intravitreal steroids, intravitreal anti-vascular endothelial growth factors (anti-VEGFs), and surgery. The main goal of the treatment is to improve visual function and/or prevent further visual loss. Although there are constant improvements in diagnostic tools and treatment options for RR, a considerable number of eyes, particularly those with proliferative RR or further complications, still loose vision.

**Table 1.** Classification of radiation retinopathy (RR) based on ophthalmic multi-modal imaging

Method of imaging	Classification of radiation retinopathy/maculopathy
Ophthalmoscopic findings and fluorescein angiography [36]	Stage 1: Extramacular ischemic changes Stage 2: Macular ischemic changes Stage 3: Additional macular edema and extramacular retinal neovascularization Stage 4: Vitreous hemorrhage Stage 5: Disc areas of retinal ischemia macular or extramacular
Fluorescein angiography [27]	Non-ischemic and ischemic radiation maculopathy Focal, diffuse, and mixed radiation macular edema
Widefield fluorescein angiography [74]	Grade 0: Normal Grade 1: Late foveal leakage Grade 2: Late peripheral leakage Grade 3: Presence of non-perfusion Grade 4: Retinal neovascularization
OCT examination [5]	Grade 1: Extrafoveal non-cystoid edema Grade 2: Extrafoveal cystoid edema Grade 3: Foveolar non-cystoid edema Grade 4: Mild-to-moderate foveolar cystoid edema Grade 5: Severe foveolar cystoid edema
Angiography of OCT, SD-OCT, and ophthalmoscopic findings [75]	Grade 0: -, -, - Grade 1: +, -, - Grade 2: +, +, - Grade 3: +, +, +, - Grade 4: +, +, +, + Grade 5: Unreadable, +, +, +, + Clinical features detected in OCTA, OCT thickness and cysts, ophthalmoscopic features
Multi-modal imaging and visual acuity-oriented classification of RM [35]	C <sub>x</sub> : Vertical size of the largest macular cyst cannot be assessed C <sub>0</sub> : No evidence of measurable cysts C <sub>n</sub> : n indicate the vertical size of the largest macular cyst in μm J <sub>x</sub> : Presence of IS/OS junction alterations cannot be assessed J <sub>0</sub> : No evidence of IS/OS junction alterations J <sub>1</sub> : Presence of IS/OS junction alterations A <sub>x</sub> : Presence of RPE atrophy cannot be assessed A <sub>0</sub> : No evidence of RPE atrophy A <sub>1</sub> : Presence of RPE atrophy Cyst junction atrophy (CJA) classification: vertical thickness of the largest macular cyst (C parameter), IS/OS layer disruption (I parameter), and presence of foveal RPE atrophy (A parameter)

### Laser therapy

Several studies demonstrated argon laser (focal or grid) efficacy in the reduction of macular thickness, but they were usually only short-term improvements, allowing for the maintenance of VA in a small group of patients [36, 37]. In a group of 45 eyes, Finger *et al.* demonstrated that sector argon laser photocoagulation resulted in regression of clinically evident RR in 64.4% patients and 15.5% of them lost more than 3 lines in VA due to MR [36].

Hykin *et al.* demonstrated that focal laser therapy in 42% of patients (8 eyes) had improved VA comparing with observed controls at 6 months follow-up, but the two groups did not differ after 24 months [37]. For the treatment of proliferative RR, peripheral laser photocoagulation is considered, especially in case of retinal ischemia in extramacular localization or neovascularization. Bianciotto *et al.* found that panretinal photocoagulation causes regression of neovascularization in 66% of eyes

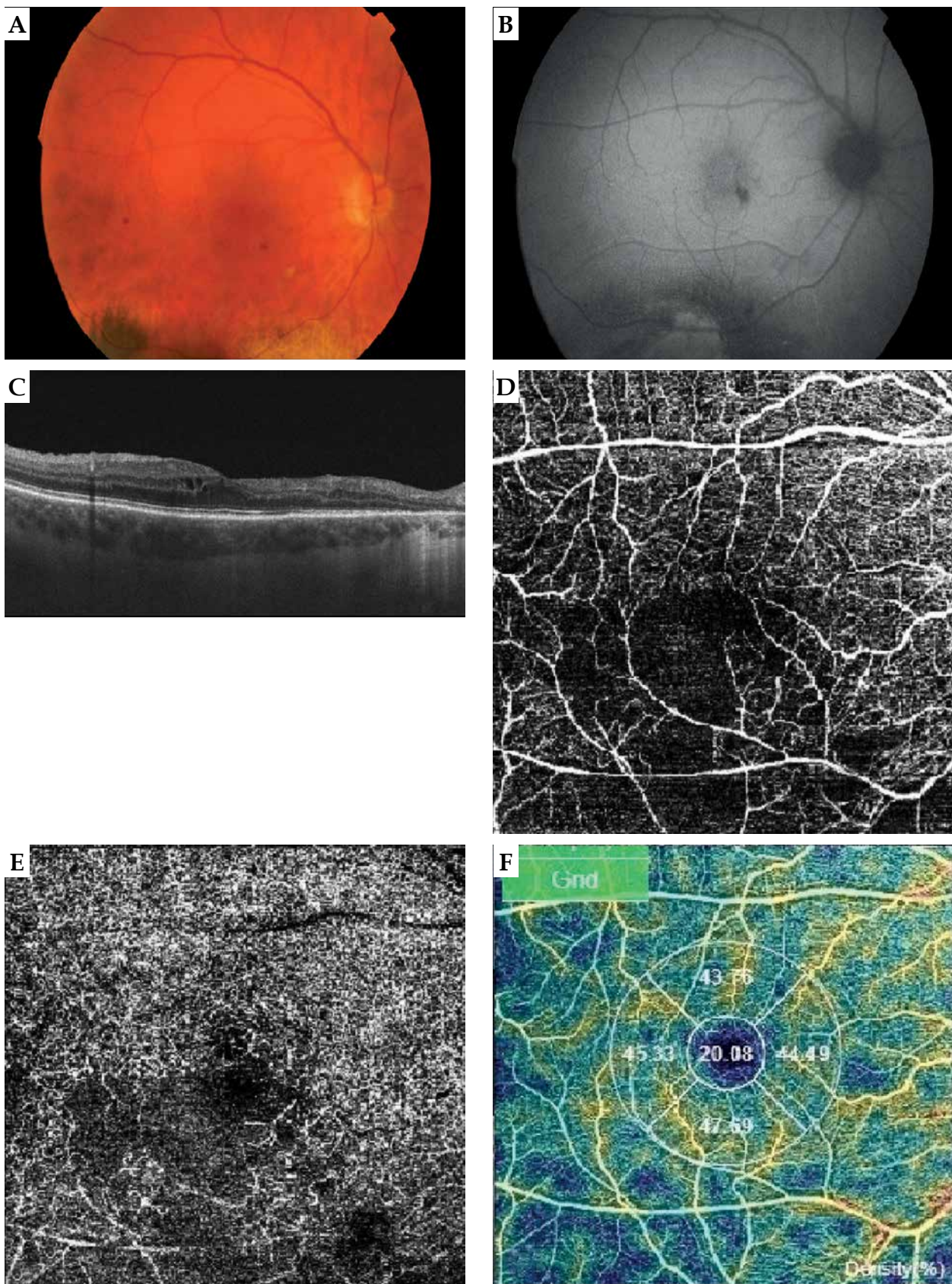
with proliferative RR [38]. With regards to micropulse laser therapy (MPLT), only case reports are available with short follow-up, resulting in improving symptoms and anatomical benefits [39, 40].

### Glucocorticosteroids

Intravitreal steroids are widely used in the treatment of ME, and therefore can be also employed in the treatment of RM. Some studies suggest that intravitreal triamcinolone acetonide (4 mg/0.1 ml) (TA) temporarily reduces ME and improves vision. Shields *et al.* reported that single intra-vitreous injection of 4 mg TA improved or stabilized VA in 91% eyes at 1 month, and in 45% eyes at 6 months after uveal melanoma BT [41].

Steroids are believed to restore the integrity of inner retinal barrier by increasing tight junction protein and upregulating adenosine; therefore, they may complement the action of anti-VEGF medications in the event of in-





**Fig. 2.** Right eye of the 47-year-old male patient sixteen months after ruthenium plaque brachytherapy: color (A) and auto-fluorescence (B) images of the fundus. The images present macular edema with intra-retinal cysts visible in OCT scan (C) and parafoveal vessels droplets in OCTA scans of the macula (retinal capillary network: D) superficial capillary plexus, E) deep capillary plexus, F) density map of the vessels). Scans were captured by DRI OCT Triton, Topcon

**Table 2.** Anti-VEGF treatment in radiation retinopathy. Comparison of studies' design and results

Anti-VEGF intra-vitreous injection	Study design/(n of patients)	Medication dose	Scheme of administration	Follow-up period	Comments on results
Aflibercept [61]	Randomized, clinical prospective study Evaluation of 2 treatment approaches/ (20)/(20)	2 mg/0.05 ml  2 mg/0.05 ml	Every 6 weeks (9 injections)  Treat and extend (mean, 8.4 injections)	60 weeks  60 weeks	Baseline study entry mean BCVA was 20/63 and was maintained at 20/62 at study conclusion of 60 weeks. Almost half of all treated patients maintained BCVA 20/50 or better. Mean CRF SD-OCT was significantly decreased from 432 µm to 294 µm. No difference was found between the two groups
Aflibercept [62]	Prospective, interventional case series report/(9 eyes)	2 mg/0.05 ml	PRN (mean of 4.4 injections were given)	24 months	Functional (BCVA) and anatomical (CRT SD-OCT) improvement. At the end of follow-up, mean BCVA was significantly improved, from 0.9 logMAR at baseline to 0.56 logMAR
Bevacizumab [51]	(6)	1.25 mg/0.05 ml	PRN (every 6-8 weeks)	Mean, 4.7 months (range, 2-8 months)	2 patients resulted in improvement of BCVA and 4 had it stable
Bevacizumab [53]	(21)	1.25 mg/0.05 ml	PRN (mean of 3.8 injections)	Mean, 7.8 months (range, 2-18 months)	18 patients (86) had stable or improved BCVA
Bevacizumab [52]	Retrospective study/(159)	1.25 mg/0.05 ml	PRN (81 patients were given a mean of 5 injections)	3 years	81 patients (50.9%) demonstrated BCVA 20/50 or better. Mean BCVA prior to plaque placement was 20/34. At the time of first anti-VEGF injection, mean BCVA was 20/43, which improved to 20/31 at 34.6 months after brachytherapy
Bevacizumab [54]	Retrospective review/(31)	1.25 mg	Monthly 3x, then PRN (average, 5 injections)	Average of 19 months (range, 0-43 months)	Average BCVA on the day of first intra-vitreous injection was 0.7 logMAR and decreased to 1.3 logMAR at last follow-up. After initiating injection therapy, the mean visual acuity remained stable for 9 months. Patients benefited most from injections administered every 90 days or sooner
Bevacizumab [55]	Non-comparative, interventional case series/(36)	1.5 mg/0.06 ml	Every 4 months	4-6 months	Improvement of BCVA in 42% of the treated eyes, stable in 42% of eyes, and decline in macular edema in 56% of patients. There was a decrease in mean CFT from 482 µm before injection to 284 µm at 6 weeks, but this increased to 449 µm at 4 months after the injection
Bevacizumab [56]	For recalcitrant to 1.25 mg bevacizumab/ (15)	2.5 mg/0.5 ml	Every 3 months	9 months	Mean BCVA improved from 0.55 logMAR to 0.48 logMAR, and mean CMT reduced significantly from 406 µm to 360 µm after 3 months of follow-up. At final follow-up at 9 months, CMT was 395 µm and BCVA was 0.51 logMAR. Response with significant CMT reduction, but not in BCVA
Ranibizumab [57]	Phase 1, open-label, single-center clinical trial/(5)	0.5 mg	Monthly 4x, then PRN (mean of 8.2 injection)	8 months	BCVA improved in 4 of 5 patients (80%) by a mean of 9.5 letters. Mean initial CFT was 416 µm, mean final CFT was 270 µm (reduction in all cases)

Table 2. Cont.

Study design/(n of patients)	Medication dose	Scheme of administration	Follow-up period	Comments on results
Anty-VEGF intra-vitreous injection				
Ranibizumab [58]	0.5 mg	Monthly	12 months	There was a significant difference in mean BCVA at 1 year among all 3 cohorts, with the most significant gains in the monthly group. Mean CMT decreased in all 3 cohorts
	0.5 mg	Monthly and TRP	12 months	
	0.5 mg	Monthly 3x, then PRN and TRP	12 months	
Ranibizumab [60]	0.5 mg	Monthly 2x, then PRN (median 5 injections)	12 months	Significant improvement in BCVA from baseline: 0.16 logMAR to 0.03 logMAR for ranibizumab at 26 weeks end-point. The effect disappeared between two groups at week 52
	Laser therapy	Focal laser treatment of the macula or peripheral laser treatment of the ischemic retina	12 months	
Ranibizumab [59]	2 mg	Every 30 days ±7days for 12 months (mean, 10.2 injections)	12 months	Mean change in BCVA was +3.3 letters at 6 months and +0.7 letters at 1 year. Initial mean CFT was 428 µm and decreased to 333 µm (80% of patients demonstrated a statistically significant reduction in CFT)
	2 mg	Every 30 days ±7days for 4 months, then every month (mean, 10.8 injections)	12 months	

PRN – pro-re-nata (as needed), T&E – treat-and-extend, TRP – targeted panretinal photocoagulation, BCVA – best-corrected visual acuity, CRT SD-OCT – central retinal thickness spectral domain optical coherence tomography, CFT – central foveal thickness, CMT – central macular thickness

complete response to current treatment [42, 43]. They also reduce the inflammatory response that appears during RR with fluid leakage and lipid exudation. Some studies report 4 mg TA as an adjuvant therapy to bevacizumab in incomplete response to treatment or co-therapy in radiation-induced ME [44, 45].

Various authors investigated the efficacy of 0.7 mg intravitreal dexamethasone (DEX) implant or off-label use of fluocinolone acetonide (FA) slow-release implants [46-49]. An improvement of VA has been reported with the use of DEX implant, but with no statistical significance [46, 47]. Of note, the efficacy of intravitreal slow-release implant of 0.19 mg fluocinolone acetonide (FA) was demonstrated in a small group of patients, allowing for the stabilization of VA at 8 months follow-up [49].

**Anti-vascular endothelial growth factor (anti-VEGF) therapy**

Anti-VEGF therapy is a common treatment used nowadays in ophthalmology to manage various retinal diseases. Bevacizumab is the whole anti-VEGF antibody, while ranibizumab is a recombinant humanized IgG1 monoclonal antibody fragment. Both bind to all isoforms of vascular endothelial growth factor A (VEGF-A), but ranibizumab is believed to penetrate through the retinal tissue better and has higher affinity to VEGF-A than bevacizumab. Aflibercept is a fusion protein made up of parts of extracellular domain of human VEGF receptors fused with a part of human immunoglobulin. It binds to all isoforms of VEGF-A, and also to vascular endothelial growth factor B (VEGF-B) and placental growth factor (PGF) [50]. The VEGFs increase vascular permeability and stimulate the division of endothelial cells and formation of new blood vessels (neovascularization process). Anti-VEGF treatment inhibits both processes resulting in reduction of ME and improvement of visual function. However, to achieve these benefits, multiple injections over a certain period of time are required. The anti-VEGF treatment can be administered in fixed time intervals (i.e., every 3 to 4 months) or adjusted as needed (i.e., 3 injections every 3 weeks) and then as needed (pro-re-nata – PRN) to obtain the resolution of ME. Of note, some studies have also found variable responses to treatment according to different treatment protocols [51-54].

**Bevacizumab**

Most of the trials on RR treatment concerned bevacizumab as the most low-cost option (which is used off-label for intravitreal injections), but there were often small groups of patients, case series, or retrospective trials.

Intravitreal injection of 1.25 mg bevacizumab (i.e., PRN) caused regression of ME with stabilization or improvement of VA in most patients [51-53], or in the form of loading phase of 3 injections and then administered PRN [54], or injections every 4 months [55]. Higher doses of bevacizumab (2.5 mg) were administered in recalcitrant ME [56]. In the protocol using intravitreal bevacizumab injection every 3 months in a group of 15 patients, there were no benefits during 9-month follow-up in anatomical improvement of the macula or VA [56].



### **Ranibizumab**

Ranibizumab was investigated in different doses (0.5 or 2 mg) as a first-line treatment in RM or in recalcitrant ME, and in comparison with other treatment options [57-60]. Scheffler *et al.* in their prospective trial investigated the effectiveness of three different ranibizumab treatment protocols in RR: monthly ranibizumab, monthly ranibizumab and targeted retinal photocoagulation (TRP) to areas of peripheral retinal ischemia after 1 week, or three consecutive loading doses of monthly ranibizumab, and then only treated as needed (PRN) with TRP after 1 week after first injection. They showed that ranibizumab improved vision and central macular thickness (CMT), and prevented visual loss for one year in every arm of the study. Moreover, monthly injections were more effective than PRN regimen, and the addition of TRP showed no benefits [58].

Finger *et al.* observed that intra-vitreous injections of high-dose ranibizumab (2 mg) induced significant reductions in ME in 80% cases, and maintained or improved best corrected visual acuity (BCVA) in 70% of patients who did not improve with standard dose anti-VEGF therapy. However, the studied group comprised only 10 patients with 1 year follow-up [59]. Seibel *et al.* in a prospective randomized controlled trial investigated the effect of intravitreal 0.5 mg ranibizumab injections versus laser photocoagulation (Radi Ret study). In 6 months follow-up, ranibizumab was superior to laser treatment with regards to visual function, but the positive effect disappeared if treatment was discontinued after 12 months [60].

### **Aflibercept**

A randomized study with 2 mg aflibercept administered every 6 weeks or in a treat-and-extend approach, showed VA stabilization and ME reduction. Only 5% of eyes had a BCVA worse than 20/200. Functional and anatomic improvements were demonstrated at 12 months in both groups, with no difference in BCVA by protocol [61]. Similarly, Fallico *et al.* found significant improvement in VA and CMT in MR using 2 mg intravitreal aflibercept with PRN protocol, but only 9 eyes were treated [61, 62].

### **Next generation anti-VEGF drugs**

There are some drugs that are promising for the treatment of ME, including brolocizumab, faricimab, and conbercept, or technologies with a port-delivery system, but they still need investigations in RR [63]. Brolocizumab works by inhibiting the binding of VEGF-A to its receptors. Unlike full-size antibodies, this drug has a small molecular size and lacks a crystallizable fragment that allows for better tissue penetration [64, 65]. Faricimab has a dual mechanism of blocking angiopoietin-2 and VEGF-A simultaneously, so it can be an interesting treatment option for radiation-induced retinopathy with its inflammatory background [63]. Conbercept is a recombinant fusion protein that binds specifically to VEGF-B, PGF and various forms of VEGF-A [63].

### **Surgical treatment**

Proliferative RR has been reported to develop in 3% to 25% of eyes treated with BT [7, 35]. Advanced proliferative RR complicated by vitreous hemorrhage or retinal detachment may require pars plana vitrectomy. Neovascular glaucoma remains a difficult complication that can lead to enucleation. In patients who received <sup>125</sup>I plaque BT, secondary enucleation due to neovascular glaucoma occurred in 1-12% of treated eyes [66]. In cases of toxic tumor syndrome, surgical removal (endo-/exo-resection) of the remaining irradiated tumor tissue can be another way of treatment.

### **Prevention of radiation retinopathy and macular edema**

In prevention of developing RR or ME, few different strategies were investigated; but mostly only on small group of patients. When qualifying patients for prophylactic treatment in these cases, the sum of benefits, including VA, must outweigh the risk of complications, such as cataract, glaucoma, infections, etc. There are few treatments that patients can benefit most, including sub-Tenon's steroids, laser, and prophylactic anti-VEGFs.

### **Steroids**

Sub-Tenon's triamcinolone every 4 months can be employed as prophylactic treatment. In a prospective, randomized, controlled clinical trial, periocular injection of triamcinolone acetonide (40 mg/1 ml) was administered at the time of plaque radiotherapy, and then 4 and 8 months later. ME occurred less often with statistical significance in the triamcinolone group compared with the control group up to 18 months after plaque BT (143 patients were included). At 18-month follow-up, visual loss of 3 lines or more and BCVA 5/200 on Snellen chart, occurred significantly less frequently in the TA group than in the control group (31% vs. 48%, and 5% vs. 15%, respectively). Rates of elevated intraocular pressure and cataract progression were similar in both groups [67].

### **Laser therapy**

Laser ablation of ischemic peripheral retina in some studies were proved to reduce the incidence of retinal neo-vascular complications. Finger *et al.* used prophylactic sector-laser photocoagulation, and reported that 62% of patients were stable, 19% improved their BCVA at a mean follow-up of 16.5 months, but it was a small series report of 16 patients [36].

### **Anti-VEGF drugs**

As a prophylactic strategy to prevent radiation-induced ME and RR, intravitreal injections of bevacizumab every 4 months after plaque placement seem to be the most promising approach [68, 69].

Shah *et al.* in their research showed a lower percentage of eyes with ME as well as decreased BCVA compared with the control group. The bevacizumab group of 292 patients received intra-vitreous 1.5 mg bevacizumab injection



at the time of plaque removal, and 6 subsequent injections every 4 months over 2 years. This group demonstrated less frequently OCT-evident ME (26% vs. 40% of the control group), clinically evident RM (16% vs. 31%), loss of 3 lines or more on Snellen BCVA (33% vs. 57%), and poor visual acuity (BCVA worse than 5/200 on Snellen chart, 15% vs. 28%) over a period of 2 years compared with the non-treatment group [68].

Shields *et al.* in a retrospective, non-randomized research administered 1.25 mg bevacizumab to 1,131 eyes with irradiated uveal melanoma (bevacizumab group) and compared their results with 117 eyes without bevacizumab after BT. Treatment protocol included intravitreal injections with 4-month intervals over 2 years following brachytherapy. The bevacizumab group demonstrated less OCT-evident ME and fewer clinical signs of RM at 24-, 36-, and 48-month follow-up, and statistically significant better VA outcomes at all time points (0.54 log MAR vs. 2.00 log MAR at 48 months' time point). There was no ocular or systemic adverse bevacizumab reaction in any patient [69].

Comparable results in smaller groups of patients were achieved by Powell *et al.* They analyzed a group of 14 patients, to whom bevacizumab was administered every 4-6 weeks over 6 months after BT. It prevented or delayed the onset of RM and VA loss [70]. These patients were compared with the control group (14 historical patients diagnosed with choroidal melanoma and treated with palladium-103 plaque BT), case-matched by radiation dose to fovea, proximity to fovea, and size of tumors. When compared with their VA measured at the time of diagnosis, 64.3% in the anti-VEGF-treated group showed improvement or no change in VA, in contrast to 28.6% in the case-matched group. No patient in the anti-VEGF group lost more than 3 lines of vision compared with 10 patients (71.4%) in the case-matched group. At last follow-up, 50% patients demonstrated OCT-detected RM, as compared with 85.7% in the control group. However, this was non-randomized study with a retrospective design and a small number of patients [70].

Another approach propose the use of optimized radiation dosage and delivery techniques that can help reduce the risk of RR and ME. This includes apex dose reduction, eccentric plaques or displacement of radioactive seeds [70-72]. However, greater doses to tumor apex result in better local control of disease [73]. Early detection and treatment of radiation damage can help prevent or minimize visual loss. Therefore, patients who undergo BT should have regular follow-ups.

## Conclusions

Radiation chorioretinopathy is a vision-threatening condition. The current management of radiation maculopathy and retinopathy is based mostly on anti-VEGF agents, laser therapy and steroids. The final choice of the treatment strategy depends on the severity of radiation damage; however, in the majority of ME cases, intravitreal anti-VEGFs would be the first choice. Further randomized clinical trials with larger cohorts of patients and longer follow-ups are needed to establish an effective

protocol of treatment as well as prevention of radiation maculopathy following episcleral plaque placement.

## Disclosure

The authors report no conflict of interest.

## References

- Shields CL, Cater J, Shields JA et al. Combined plaque radiotherapy and transpupillary thermotherapy for choroidal melanoma: tumor control and treatment complication in 270 consecutive patients. *Arch Ophthalmol* 2002; 120: 933-940.
- Peddada KV, Sangani R, Menon H et al. Complications and adverse events of plaque brachytherapy for ocular melanoma. *J Contemp Brachytherapy* 2019; 11: 392-397.
- Zemba M, Dumitrescu OM, Gheorghie AG et al. Ocular complications of radiotherapy in uveal melanoma. *Cancers (Basel)* 2023; 15: 333.
- Shields JA, Shields CL. Management of posterior uveal melanoma: Past, present, and future. *Ophthalmology* 2015; 122: 414-428.
- Horgan N, Shields CL, Mashayekhi A et al. Early macular morphological changes following plaque radiotherapy for uveal melanoma. *Retina* 2008; 28: 263-273.
- Durkin SR, Roos D, Higgs B et al. Ophthalmic and adnexal complications of radiotherapy. *Acta Ophthalmol Scand* 2007; 85: 240-250.
- Karimi S, Arabi A, Siavashpour Z et al. Efficacy and complications of ruthenium-106 brachytherapy for uveal melanoma: a systematic review and meta-analysis. *J Contemp Brachytherapy* 2021; 13: 358-364.
- O'Day RFJ, Roelofs KA, Negretti GS et al. Long-term visual outcomes after ruthenium plaque brachytherapy for posterior choroidal melanoma. *Eye (Lond)* 2023; 37: 959-965.
- Özcan G, Gündüz AK, Mirzayev İ et al. Early results of stereotactic radiosurgery in uveal melanoma and risk factors for radiation retinopathy. *J Ophthalmol* 2020; 50: 156-162.
- Yazici G, Kiratli H, Ozyigit G et al. Stereotactic radiosurgery and fractionated stereotactic radiation therapy for the treatment of uveal melanoma. *Radiat Oncol Biol* 2017; 98: 152-158.
- Modorati GM, Dagan R, Mikkelsen LH et al. Gamma knife radiosurgery for uveal melanoma: A retrospective review of clinical complications in a tertiary referral center. *Ocul Oncol Pathol* 2020; 6: 115-122.
- Sahoo NK, Ranjan R, Tyagi M et al. Radiation retinopathy: Detection and management strategies. *Clin Ophthalmol* 2021; 15: 3797-3809.
- Avery RB, Diener-West M, Reynolds SM et al. Histopathologic characteristics of choroidal melanoma in eyes enucleated after iodine 125 brachytherapy in the Collaborative Ocular Melanoma Study. *Arch Ophthalmol* 2008; 126: 207-212.
- Frizziero L, Parrozzani R, Midena G et al. Hyperreflecting intraretinal spots in radiation macular edema on spectral domain optical coherence tomography. *Retina* 2016; 36: 1664-1669.
- Midena E, Torresin T, Velotta E et al. OCT hyperreflective retinal foci in diabetic retinopathy: A semi-automatic detection comparative study. *Front Immunol* 2021; 12: 613051.
- Groenewald C, Konstantinidis L, Damato B. Effects of radiotherapy on uveal melanomas and adjacent tissues. *Eye (Lond)* 2013; 27: 163-171.
- Platt S, Salomao DR, Pulido J. Histologic findings of choroidal vasculopathy in eyes enucleated following radiation therapy for uveal melanoma: Radiation choroidopathy. *Klin Monbl Augenheilkd* 2021; 238: 584-590.
- Stack R, Elder M, Abdelaal A et al. New Zealand experience of I125 brachytherapy for choroidal melanoma. *Clin Experiment Ophthalmol* 2005; 33: 490-494.

19. Haas A, Pinter O, Papaefthymiou G et al. Incidence of radiation retinopathy after high-dosage single-fraction gamma knife radiosurgery for choroidal melanoma. *Ophthalmology* 2002; 109: 909-913.
20. Özcan G, Gündüz AK, Mirzayev İ et al. Early results of stereotactic radiosurgery in uveal melanoma and risk factors for radiation retinopathy. *Turk J Ophthalmol* 2020; 50: 156-162.
21. Viebahn M, Barricks ME, Osterloh MD. Synergism between diabetic and radiation retinopathy: case report and review. *Br J Ophthalmol* 1991; 75: 629-632.
22. Kumar B, Palimar P. Accelerated radiation retinopathy in diabetes and pregnancy. *Eye (Lond)* 2000; 14: 107-108.
23. Shields CL, Shields JA, Cater J et al. Plaque radiotherapy for uveal melanoma: long-term visual outcome in 1106 consecutive patients. *Arch Ophthalmol* 2000; 118: 1219-1228.
24. Melia BM, Abramson DH, Albert DM et al. Collaborative ocular melanoma study (COMS) randomized trial of I-125 brachytherapy for medium choroidal melanoma. I. Visual acuity after 3 years COMS report no. 16. *Ophthalmology* 2001; 108: 348-366.
25. Shields CL, Dalvin LA, Chang M et al. Visual outcome at 4 years following plaque radiotherapy and prophylactic intravitreal bevacizumab (every 4 months for 2 years) for uveal melanoma: Comparison with nonrandomized historical control individuals. *JAMA Ophthalmol* 2020; 138: 136-146.
26. Dalvin LA, Zhang Q, Hamershock RA et al. Nomogram for visual acuity outcome after iodine-125 plaque radiotherapy and prophylactic intravitreal bevacizumab for uveal melanoma in 1131 patients. *Br J Ophthalmol* 2020; 104: 697-702.
27. Amoaku WM, Archer DB. Fluorescein angiographic features, natural course and treatment of radiation retinopathy. *Eye (Lond)* 1990; 4 (Pt 5): 657-667.
28. Amoaku WM, Lafaut B, Sallet G et al. Radiation choroidal vasculopathy: an indocyanine green angiography study. *Eye (Lond)* 1995; 9 (Pt 6): 738-744.
29. Horgan N, Shields CL, Mashayekhi A et al. Classification and treatment of radiation maculopathy. *Curr Opin Ophthalmol* 2010; 21: 233-238.
30. De Carlo TE, Mieler WF. Automated quantitative OCTA measurements of uveal melanoma-treated eyes with and without radiation retinopathy after I-125 plaque therapy and of nonirradiated fellow eyes. *Eye (Lond)* 2021; 35: 769-776.
31. Skalet AH, Liu L, Binder C et al. Longitudinal detection of radiation-induced peripapillary and macular retinal capillary ischemia using OCT angiography. *Ophthalmol Retina* 2020; 4: 320-326.
32. Lim LS, Camp DA, Ancona-Lezama D et al. Wide-Field (15 × 9 mm) swept-source optical coherence tomography angiography following plaque radiotherapy of choroidal melanoma: An analysis of 105 eyes. *Asia Pac J Ophthalmol (Phila)* 2020; 9: 326-334.
33. Shields CL, Say EA, Samara WA et al. Optical coherence tomography angiography of the macula after plaque radiotherapy of choroidal melanoma: Comparison of irradiated versus nonirradiated eyes in 65 patients. *Retina* 2016; 36: 1493-1505.
34. Midena G, Parrozzani R, Frizziero L et al. Chororetinal side effects of therapeutic ocular irradiation: a multimodal imaging approach. *J Clin Med* 2020; 9: 3496.
35. Parrozzani R, Midena E, Trainiti S et al. Identification and classification of macular morphologic biomarkers related to visual acuity in radiation maculopathy. *Retina* 2020; 40: 1419-1428.
36. Finger PT, Kurli M. Laser photocoagulation for radiation retinopathy after ophthalmic plaque radiation therapy. *Br J Ophthalmol* 2005; 89: 730-738.
37. Hykin PG, Shields CL, Shields JA et al. The efficacy of focal laser therapy in radiation-induced macular edema. *Ophthalmology* 1998; 105: 1425-1429.
38. Bianciotto C, Shields CL, Pironini C et al. Proliferative radiation retinopathy after plaque radiotherapy for uveal melanoma. *Ophthalmology* 2010; 117: 1005-1012.
39. Murray T. Micropulse laser therapy for the treatment of radiation retinopathy. *Ret Surg* 2013.
40. Wong JG, Nguyen TT. Yellow pattern 577-nm micropulse laser: Treatment of macular edema from radiation retinopathy – a case report. *Case Rep Ophthalmol* 2017; 8: 81-86.
41. Shields CL, Demirci H, Dai V et al. Intravitreal triamcinolone acetonide for radiation maculopathy after plaque radiotherapy for choroidal melanoma. *Retina* 2000; 25: 868-874.
42. Nehmé A, Edelman J. Dexamethasone inhibits high glucose-, TNF-alpha-, and IL-1 beta-induced secretion of inflammatory and angiogenic mediators from retinal microvascular pericytes. *Invest Ophthalmol Vis Sci* 2008; 49: 2030-2038.
43. Mizuno S, Nishiwaki A, Morita H et al. Effects of periocular administration of triamcinolone acetonide on leukocyte endothelial interactions in the ischemic retina. *Invest Ophthalmol Vis Sci* 2007; 48: 2831-2836.
44. Bakri SJ, Larson TA. The variable efficacy of intravitreal bevacizumab and triamcinolone acetonide for cystoid macular edema due to radiation retinopathy. *Semin Ophthalmol* 2015; 30: 276-280.
45. Kaplan RI, Chaugule SS, Finger PT. Intravitreal triamcinolone acetate for radiation maculopathy recalcitrant to high-dose intravitreal bevacizumab. *Br J Ophthalmol* 2017; 101: 1694-1698.
46. Caminal JM, Flores-Moreno I, Arias L et al. Intravitreal dexamethasone implant for radiation maculopathy secondary to plaque brachytherapy in choroidal melanoma. *Retina* 2015; 35: 1890-1897.
47. Frizziero L, Parrozzani R, Trainiti S et al. Intravitreal dexamethasone implant in radiation-induced macular oedema. *Br J Ophthalmol* 2017; 101: 1699-1703.
48. Russo A, Reibaldi M, Avitabile T et al. Dexamethasone intravitreal implant vs Ranimizumab in the treatment of macular edema secondary to brachytherapy for choroidal melanoma. *Retina* 2018; 38: 788-794.
49. Zimmermann L, Kneifel C, Grajewski L et al. Treatment of radiation-induced maculopathy with fluocinolone acetonide. *Arch Clin Exp Ophthalmol* 2020; 258: 2535-2539.
50. Plyukhova AA, Budzinskaya MV, Starostin KM et al. Comparative safety of bevacizumab, ranibizumab, and aflibercept for treatment of neovascular age-related macular degeneration (AMD): a systemic review and network meta-analysis of direct comparative studies. *J Clin Med* 2020; 9: 1522.
51. Finger PT, Chin K. Anti-vascular endothelial growth factor bevacizumab (Avastin) for radiation retinopathy. *Arch Ophthalmol* 2007; 125: 751-756.
52. Shah NV, Houston SK, Markoe AM et al. Early SD-OCT diagnosis followed by prompt treatment of radiation maculopathy using intravitreal bevacizumab maintains functional visual acuity. *Clin Ophthalmol* 2012; 6: 1739-1748.
53. Finger PT. Radiation retinopathy is treatable with anti-vascular endothelial growth factor bevacizumab (Avastin). *Int J Radiat Oncol Biol Phys* 2008; 70: 974-977.
54. Stacey AW, Demirci H. Serial intravitreal bevacizumab injections slow the progression of radiation maculopathy following iodine-125 plaque radiotherapy. *Open Ophthalmol J* 2016; 10: 103-110.
55. Mashayekhi A, Rojanaporn D, Al-Dahmash S et al. Monthly intravitreal bevacizumab for macular edema after iodine-125 plaque radiotherapy of uveal melanoma. *Eur J Ophthalmol* 2013; 24: 228-234.
56. Khan MA, Mashayekhi A, Ferguson K et al. High-dose (2.5 mg) intravitreal bevacizumab as rescue therapy for per-

- sistent postirradiation cystoid macular edema. *Ocul Oncol Pathol* 2017; 3: 168-175.
57. Finger PT, Chin KJ. Intravitreal ranibizumab (lucentis) for radiation maculopathy. *Arch Ophthalmol* 2010; 128: 249-252.
  58. Shefler AC, Fuller D, Anand R et al. Randomized trial of monthly versus as-needed intravitreal ranibizumab for radiation retinopathy-related macular edema: 1 year outcomes. *Am J Ophthalmol* 2020; 216: 165-173.
  59. Finger PT, Chin KJ. High-dose (2.0 mg) intravitreal ranibizumab for recalcitrant radiation retinopathy. *Eur J Ophthalmol* 2013; 23: 850-856.
  60. Seibel I, Vollhardt D, Riechardt AI et al. Influence of Ranibizumab versus laser photocoagulation on radiation retinopathy (RadiRet) – a prospective randomized controlled trial. *Graefe's Arch Clin Exp Ophthalmol* 2020; 258: 869-878.
  61. Murray TG, Latiff A, Villegas VM et al. Aflibercept for radiation maculopathy study: A prospective, randomized clinical study. *Ophthalmol Retin* 2019; 3: 561-566.
  62. Fallico M, Reibaldi M, Avitabile T et al. Intravitreal aflibercept for the treatment of radiation-induced macular edema after ruthenium 106 plaque radiotherapy for choroidal melanoma. *Graefe's Arch Clin Exp Ophthalmol* 2019; 257: 1547-1554.
  63. Iglicki M, González DP, Loewenstein A et al. Next-generation anti-VEGF agents for diabetic macular oedema. *Eye (Lond)* 2022; 36: 273-277.
  64. Sacconi R, Giuffrè C, Corbelli E et al. Emerging therapies in the management of macular edema: a review. *F1000Res* 2019; 8: F1000 Faculty Rev-1413.
  65. Tadayoni R, Sararols L, Weissgerber G et al. Brolucizumab: A newly developed anti-VEGF molecule for the treatment of neovascular age-related macular degeneration. *Ophthalmologica* 2021; 244: 93-101.
  66. Wen JC, Oliver SC, McCannel TA. Ocular complications following I-125 brachytherapy for choroidal melanoma. *Eye (Lond)* 2009; 23: 1254-1268.
  67. Horgan N, Shields CL, Mashayekhi A et al. Periocular triamcinolone for prevention of macular edema after plaque radiotherapy of uveal melanoma. A randomized controlled trial. *Ophthalmology* 2009; 116: 1383-1390.
  68. Shah SU, Shields CL, Bianciotto CG et al. Intravitreal bevacizumab at 4-month intervals for prevention of macular edema after plaque radiotherapy of uveal melanoma. *Ophthalmology* 2014; 121: 269-275.
  69. Shields CL, Dalvin LA, Chang M et al. Visual outcome at 4 years following plaque radiotherapy and prophylactic intravitreal bevacizumab (every 4 journal pre-proof months for 2 years) for uveal melanoma: Comparison with nonrandomized historical control individuals. *JAMA Ophthalmol* 2020; 138: 136-146.
  70. Powell BE, Finger PT. Anti-vascular endothelial growth factor therapy immediately after plaque radiation therapy prevents or delays radiation journal pre-proof maculopathy. *Ophthalmol Retina* 2020; 4: 547-550.
  71. Reichstein D. Current treatments and preventive strategies for radiation retinopathy. Review. *Curr Opin Ophthalmol* 2015; 26: 157-166.
  72. American Brachytherapy Society – Ophthalmic Oncology Task Force. ABS – OOTF Committee. The American Brachytherapy Society consensus guidelines for plaque brachytherapy of uveal melanoma and retinoblastoma. *Brachytherapy* 2014; 13: 1-14.
  73. Jensen AW, Petersen IA, Kline RW et al. Radiation complications and tumor control after 125 I plaque brachytherapy for ocular melanoma. *Int J Radiat Oncol Biol Phys* 2005; 63: 101-108.
  74. McCannel TA, Kim E, Kamrava M et al. New ultra-wide field angiographic grading scheme for radiation retinopathy after Iodine-125 brachytherapy for uveal melanoma. *Retina* 2018; 38: 2415-2421.
  75. Veverka KK, AbouChehade JE, Iezzi R Jr, Pulido JS. Noninvasive grading of radiation retinopathy: The use of optical coherence tomography angiography. *Retina* 2015; 35: 2400-2410.