

# Recovery of nonketotic hyperglycaemic hemichorea – hemiballismus due to acute ischemic stroke in the contralateral supplementary motor area: a case report and literature review

Xiuyu Du, Xiaochuan Guo, Xiaobao Zhou

Department of Neurosurgery, Shanghai Municipal Hospital of Traditional Chinese Medicine, Shanghai University of Traditional Chinese Medicine, Shanghai, China

*Folia Neuropathol* 2024; 62 (1): 1-6

DOI: <https://doi.org/10.5114/fn.2024.135290>

## Abstract

**Introduction:** There remains uncertainty about the mechanism and specific location of the relative cortex with nonketotic hyperglycaemic hemichorea–hemiballismus (HC–HB). This paper aims to analyse the relationship between the disappearance of HC–HB and the supplementary motor area (SMA) infarction in a patient who recovered following an acute ischemic stroke.

**Case presentation:** An 83-year-old female patient with diabetes mellitus presenting with severe and refractory involuntary movement after hypoglycaemic therapy was referred to an outpatient neurosurgery department for further intervention. Laboratory, magnetic resonance imaging (MRI) and computed tomography (CT) neuroimaging and physical examinations were performed. After a diagnosis of HC–HB was confirmed, the patient received hypoglycaemic therapy and haloperidol; however, there was no significant improvement. Brain MRI T1-weighted images and CT scans showed high signal intensity involving the bilateral putamen nucleus. CT perfusion and CT angiography showed a hypo-perfusion in the SMA of the right hemisphere without significant vascular occlusion. Then, aspirin and clopidogrel were administered, and the patient's left leg presented slight involuntary movement three days later. Interestingly, her involuntary movement disappeared again on the second day after the discontinuation of antiplatelet therapy. She was discharged three days later, and her symptoms did not recur during a follow-up for three months.

**Conclusions:** The SMA dysfunction caused by the acute infarction could terminate or reset the pathological neural pathway of nonketotic hyperglycaemic HC–HB and contribute to the disappearance of the involuntary movement on the contralateral side. The SMA may be a selective intervention target for patients with refractory nonketotic hyperglycaemic HC–HB.

**Key words:** stroke, diabetes, hemiballismus, hemichorea, hyperglycaemia.

## Introduction

Hemichorea–hemiballismus (HC–HB) syndrome linked with nonketotic hyperglycaemia is a rare first manifestation of diabetes mellitus or incidence in diabetic patients with poor glycaemic control. Approximately 71.6% of the HC–HB instances documented have been

seen in older Asian female patients. The clinical manifestation of nonketotic hyperglycaemic HC–HB presents as hyperkinetic disorders on one side and involves the limbs and face; there is hyperintensity of basal ganglia (especially in the putamen) in computed tomography (CT) and T1-weighted magnetic resonance

## Communicating author:

Xiuyu Du, MD, Department of Neurosurgery, Shanghai Municipal Hospital of Traditional Chinese Medicine, Shanghai University of Traditional Chinese Medicine, 274 Zhijiang Road (M), Jing'an District, Shanghai, 200071, China, phone: 021-56639828-6333, e-mail: [duxuy8108@163.com](mailto:duxuy8108@163.com)

**Received:** 26.12.2022, **Accepted:** 11.08.2023, **Online publication:** 2024

imaging (MRI). For most patients, the movement disorders disappear when the patient's hyperglycaemia is controlled [8,10]. The risk factors for nonketotic hyperglycaemia caused by HC–HB include metabolic causes, autoimmune inflammation, infectious causes, hormone imbalance, medication/toxic exposure, polycythaemia vera, genetic aetiology and neurodegenerative disorders [5]. Among these factors, uncontrolled diabetes mellitus is the most common concern. Several hypothesised pathophysiologic mechanisms exist for nonketotic hyperglycaemic HC–HB, and the basal ganglia–thalamus–cerebral cortex circuit is the most concerning [2,7]. Most researchers have suggested that for patients with nonketotic hyperglycaemic HC–HB affected by hyperglycaemia, the basal ganglia's output is reduced and causes disinhibition of the thalamus–cerebral cortex, leading to a hyperkinetic movement disorder [7]. However, the precise neural pathway and location of the related cortex are difficult to determine by direct clinical evidence.

This study describes the first known patient with nonketotic hyperglycaemic HC–HB who had complete recovery following an acute ischemic stroke in the supplementary motor area (SMA). The SMA is thought to play a crucial role in patients' planning and controlling of motor tasks, and SMA injury would result in contralateral dyskinesia, mutism or severe speech impairment. However, these deficits are transient, and patients have complete or basic recovery within weeks to months. This paper analyses the relationship between the disappearance of symptoms and related cortex location and speculates that SMA may be a selective inter-

vention target for patients with refractory nonketotic hyperglycaemic HC–HB.

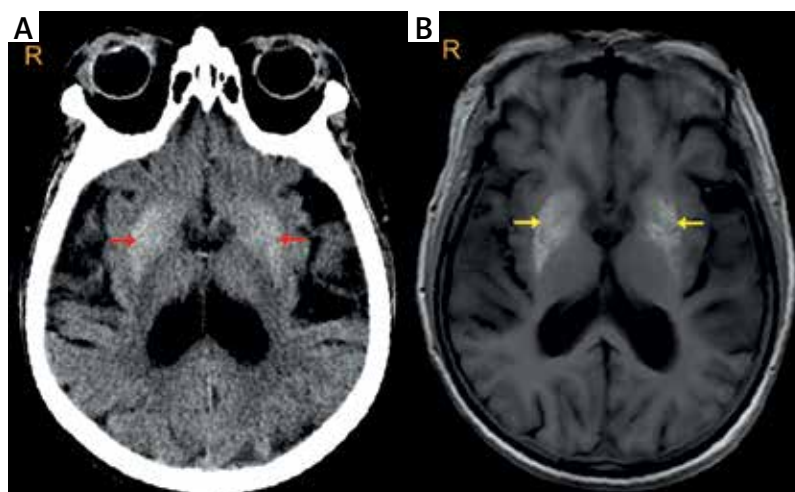
## Case presentation

### Ethics approval and consent to participate

This study was conducted in accordance with the Declaration of Helsinki and approved by the Ethics Committee of Shanghai Municipal Hospital of Traditional Chinese Medicine. All participants signed an informed consent form for inclusion in the study.

### General information

An 83-year-old female patient with severe and refractory involuntary movement of the left limbs, mouth and face was referred to an outpatient neurosurgery department at the endocrinology clinic for surgical intervention. The patient had a more than 20-year history of type 2 diabetes mellitus. Two months earlier, she went to the endocrinology clinic for treatment of her poorly controlled hyperglycaemia (blood glucose was 25 mmol/l, glycosylated haemoglobin A<sub>1c</sub> [HBA<sub>1c</sub>] level was 11.4%). During the treatment and one week after the initial treatment, she suffered a sudden onset of uncontrolled mouth chewing and then the involuntary ballistic movement of her left arm. Finally, she could not keep her left leg still, which failed to cease even during sleep. Although her blood glucose level was well-controlled, her condition worsened, and she was referred to a neurologist for consultation. The patient had no history of carbon monoxide poisoning or hypoxic-ischemic



**Fig. 1.** Axial non-contrast computed tomography (CT) scan (A, red arrow) and axial T1-weighted magnetic resonance imaging (MRI) sequence (B, yellow arrow) showing hyperintensity in the bilateral putamen nucleus, and the high intensity in the right side is more significant than that in the left side.

encephalopathy. A lung CT showed slight interstitial pneumonia on both sides.

According to her lab examinations, neuroimaging (Fig. 1) and physical examination, she was diagnosed with nonketotic hyperglycaemic HC–HB. She accepted a multidisciplinary therapeutic schedule containing hypoglycaemic therapy and haloperidol. However, there was no significant improvement. Due to her poor improvement, the patient came to this study's outpatient department of neurosurgery to consult about potential surgical approaches. Her clinical data were thoroughly analysed. She had no personal or family history of dyskinesia disease. The patient had normal consciousness without discomfort except for her restless left limbs, mouth and face, and her vital signs were normal.

### Laboratory examinations and neurological assessments

Her laboratory examination results for glucometabolic indices included the following: blood glucose 10 mmol/l, HbA1c level 7.1%, glycated albumin 30.4%, insulin (0-120 min) 10.8-23.3 pmol/l, C-peptide (0-120 min) 0.48-1.05 ng/ml, negative islet cell antibody, insulin autoantibody and zinc transporter 8 antibody tests, plasma osmotic pressure 304.69 mmol/l, urine negative for ketones; and normal liver and renal function indices.

The patient's electrolytes were as follows: potassium 3.76 mmol/l, calcium 2.26 mmol/l and sodium 140.0 mmol/l. The SAP analysis showed anoxemia. It also showed that the partial pressure of oxygen was 64.0 mmHg, the partial pressure of carbon dioxide was 38.0 mmHg, and the pH value was 7.430. The patient's thyroid hormone and parathyroid hormone levels were normal, and her haemoglobin was 126 g/l.

The results of the neurological assessment were that the patient had clear awareness, and the function of her cranial nerves was normal. There was continuous chewing action of her mouth that affected her ipsilateral face, with involuntary ballistic movements of her shoulder and elbow joints and disturbance actions in her hand and leg. These involuntary movements did not stop when she was sleeping. Her right limbs had normal muscle strength and tension, and her left limbs had V-muscle strength and normal tension. The bilateral Babinski sign was negative. There was mild ataxia on her left side, and the Romberg sign was positive.

### Imaging examinations

Brain MRI T1-weighted images and CT scans showed high signal intensity involving the bilateral putamen nucleus (Fig. 1). The functional neurosurgery department considered stereotactic nucleus lesioning

therapy or deep brain stimulation therapy. During the preoperative evaluation, the symptoms of HC–HB disappeared suddenly without any special medical treatments, except for common oral hypoglycaemic drugs and insulin subcutaneous injection therapy. The repeated lab examination showed the patient's blood glucose was 8.8 mmol/l, and her HbA<sub>1c</sub> level was 7.0%. A brain MRI was arranged immediately, and an acute cerebral infarction in her right SMA cortex was found (Fig. 2). The patient was without hemiparesis and sensory disturbance on her right side and other neurological dysfunction, and she had negative pathological signs. Then, CT perfusion and CT angiography were completed and showed a hypofusion in the SMA of the right hemisphere (Fig. 3) without a large cerebral vascular occlusion.

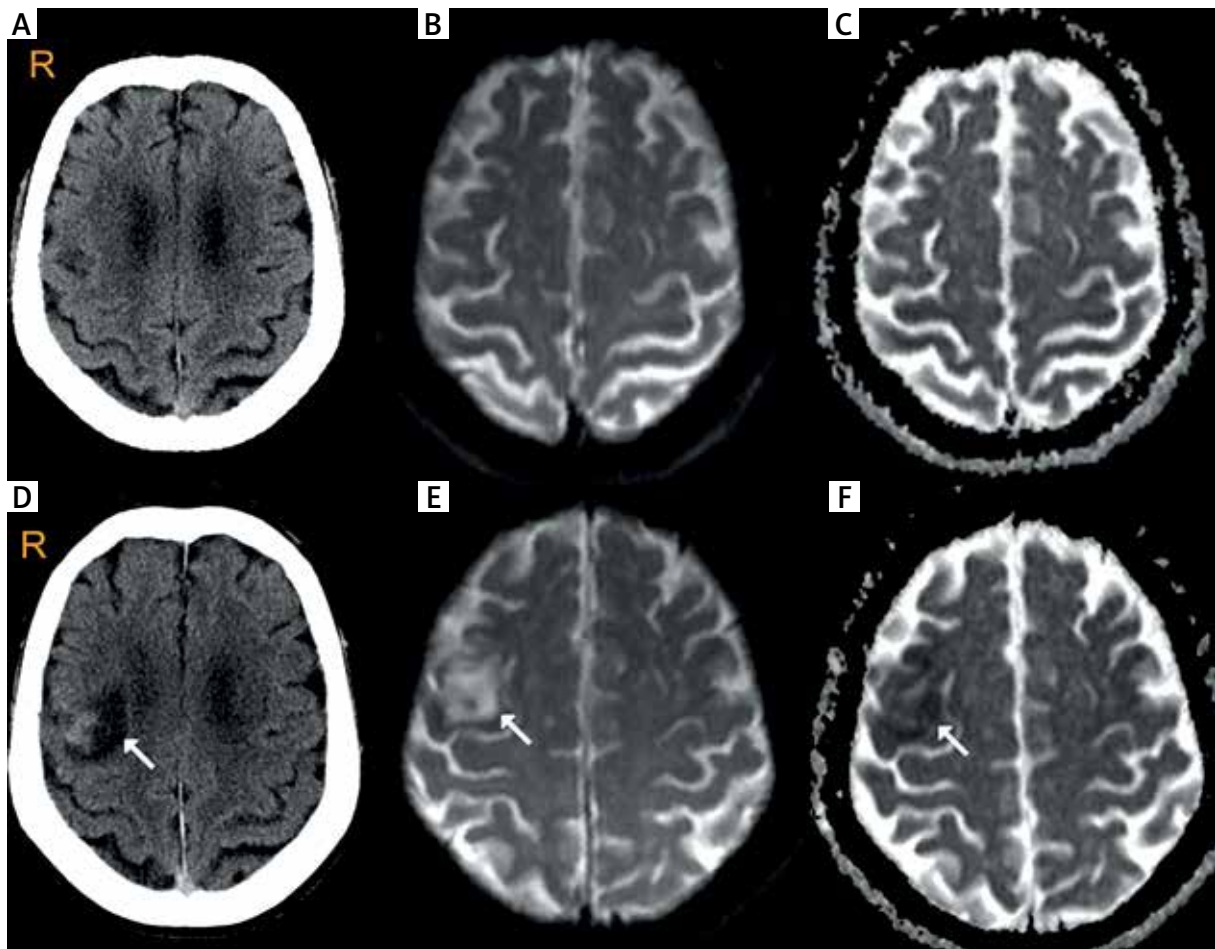
### Treatments and prognosis

Antiplatelet therapy with aspirin and clopidogrel was administered, and three days later, the patient presented with slight involuntary movement in her left foot and leg. The laboratory examination was repeated and showed that the blood glucose level was 7.9 mmol/l, and the HbA1c level was 7.2%. The partial pressure of oxygen was 85.0 mmHg. Since the patient had no new neurological dysfunction, antiplatelet therapy was stopped. Interestingly, the patient's involuntary movement disappeared again on the second day. She was discharged three days later, and her symptoms did not recur at the three-month follow-up.

### Discussion and conclusion

This article described a rare case presenting nonketotic hyperglycaemic HC–HB followed by cerebral stroke. The main findings can be summarised as follows: 1) this older diabetic patient had severe and refractory involuntary movement after hypoglycaemic therapy; 2) despite the confirmed diagnosis of HC–HB, the symptoms did not improve after the combined use of hypoglycaemic therapy and haloperidol; 3) neuroimaging showed a hypo-perfusion in the SMA of the right hemisphere without significant vascular occlusion; and 4) these symptoms disappeared after the discontinuation of antiplatelet therapy and did not recur at the three-month follow-up. This report suggests that the SMA might participate in the motor circuits of nonketotic hyperglycaemic HC–HB, which provides a potential therapeutic target for this subgroup of patients.

The sudden disappearance of nonketotic hyperglycaemic HC–HB symptoms followed by cerebral stroke is rare. To date, only two similar cases involving two patients have been reported [3,9]. This paper describes the first case of nonketotic hyperglycaemic HC–HB

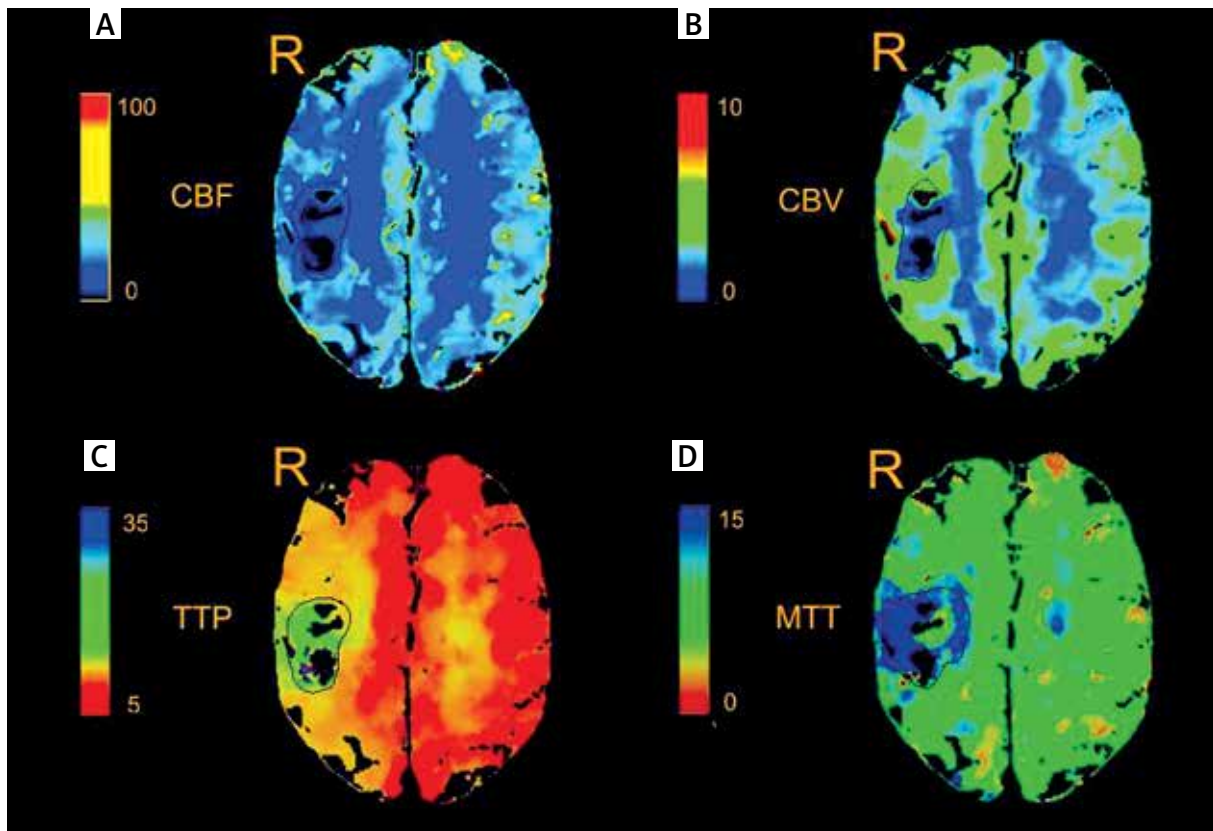


**Fig. 2.** Comparison of neuroimaging before and after HC–HB disappeared. Computed tomography (CT) and magnetic resonance imaging (MRI) scans showed that there was no abnormal signal in the right frontal lobe before the symptoms of HC–HB disappeared (A–C). Following the recovery of HC–HB, CT scan showed a hypointensity lesion in the SMA of the right frontal lobe (D), MRI examination showed high signal intensity in diffusion weighted images (E, white arrow) and low signal intensity in apparent diffusion coefficient (F, white arrow), both in the SMA of the right frontal lobe.

ceasing with an infarction in the contralateral SMA cortex; additionally, the patient differed from the previous two patients in that she did not have hemiparesis on the contralateral side of the ischemic lesion.

Kim *et al.* [9] reported a 70-year-old female with a sudden onset of nonketotic hyperglycaemic HC–HB in the right limbs, which did not disappear until the patient developed an acute infarction in the left basal ganglia six months later; however, the patient suffered from right hemiparesis after the stroke. They speculated that the mechanism was due to the change in the motor circuit following the striatal ischemic lesion located in the basal ganglia opposite to the affected limbs. They also assumed that the HC–HB would never have disappeared if the ischemic stroke did not occur.

Carrion *et al.* [3] described another similar case. A 52-year-old man was seen in the emergency department for recurrent left nonketotic hyperglycaemic HC–HB. Due to his poorly controlled diabetes mellitus, he also presented with a sudden disappearance of left HC–HB during conservative therapy. However, the patient suffered from left-sided hemiparesis, and a repeated brain CT scan showed an ischemic stroke in the middle cerebral artery territory. After physical rehabilitation therapy for approximately one month, he achieved good recovery of his hemiparesis, and at the three-month follow-up, the symptoms of HC–HB did not recur. The authors supplied part of the CT images, from which this paper’s researchers ascertained that the infarction territory involved part of the SMA cortex and subcortex area.



**Fig. 3.** Perfusion computed tomography after HC–HB disappeared. Bilateral cerebral hemisphere cerebral blood flow (CBF), cerebral blood volume (CBV), time to peak (TTP) and mean transit time (MTT) showed asymmetry. The right side frontal lobe (SMA) CBF = 8.46, CBV = 2.10, TTP = 13.69, MTT = 15.47. The left side frontal lobe (symmetric region): CBF = 11.93, CBV = 1.49, TTP = 9.96, MTT = 7.66. The pseudo colour perfusion image showed that the perfusion on the right side was lower than that on the left side.

In the above two similar cases, only the unilateral limbs were affected, and there were no involuntary movement disorders in the mouth and face. Moreover, the locations of the two infarctions could both lead to contralateral hemiparesis, so it was difficult to judge whether the disappearance of HC–HB benefited from ipsilateral hemiparesis or was the result of the primary disease. In this report, all the symptoms of HC–HB resolved after an acute ischemic stroke in the right SMA without functional disturbance of the left leg, arm, mouth or face. Therefore, it is speculated that the SMA participates in the motor circuit of nonketotic hyperglycaemia in HC–HB and that the resolution of HC–HB is ascribed to the inhibited excitability of the SMA cortex by acute infarction. A previous study suggested that repetitive transcranial magnetic stimulation can improve the symptoms of HC–HB by inhibiting the hyperexcitability of the contralateral primary motor cortex (M1) [13]. Inconsistently, a report showed that HC–HB was secondary to a cerebral motor cortex infarction [12];

however, it was not a single lesion but a moyamoya disease in the subcortex. Based on existing knowledge, it is difficult to distinguish between the SMA or M1 as the crucial cortical origin of nonketotic hyperglycaemic HC–HB. For the patient in this study, her left foot and leg started to present involuntary movements again during conversation therapy of the infarction area. The use of related drugs (antiplatelet drugs) was discontinued to identify the interference of medications.

Interestingly, when the antiplatelet therapy was stopped, the patient's left leg was normal again, and during this period, her blood glucose level did not fluctuate. It is speculated that the improvement of the SMA infarction prompts the slight recurrence of HC–HB and the second recovery of HC–HB due to the termination of antiplatelet therapy. This is direct clinical evidence and a verifiable experience to certify that the SMA may be a crucial cortical origin of nonketotic hyperglycaemic HC–HB, at least for the current patient. Previous studies suggested that some subcircuits of movement

disorders originate from several premotor areas, which is consistent with this paper's findings [6,7].

According to previous studies [7], if the basal ganglia's output inhibited the thalamocortical projection neurons in the motor circuit, the movement would be reduced, and vice versa. For patients with nonketotic hyperglycaemic HC–HB, one of the pathophysiologic mechanisms is the imbalance of  $\gamma$ -aminobutyric acid/enkephalin neurons, which is due to metabolic disorders in strata in the hyperglycaemia internal environment [1,7]. Theoretically, HC–HB should disappear if hyperglycaemia is controlled. However, similar to this report, many patients with controlled hyperglycaemia still presented with involuntary movement [4,11]. It is speculated that the underlying reason is the incongruous basal ganglia–thalamus–cerebral cortex circuit. The internal globus pallidus (GPi) also participates in the motor circuit in addition to the basal ganglia and thalamocortical projection [7]. Increasing the output of the basal ganglia and GPi by deep brain stimulation can reduce movement, which is the anatomical basis of neuromodulation [2,7]. The direct clinical evidence of the putamen's involvement in HC–HB is that the symptoms disappear immediately after tumour resection in patients with putamen tumours complicated with HC–HB. Therefore, the contralateral movement should increase if a cerebral infarction occurs in the basal ganglia. It is impossible for basal ganglia infarction to occur except in the internal capsule. Based on the above ratiocination, it is believed that the recovery of HC–HB after ischemic stroke in the basal ganglia or middle cerebral artery territory may result from hemiparesis, but there also is a rearrangement of the traditional basal ganglia–thalamus–cerebral cortex circuit. Although the patient's hemiparesis resolved completely after rehabilitative therapy and without recurrence of HC–HB for the second similar case, this paper considers the decreased excitability of the motor cortex due to ischemia to be involved in the recovery of symptoms. Although the possibility of individual heterogeneity and accidental coincidence cannot be completely ruled out, this study suggests that the SMA may be a selective intervention target for patients with refractory nonketotic hyperglycaemic HC–HB.

There are some limitations in this report. First, the patient had no genetic diagnosis related to chorea or did not undergo cerebrospinal fluid examination. Second, the follow-up period was short, so a long-term follow-up should be conducted to observe the effect of the infarction.

In conclusion, this paper hypothesises that the SMA participates in nonketotic hyperglycaemic HC–HB motor circuits. The dysfunction of the SMA caused by the acute infarction terminated or reset the pathological neural pathway of nonketotic hyperglycaemic HC–

HB and contributed to the disappearance of the involuntary movement on the contralateral side. The SMA may be a selective intervention target for patients with refractory nonketotic hyperglycaemic HC–HB.

## Funding

Traditional Chinese Medicine Science and Technology Development Project of Shanghai Medical Innovation & Development Foundation (No. WL-HBMS-2021007K).

## Acknowledgements

We would like to express our gratitude to all those who helped us during the writing of this manuscript.

## Disclosure

The authors report no conflict of interest.

## References

1. Beal MF, Kowall NW, Ellison DW, Mazurek MF, Swartz KJ, Martin JB. Replication of the neurochemical characteristics of Huntington's disease by quinolinic acid. *Nature* 1986; 321: 168-171.
2. Calabresi P, Picconi B, Tozzi A, Ghiglieri V, Di Filippo M. Direct and indirect pathways of basal ganglia: a critical reappraisal. *Nat Neurosci* 2014; 17: 1022-1030.
3. Carrion DM, Carrion AF. Non-ketotic hyperglycaemia hemichorea-hemiballismus and acute ischaemic stroke. *BMJ Case Rep* 2013; 2013: bcr2012008359.
4. Cheema H, Federman D, Kam A. Hemichorea-hemiballismus in non-ketotic hyperglycaemia. *J Clin Neurosci* 2011; 18: 293-294.
5. Cincotta M, Walker RH. One side of the story; clues to etiology in patients with asymmetric chorea. *Tremor Other Hyperkinet Mov (N Y)* 2022; 12: 3.
6. Defebvre L, Krystkowiak P. Movement disorders and stroke. *Rev Neurol (Paris)* 2016; 172: 483-487.
7. DeLong MR, Wichmann T. Circuits and circuit disorders of the basal ganglia. *Arch Neurol* 2007; 64: 20-24.
8. Hansford BG, Albert D, Yang E. Classic neuroimaging findings of nonketotic hyperglycemia on computed tomography and magnetic resonance imaging with absence of typical movement disorder symptoms (hemichorea-hemiballismus). *J Radiol Case Rep* 2013; 7: 1-9.
9. Kim YD, Cho HJ, Song IU, Chung SW. Complete disappearance of hemichorea-hemiballismus due to hyperglycemia following acute ischemic stroke. *Eur Neurol* 2011; 66: 339-342.
10. Lin JJ, Chang MK. Hemiballismus-hemichorea and non-ketotic hyperglycaemia. *J Neurol Neurosurg Psychiatry* 1994; 57: 748-750.
11. Salem A, Lahmar A. Hemichorea-hemiballismus syndrome in acute non-ketotic hyperglycemia. *Cureus* 2021; 13: e19026.
12. Sierra-Marcos A, Hernández-Vara J, Tur C, Pujadas-Navinés F, Álvarez-Sabín J. Hemichorea-hemiballismus secondary to infarction of the primary motor area: an atypical form of presentation of Moya moya syndrome. *Rev Neurol* 2011; 52: 575-576.
13. Ziemann U, Koc J, Reimers CD, Finkstaedt M, Paulus W. Exploration of motor cortex excitability in a diabetic patient with hemiballismus-hemichorea. *Mov Disord* 2000; 15: 1000-1005.