

Laser method and its effect on the oral mucous membrane in the context of the preprosthetic surgery*

Metoda laserowa i jej wpływ na błonę śluzową jamy ustnej w kontekście chirurgii przedprotetycznej*

Joanna Ryniewicz¹, Wojciech Ryniewicz², Jolanta E. Loster²,
Bartłomiej W. Loster³

¹ Zakład Stomatologii Zintegrowanej, Instytut Stomatologii, Wydział Lekarski, Uniwersytet Jagielloński Collegium Medicum w Krakowie, Polska
Department of Integrated Dentistry, Dental Institute, Faculty of Medicine, Jagiellonian University Medical College in Cracow, Poland
Head: dr hab. J. Pytko-Polończyk, prof. UJ

² Katedra Protetyki Stomatologicznej, Instytut Stomatologii, Wydział Lekarski, Uniwersytet Jagielloński Collegium Medicum w Krakowie, Polska
Department of Prosthodontics, Dental Institute, Faculty of Medicine, Jagiellonian University Medical College in Cracow, Poland
Head: dr hab. G. Wiśniewska, prof. UJ

³ Katedra Ortodoncji, Instytut Stomatologii, Wydział Lekarski, Uniwersytet Jagielloński Collegium Medicum w Krakowie, Polska
Department of Orthodontics, Dental Institute, Faculty of Medicine, Jagiellonian University Medical College in Cracow, Poland
Head: prof. B.W. Loster

Abstract

Introduction. Various treatment methods are applied in the preprosthetic surgery. The most frequently used are lasers, standard excision of the lesion with a scalpel and with an electrocauter. **Aim of the study.** Comparison of the laser method (using the CO₂ laser) with the standard method was chosen as the subject of the analysis. **Material and method.** The tests were conducted in 40 generally healthy patients of both sexes, aged 44-90 years with diagnosed stomatitis prothetica hyperplastica fibrosa (SPHF). Randomly divided patients formed two 20-people groups. In group I patients were subjected to the laser therapy, and in group II proliferative lesions were removed by excision with a scalpel and suture closure. **Results.** Differences in the clinical estimation of the healing process were indicated in both testing groups. In the course of the wound healing after the laser therapy, on the 30th day of observation, the presence of smooth scars was confirmed in 25% of patients, and scarless healing in 75% of patients. In patients undergoing the CO₂ laser therapy, no astringent scars were observed.

Streszczenie

Wstęp. W chirurgii przedprotetycznej wykorzystywane są różne metody zabiegowe. Do najczęściej stosowanych należą laseroterapia, klasyczne wycięcie zmiany przy użyciu skalpela oraz wycięcie kauterem elektrycznym. **Cel pracy.** Jako przedmiot analizy pracy wyznaczono porównanie metody laserowej (z wykorzystaniem lasera CO₂) oraz metody klasycznej. **Materiał i metody.** Badania przeprowadzono u 40 pacjentów ogólnie zdrowych, obojga płci, w wieku 44-90 lat z rozpoznaniem stomatitis prothetica hyperplastica fibrosa (SPHF). Dokonano losowego podziału pacjentów na dwie dwudziestoosobowe grupy. W grupie I pacjenci zostali poddani zabiegowi laseroterapii, w grupie II zmiany rozrostowe usuwano poprzez wycięcie skalpelem i zszycie rany. **Wyniki.** Wykazano różnice w klinicznej ocenie procesu gojenia w obu grupach badawczych. W przebiegu procesu gojenia po zabiegu laserowym, w 30 dniu obserwacji, stwierdzono obecność gładkich blizn u 25% pacjentów, zaś u 75% – gojenie bezbliznowe. U pacjentów operowanych laserem CO₂ nie obserwowano blizn

KEYWORDS:

CO₂ laser, preprosthetic treatment, prosthetic base, scar

HASŁA INDEKSOWE:

laser CO₂, leczenie przedprotetyczne, podłoże protetyczne, blizna

* This project was financed by Jagiellonian University Collegium Medicum (K/ZDS/002557).

* Praca sfinansowana przez Uniwersytet Jagielloński CM w ramach projektu K/ZDS/002557.

In 70% of the operated with the standard procedure one noticed the smooth scars and in 30% of the patients astringent scar occurred. **Conclusion.** On the basis of the clinical estimation of the wound healing process the CO₂ laser method proved more effective than the standard surgical excision in preprosthetic correction of the prosthetic base.

Introduction

Preprosthetic surgery aims at the preparation of the denture-bearing area in such a way that it provides proper fixation and stabilization of the denture and makes the area of the base as wide as possible. The structures, which developed due to the pathological processes, and may disturb the prosthetic procedures, should be excised, and thus a correct structure and functions of components of the stomatognathic system, acting in the scheme of the mutual homeostasis, are restored.^{1,2} The surgical intervention within the structures of the oral cavity also significantly determines further prosthetic effects. The application of the suitable treatment technique enforces the specific scheme of wound healing, so it influences the final effects of healing – inter alia postoperative scars. As is generally known, the scars within the tissues of the oral cavity are not desired elements because they may hinder the stabilization and fixations of dentures.³ In the preprosthetic surgery, various treatment methods are used and the most frequently applied ones are: lasers, standard excision of the lesion with the help of the scalpel, and with the electric cautery.⁴⁻⁶

Comparison of the laser method (using CO₂ laser) with the standard method was determined as the subject of the study. To conduct the tests two ways of surgical treatment were purposely chosen after which different scheme of healing could be observed. The healing after laser therapy takes place in the *sanatio per secundam intentionem* system, and after the excision with the scalpel in the *sanatio per primam intentionem* scheme.⁷

Material and method

The tests were carried out in forty patients who registered for the prosthetic treatment in the

ściąających. U 70% pacjentów po zabiegu klasycznym obserwowano obecność gładkich blizn, natomiast u 30% pacjentów występowały blizny ściąające. **Wniosek.** Na podstawie oceny klinicznej procesu gojenia wskazano zastosowanie lasera CO₂ jako metodę bardziej skuteczną od klasycznego wycięcia chirurgicznego w przedprotetycznej korekcie podłoża protetycznego.

University Dental Clinic in Cracow, and who were using plate dentures. The patients subjected to the tests had proliferate lesions of *stomatitis prothetica hyperplastica fibrosa* of cross-section smaller than 4 mm diagnosed in the vestibule of oral cavity. Generally healthy patients of both sexes aged 44-90 years were selected for testing. Two groups of twenty patients each were randomly formed. In Group I patients underwent laser therapy and in Group II proliferate lesions were removed with a scalpel and wounds were sutured. Afterwards, patients were informed about the postoperative procedure and possible complications.

The exclusion criteria from the tests were: diabetes and smoking delaying the process of wound healing as well as the patient's resignation during the tests, or postoperative complications.

The procedure during the conducted experiment was consistent with the principles of The Declaration of Helsinki. The research was carried out with the consent of The Bioethics Committee of Jagiellonian University (KBET/205/B/2010 from 25th of November 2010) after obtaining the patient's written consent.

Prior to the procedure the patients were asked to rinse the mouth three times a day for three days with the solution of 0.1% chlorhexidine (Eludril f. Pierre Fabre). The treatment procedures were performed under local anaesthesia applying the technique of infiltration. The anaesthetic agent was mepivacaine (3% Mepidont, f. Molteni Dental) without any vasoconstricting agents. The procedures were conducted by the team consisting of an operator and an assistant.

Laser therapy

To excise the proliferative lesion, the CO₂ laser from the Centre of Laser Technology in Warsaw

was applied. It was the CTL-1401 model with pulse mode, whose wavelength is 10 600 nm. The range of the power was 0-12 W and frequency 0.1-10Hz. For the purpose of this study the following laser parameters were used: first, the proliferation was removed by excision (7 W), the remaining structures were smoothed with the help of a smaller power laser (3 W). The frequency of the laser beam was 5 Hz and the pulse duration equalled 0.1 s. Safety precautions were taken: masks and

protective glasses were worn in accordance with the EN207 norm for the operator, the assistant and the patient. During the ablation of the tissues with the laser beam suction was used to remove the largest possible amount of laser plume.

Standard therapy

Within the second group the patients under local anaesthesia were subjected to the procedure of excision of a proliferative lesion with the standard

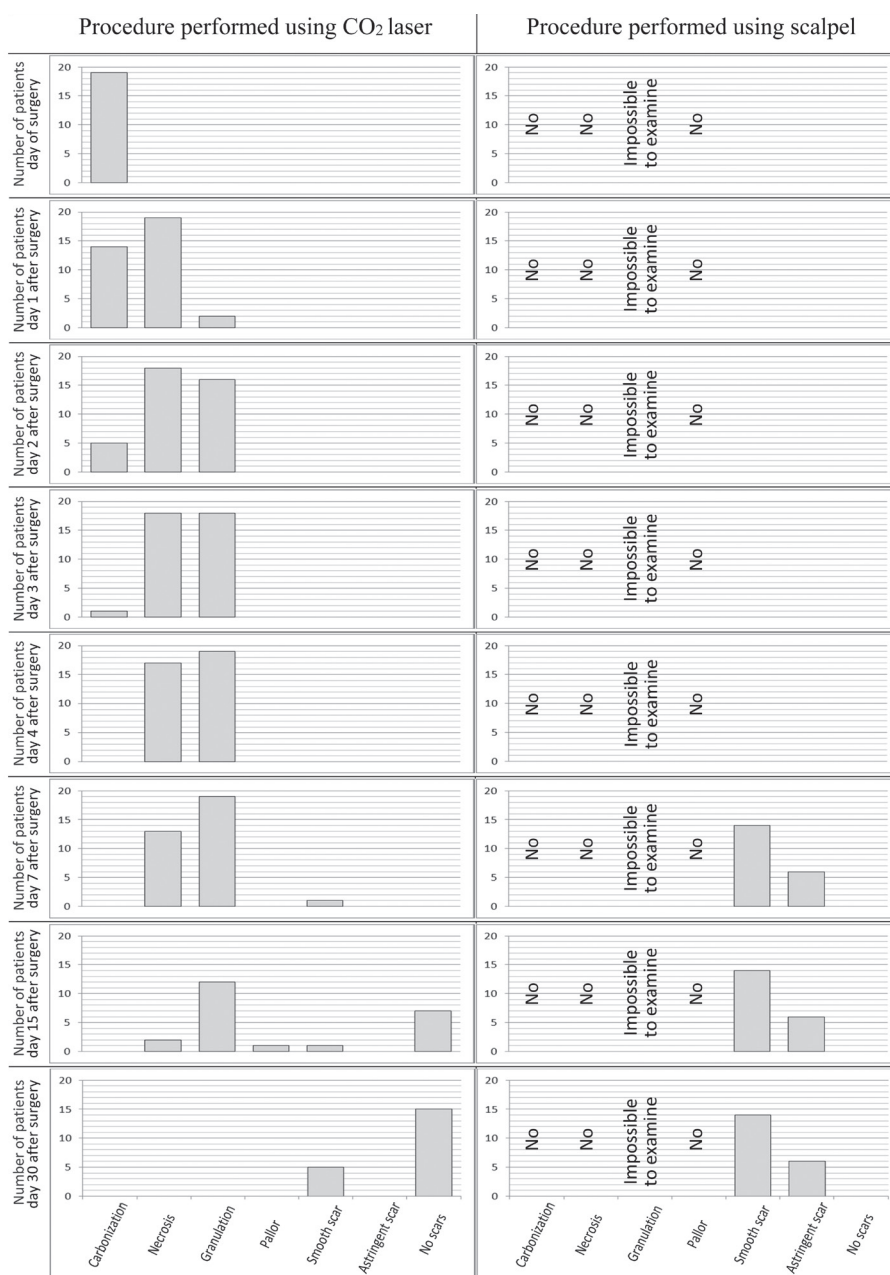


Fig. 1. Clinical estimation of the healing process after the laser and standard therapy.

method – instrumented by the surgical laser with wound suture. The patients had single-knotted stitches applied. As a suturing material nylon thread of 4/0 with atraumatic tapercut needle was selected. After seven days, stitches were removed.

The testing protocol included taking history, performing physical examination and providing photographic documentation taken before, immediately after and on the 1st, 2nd, 3rd, 4th, 7th, 15th, 30th day after the procedure.

Results

Figure 1 presents clinical stages of the process of healing after the laser and standard therapy. On the basis of the analysis of the photographic documentation clinical phases of the process of healing after the laser therapy have been described. The presence of the areas of tissue carbonization – as observed from the day of the procedure – maximum three days after the therapy. The next stage in the process of healing – after the

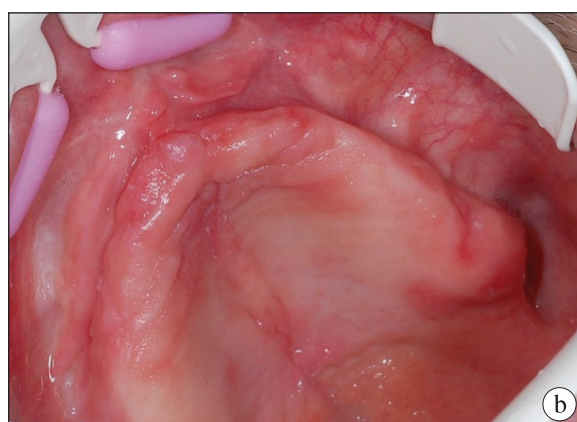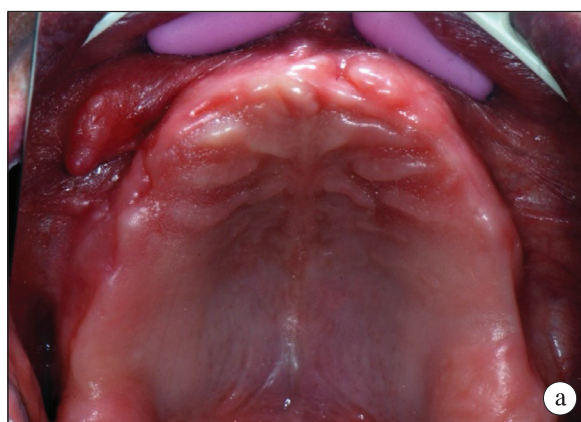


Fig. 2. SPHF in the vault of the oral vestibule: a) before the laser therapy, b) before the standard procedure (own material).

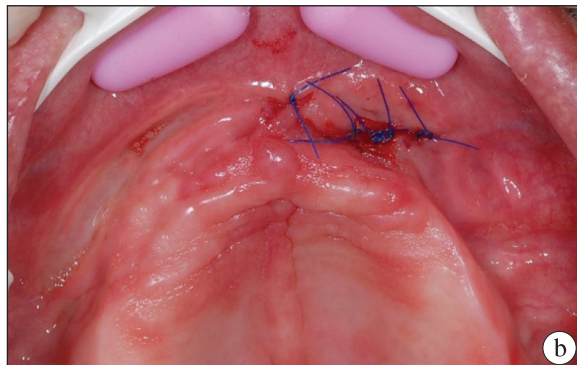
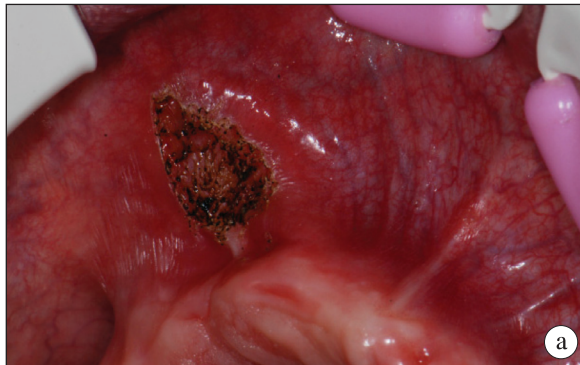


Fig. 3. Clinical condition immediately after SPHF excision; a – laser method, b – standard method (own material).

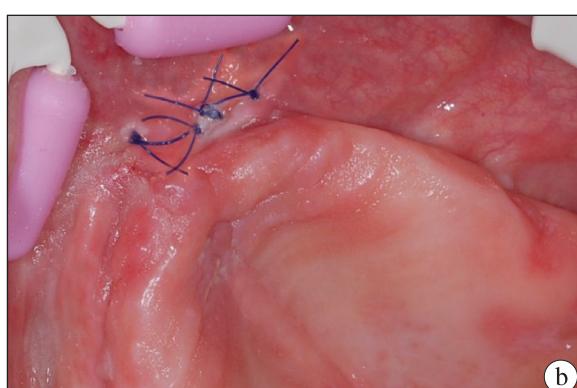
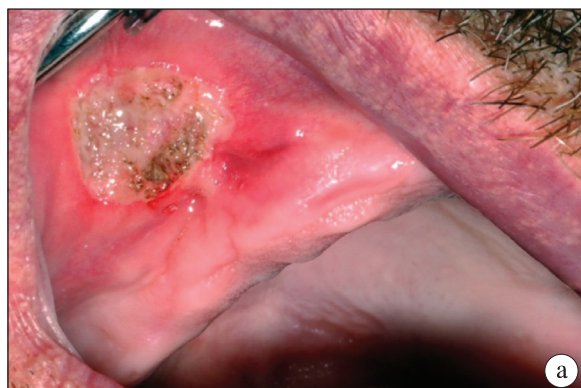

Fig. 4. Clinical condition on the 1st day after the SPHF excision; a – laser therapy, b – standard method (own material).

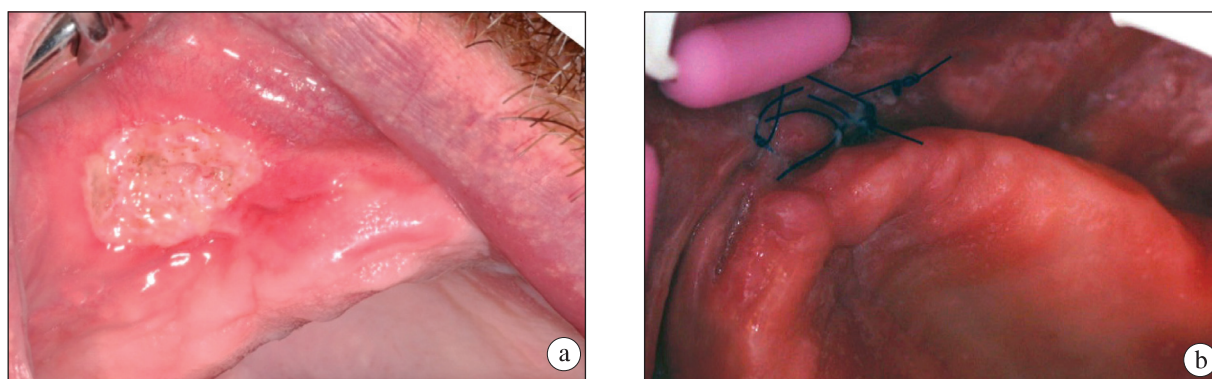


Fig. 5. Clinical condition two days after the SPHF; a – laser metod, b – standard metod (own material).

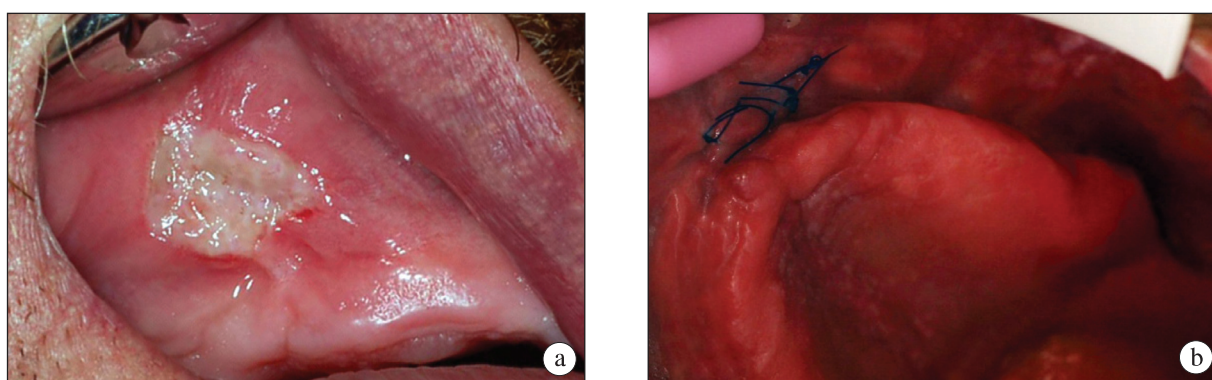


Fig. 6. Clinical condition three days after the SPHF; a – laser metod, b – standard metod (own material).

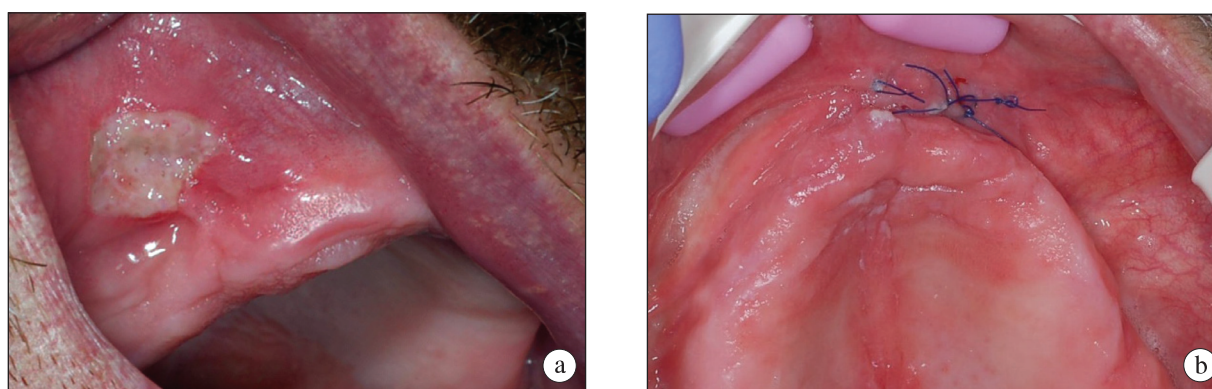


Fig. 7. Clinical condition four days after the SPHF; a – laser metod, b – standard metod (own material).

application of CO₂ laser – is necrosis of surface tissues – from the period of the 1st to even 15th day after the procedure. Almost simultaneously the presence of the process of granulation was reported (from the 1st to the 15th day after the procedure). As the final result of tissue healing the presence or absence of the scars after the laser therapy were estimated.

During healing after the laser therapy, on the

30th day of observation the presence of smooth scars in 25% of patients and scarless healing in 75% of patients were stated. To compare, on the 15th day only 5% of smooth scars were noticed, 35% of complete scarless healing, but in the rest of the patients the process of healing was still incomplete. In patients treated with the CO₂ laser, astringent scars were not confirmed. In the group of patients undergoing the standard method the

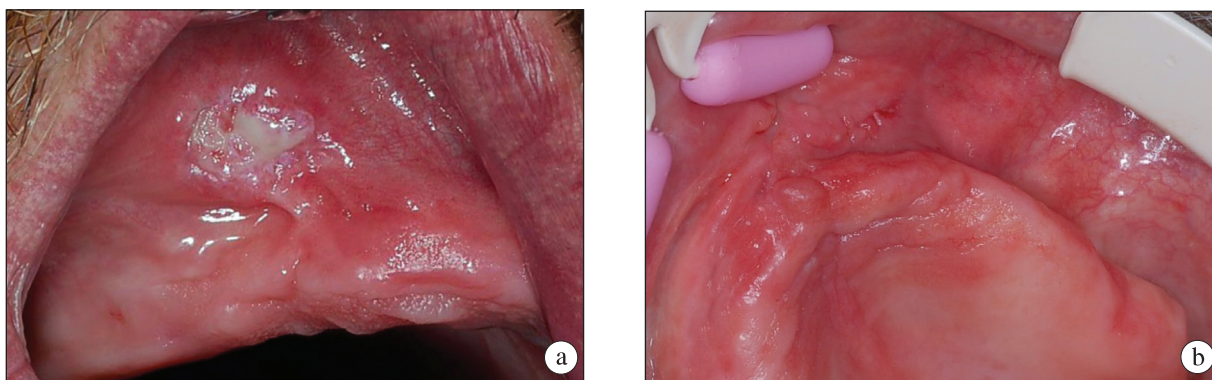


Fig. 8. Clinical condition seven days after the SPHF; a – laser metod, b – standard metod (own material).

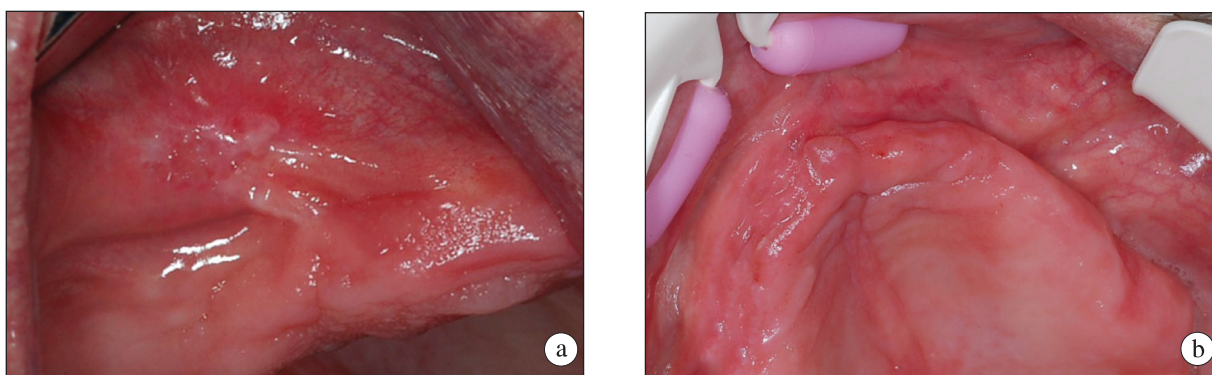


Fig. 9. Clinical condition 15 days after the SPHF; a – laser metod, b – standard metod (own material).

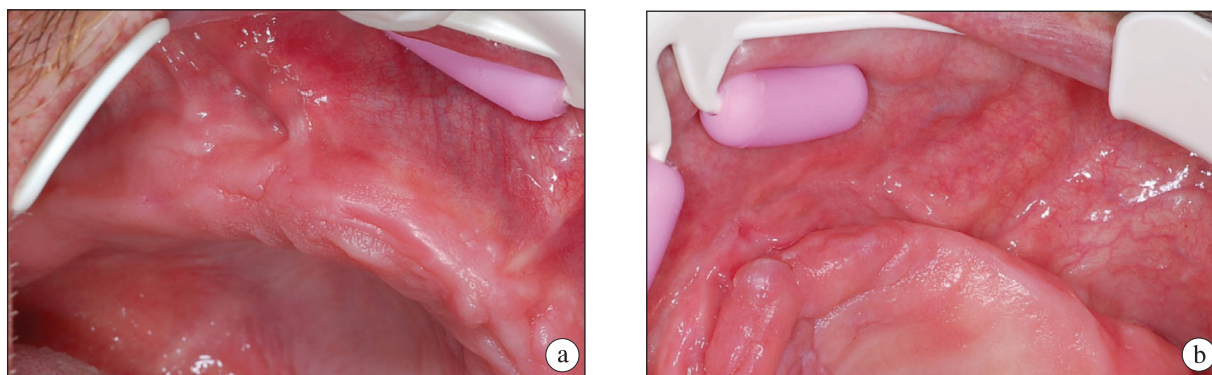


Fig. 10. Clinical condition 30 days after the SPHF; a – laser metod, b – standard metod (own material).

initial clinical stages of the healing process were not analysed because of their absence or difficulties connected with the clinical estimation. However, the attention was drawn to the final effect of the healing process which differs significantly in view of the period of time when scars develop and their type. Clinically, complete wound healing process was observed on the 7th day postoperatively.

Smooth scars occurred in 70% of the patients

while astringent scars in 30%. The clinical cycle of wound healing after the laser therapy is presented in pictures 2a–10a and after the procedure with scalpel in pictures 2b–10b.

Discussion

The radiation of the laser on the biological tissue is dependent on, among other things, the type of laser applied. In therapeutic procedures

lasers of different wavelength are used. They have the following absorbents: melanin, hemoglobin, protein and water.⁸ Thanks to the presence of the radiation absorption spectrum correspondent to the specific absorbent, larger or smaller affinity of the laser to the particular irradiated tissue takes place. It means that the laser activity can be selective and not destructive to adherent structures.⁹⁻¹¹ Besides the range of the spectral laser light, the radiation of lasers on the biological tissue depends on the intensity of radiation, that is the energy and duration of laser impulse.^{12,13} When analysing the mutual dependence between the density of the radiant power of the laser and the duration of the impulse, the following types of laser influence on the biological tissue can be distinguished: photochemical, photothermal and photoablative effects and plasma ablation.⁹ The radiation of the CO₂ laser on the mucous membrane of the oral cavity is related to its affinity to water as a fundamental absorbent together with the photothermal mechanism. The photothermal effects of the CO₂ laser are based on the non-selective principle of operation, due to which typically surgical activity can be achieved.¹⁴ Electromagnetic radiation of the CO₂ laser changes into the thermal energy in a small volume of the tissue. It causes direct thermal damages. At a temperature above 42°C, irreversible hyperthermia with dysfunction occurs. At a temperature above 60°C, denaturation of proteins takes place. At 100°C, vaporization of the tissue water appears, but above 150°C carbonization of the tissue takes effect so as to finally when temperature exceeds 300°C the phenomenon of pyrolysis could develop – the process of thermal decomposition without the activity of oxygen and other oxidizing factors. To continue the analysis of the pyrolysis – the next rise of temperature to around 500°C at the place of carbonization leads to the occurrence of a bright point on the surface of the tissue, which causes the emission of the laser plume.^{15,16} Referring to the type of the absorbent which operates in the case of the CO₂ laser, it should be mentioned that it has implications in the effects of the CO₂ laser activity on the tissue. In the structures intensively hydrated, inter alia submitted to the activity of

the anaesthetic agent, activity of laser radiation penetrates more shallowly than in tissues which are less hydrated, and simultaneously it causes smaller thermal changes. The basis of this phenomenon is that it is water and not the biological area that absorbs significant part of laser radiation.⁸

Depending on the depth of the penetration of the laser light, a different scheme of healing of mucous membrane occurs due to the different ability to restore particular component structures. Mucous membrane of the oral cavity comprises the epithelium, basement membrane, lamina propria of the connective tissue and submucosa.¹⁷ Epithelium covering the mucous membrane is a multilayer flat, and depending on the location in the oral cavity it can have the characteristics of keratosis. The innermost layer of the epithelium is the basement layer. It is the reproductive zone and its feature is the greatest activity of metabolism. The basement layer is also the area of synthesis of melanin in the mucous membrane. The next layer is the Malpighian Layer called also spinous. The cells of the zone remain in the early phase of maturation, in the cytoplasm they contain small granules filled with phospholipids (Odland bodies). The following layer of epithelium is the granulation layer, named after the cells of granulation with keratohyalin. Thanks to this layer, the epithelium becomes opaque. The outermost layer is the *stratum corneum*, which contains flat cells of the greatest maturation subjected to the process of continuous exfoliation.¹⁷ The thermal effects related to the epithelium of the mucous membrane only are excised owing to the great activity of the cells of the basement layer of the epithelium and stages of cell maturation in its particular layers leading to full regeneration of the damaged tissue. In the tests by *Stankiewicz* the dynamics of the wound healing process after the CO₂ laser conducted on the animal model was analysed.¹⁸ It was stated that the application of proper parameters of laser activity: frequency 2 Hz, power 0.5 W, impulse duration of 0.04s in 10s allows to carry out the procedure within the very epithelium of the oral mucous membrane. Microscopic tests by *Stankiewicz* showed that within the defect in the epithelium there was no

carbonation zone, healing took eight days and regenerated epithelium had no traces of previous damage.

The further structure of the mucous membrane located under the epithelium is built from the basement substance of the connective tissue – basement membrane. It ensures adhesion of the epithelium to the lamina propria of the mucosa and plays the role in response to the damage of the tissue.¹⁷ The subsequent structure of the oral mucous membrane is lamina propria. It comprises the papillary and reticular layers. In the basement substance one can notice the presence of collagen fibres, elastic fibres, argentaffin fibres as well as numerous cells of the connective tissue and alluvial cells. Within the lamina propria of the oral mucous membrane there are few blood vessels. The basic vascularization of the mucous membrane is located in the submucous membrane, which is the flaccid connective tissue. Apart from the vessels, there are also salivary glands, a network of lymphatic vessels and fat cells. The presence of collagen and elastic fibres allows it to play the protective function against mechanical injuries.¹⁷ Thermal damages deeper than the basement membrane, and covering the lamina propria of the mucous membrane and submucous membrane, constitute the specific model of the thermal destruction. The overheating zone is located in the deepest area, then there is the coagulation zone. The next layer is the zone of carbonization, the zone of vaporization and pyrolysis zones – without the structural presence of the tissue.¹⁵ Although the destruction of the tissue with the CO₂ laser is caused by heat, the wound induced by this laser is not a burn because the emitted photons are exponentially absorbed by water and do not transfer energy by conduction, as it happens in the case of burns.^{19,20}

In the case of surgical procedures which are intended to prepare the patient for the prosthetic treatment, the final positive effect of therapy is achieved if after the procedure no considerable process of scar formation is noted. The presence of the scar in the area of the prosthetic field may significantly impede the fixation and stabilization of the denture. In the publications there is a view

that in the oral cavity the tissue healing proceeds more dynamically and with rarer scar formation than in the skin.²¹⁻²³

In the study by *Mak et al.* the model of wound healing in the area of the mucous membrane of the oral cavity and the skin was compared. In the healing process of mucosa considerably less advanced process of scar formation can be observed both clinically and histologically than in the case of skin healing. It was noticed that there was a great difference in the number of mastocytes, macrophages and TGF β in the final stage of the healing process (maturation of the scar) to the detriment of the mucous membrane of the oral cavity. Although the number of myofibroblasts within the mucosa was described as significantly larger, slight contractility of remodeled scar was reported. The authors concluded that earlier dehiscence of the inflammation phase during the healing process as well as reduced wound contractility cause that healing in the oral cavity proceeds without scars.²³ At the same time, *Mak et al.* added that not only the number of myofibroblasts but also extracellular environment regulating their function are responsible for scar formation.

The layer of vascularization in the last phase of healing is not without significance. Tests conducted by *Amadeu et al.* showed a characteristically greater number of blood vessels within the hypertrophied scars and in keloids than in the healthy skin. So, a higher level of blood supply in the period in which the regression of vessels should take place may forecast the presence of hypertrophied scar.²⁴ *Glim et al.* also examined possible causes of various processes of healing within the mucous membrane of the oral cavity and the skin. They found differences in expression of extracellular components, such as procollagen I and tenascin C. It was observed that wounds of mucous membrane contain less inflammatory mediators, blood supplies, higher level of reepitelization and faster proliferation of fibroblasts.²¹

Grzesiak-Janias et al. compared the effectiveness of standard methods with laser technique of plastic operation of frenulum of the tongue and the lip, and pointed that scars in the case of the laser method are

not visible, unlike the standard method.³ Similar estimation was performed in the process of tests in the present study. It was concluded that scars after the laser procedure, if they appear, have smooth, slightly visible form, as opposed to the effects of treatment with a scalpel. Scars observed after the excision of proliferative lesion with a scalpel in 70% of patients had a smooth character. In 30% of patients, astringent scars remained after the procedure.

In some cases, specific location of proliferative lesions, when standard technique is applied in order to remove proliferations of mucous membrane, may cause development of contractures and astringent scars. It especially concerns lesions located within the oral vestibule. *Fisher et al.* indicate that the use of the CO₂ laser to remove fibroepithelial proliferations of prosthetic origin,

located at the bottom of the vestibule, induces slight tissue lesions and slight shallowing of the depth of the oral vestibule.²⁵ It is confirmed by the observations carried out in the process of own tests. *Pogrel et al.* applying the CO₂ laser to remove the proliferate tissue caused by the badly fitting dentures, correcting the dentures and putting them in the oral cavity immediately after the procedure, reported even 20% decrease of the depth of the vestibule after six weeks of wearing new dentures.²⁶

Conclusion

On the basis of the clinical estimation of the healing process the use of the CO₂ laser has been demonstrated as a more effective method than the standard surgical excision in preprosthetic correction of the denture-bearing area.

References

1. *Jankelson B, Hoffman GM, Hendron JA*: The physiology of the stomatognathic system. *J Am Dent Assoc* 1952; 46: 375-386.
2. *de Arruda Paes-Junior TJ, Cavalcanti SC, Nascimento DF, Saavedra Gde S, Kimpara ET, Borges AL, et al.*: CO(2) Laser Surgery and Prosthetic Management for the Treatment of Epulis Fissuratum. *ISRN Dentistry* 2011, 2011; article 282361. doi: 10.5402/2011/282361.
3. *Grzesiak-Janias G, Janias A, Ratajek-Gruda M*: Porównanie skuteczności metod klasycznych z techniką laserową plastyki wędzidełka wargi górnej, dolnej i języka. *Dent Med Probl* 2004; 41: 39-43.
4. *Wiśniewska G, Majewski S, Loster BW*: Kliniczna ocena stosowania lasera CO₂ do przedprotetycznej korekty tkanek miękkich na podstawie własnych sześciolletnich obserwacji. *Protet Stomatol* 2002; 52: 69-75.
5. *Wiśniewska G, Loster BW, Majewski S*: Stany zapalne rozrostowe typu włóknistego u użytkowników protez płytowych – etiologia i zasady leczenia na podstawie własnych doświadczeń. *Czas Stomatol* 2004; 57: 543-548.
6. *Ryniewicz J, Ryniewicz WI, Loster JE, Rogala M, Loster BW*: Analysis of microcirculation in the wound healing process after carbon dioxide laser therapy of stomatitis prothetica hyperplastica fibrosa. *J Stomatol* 2015; 68: 661-668.
7. *Kumar V, Cotran RS, Robbins SL*, editors: *Robbins Basic Pathology*. Philadelphia: Saunders, 2003.
8. *Convissar RA*: *Principles and Practice of Laser Dentistry*. St Louis: Mosby Elsevier, 2011.
9. *Boulnois JL*: Photophysical processes in recent medical laser developments: a review. *Lasers Med Sci* 1986; 1:47-66.
10. *Mustafa EA, Al Kawas S*: The effect of gallium-arsenide laser irradiation on odontogenesis. *Journal of International Dental And Medical Research* 2010; 3, 2: 52-56.
11. *Ismaili B, Bokonjic D*: Short-term low-level laser therapy attenuates inflammation and production of interleukin-1, but elevates the level of matrix metalloproteinase 9 in chronic periodontitis. *Journal of International Dental And Medical Research* 2014; 7, 1: 7-13.
12. *Ryniewicz J, Ryniewicz W, Pytko-Polończyk J*: Evaluation of the effect of CO2 laser radiation on root cementum. *J Stomatol* 2013; 66: 341-350.
13. *Ryniewicz J, Ryniewicz W, Loster BW*: Analysis of

- an effect of radiation of CO₂ laser on the enamel. *J Stomatol* 2012; 65: 62-70.
14. *Goldman L*: Chromophores in tissue for laser medicine and laser surgery. *Lasers Med Sci* 1990; 5: 289-292.
 15. *McKenzie AL*: Physics of thermal processes in laser-tissue interaction. *Phys Med Biol* 1990; 35: 1175-1209.
 16. *Ozevren H, Kahveci R*: Aseptic spondylodiscitis occurring after percutaneous laser disc decompression. *Journal of International Dental And Medical Research* 2015; 8, 1: 31-33.
 17. *Brand L*: Anatomy of orofacial structures. St. Louis: Mosby Co., 1990.
 18. *Stankiewicz J*: Analiza dynamiki procesu gojenia się ran błony śluzowej języka szczurów po zastosowaniu promieniowania lasera CO₂. *Stomatol Współcz* 2011; 18: 14-21.
 19. *Bellina JH, Seto VJ*: Pathological and physical investigations into CO₂ laser-tissue interactions with specific emphasis on cervical intraepithelial neoplasm. *Lasers Surg Med* 1980; 1: 47-69.
 20. *Sulijaya B, Soeroso Y, Sunarto H, Suri PA, Nazar K*: The Clinical Management of Nd-YAG laser combined with endodontic treatment in localized severe periodontitis patient: Case evaluation. *Journal of International Dental And Medical Research* 2016; 9: 392-397.
 21. *Glim JE, van Egmond M, Niessen FB, Everts V, Beelen RH*: Detrimental dermal wound healing: What can we learn from the oral mucosa? *Wound Repair Regen* 2013; 21: 648-660.
 22. *Larjava H, Wiebe C, Gallant-Behm C, Hart DA, Heino J, Häkkinen L*: Exploring scarless healing of oral soft tissues. *J Can Dent Assoc* 2011; 77: b18.
 23. *Mak K, Manji A, Gallant-Behm C, Wiebe C, Hart DA, Larjava H, et al.*: Scarless healing of oral mucosa is characterized by faster resolution of inflammation and control of myofibroblast action compared to skin wounds in the red Duroc pig model. *J Dermatol Sci* 2009; 56: 168-180.
 24. *Amadeu T, Braune A, Mandarin-de-Lacerda C, Porto LC, Desmoulié`re A, Costa A*: Vascularization pattern in hypertrophic scars and keloids: a stereological analysis. *Pathol Res Pract* 2003; 199: 469-473.
 25. *Fisher SE, Frame JW*: The effects of the carbon dioxide surgical laser on oral tissues. *Br J Oral Maxillofac Surg* 1984; 22: 414-425.
 26. *Pogrel MA, Yen ChK, Hansen LS*: A comparison of carbon dioxide laser, liquid nitrogen cryosurgery and scalpel wounds in healing. *Oral Surg Oral Med Oral Pathol* 1990; 69: 269-273.

31-155 Kraków, ul. Montelupich 4
Tel.: +4812 4245436
e-mail: wojciech.ryniewicz@uj.edu.pl

Received: 28th November 2016

Accepted: 14th July 2017