

Principles of surgical treatment of jaw osteomyelitis in patients with drug addiction

Zasady chirurgicznego leczenia zapalenia szpiku kości szczęk u pacjentów z uzależnieniem narkotykowym

Vladislav A. Malanchuk, Igor S. Brodetskyi

Department of Oral and Maxillo-Facial Surgery, National O. Bogomolets Medical University, Kiev, Ukraine

Katedra Chirurgii Stomatologicznej i Szczękowo-Twarzowej, Narodowy Uniwersytet Medyczny im. O. Bohomolca, Kijów, Ukraina

Head: prof. V.A. Malanchuk

Abstract

The aim of this study is to improve the effectiveness of treatment of drug addicted patients with osteomyelitis of the jaws by developing the basic principles of surgery. A total of eighty patients with chronic osteomyelitis of facial bones were examined and treated in the Kiev city clinical hospital №12 MFD №2 from 2012 to 2014. The average age of patients was 28.65 ± 0.43 years, primarily males (77.2%). Medical history revealed that sixty patients (75%) had previously suffered from viral hepatitis (B, C), ten patients (12.5%) had been HIV-infected earlier. All the patients reported the use of the drug from the group of amphetamines – Pervitin («Vint»); however, half of the patients (50%) pointed out that they also used other drugs, including “shirka” (opiates) and “methadone” (derivative of heroin). During hospitalization, all the patients underwent a standard general medical examination, radiological evaluation (CT scanning) and a surgical intervention – sequestrectomy, sequestronecrectomy, necrectomy, and resection of the affected part of the jaw.

Streszczenie

Celem pracy była poprawa skuteczności leczenia zapalenia szpiku szczęk u osób uzależnionych od narkotyków poprzez rozwijanie podstawowych zasad operacyjnych. Obserwowano i leczono 80 chorych z przewlekłym zapaleniem szpiku kości twarzy leczonych w klinice KMKL №12 №2 SCHLV w okresie od 2012 do 2014 roku. Średni wiek pacjentów wynosił $28,65 + 0,43$ roku, przeważnie mężczyźni (77,2%). Z wywiadu wynikało, że 60 pacjentów (75%) przechodzili wirusowe zapalenie wątroby (B, C), 10 pacjentów (12,5%) było wcześniej zakażonych wirusem HIV. Wszyscy pacjenci zgłaszali stosowanie pervitynu z grupy amfetamin (“VINT”), jednak ponad połowa pacjentów (50%) wskazywała używanie innych narkotyków, w tym “shirka” (opiat) i “metadonu” (pochodnej heroiny). U wszystkich pacjentów w szpitalu przeprowadzono standardowe ogólne badania kliniczne, radiografię (CT) i interwencję chirurgiczną: sekwestrektomię, sekwestronekrectomię, nekrectomię i resekcję zmienionych chorobowo kości szczęk.

KEYWORDS:

surgical treatment, jaw osteomyelitis of drug addicted patients, pervitin, «krokodil».

HASŁA INDEKSOWE:

leczenie chirurgiczne, zapalenie szpiku szczęk u pacjentów uzależnionych od narkotyków, pervityn, “krokodil”

Relevance of the topic

The problem of treatment for drug addicted patients with jaw osteomyelitis is acute. The number of hospitalizations with this condition in specialized maxillofacial departments remains high (from 70 to 110 cases per year, that is 6-9.5% of the total number of patients). The main cause of

emergence and the increasing level of this disease is the use of self-made drug «Pervitin» («vint» «jeff», «mulka», «krokodil») (Volik, 2000). The components of this drug are well known (pseudoephedrine, red phosphorus, iodine) and directly affect the blood circulation of the jawbone leading to osteonecrosis (Poghosyan et al., 2014).

The clinical course of osteomyelitis of the jaws in patients with history of drug addiction is complicated by drug-associated diseases: HIV, hepatitis B and C, tuberculosis. According to our observations (Malanchuk, Brodetskyi, 2012), 56% of these patients showed blood AB (antibodies) and AG (antigens) to hepatitis C.

Clinically, the disease has a difficult, atypical course, with diffuse exposing of the alveolar bone, the presence of dense painless infiltrates, prolonged aching pain along the branches of the trigeminal nerve, large purulent exudates out of many fistulas of the mucosa and the skin, spreading of the process to the previously unaffected area of the jaws and the emergence of new lesion foci outside the demarcation line, high recurrence rate in the postoperative period, septic complications (sepsis, brain abscess, meningitis). As a result, it leads to disability of patients or death (Malanchuk et al., 2007) (Fig. 1, 2, 3)

As for the surgical treatment of this pathology we use traditional methods – sequestrectomy, sequestronecrectomy, necrectomy, resection of

the jaws (Saberov, Drobishev, 2011). However, there are no clear recommendations in which cases a particular method of surgery should be used, because the pathogenesis of such type of osteomyelitis has not been studied sufficiently yet. Therefore, the purpose of this research is to improve the effectiveness of treatment of drug addicted patients with osteomyelitis of the jaws by developing the basic principles of surgery.

Materials and methods

The authors had examined and treated 80 patients with chronic osteomyelitis of facial bones in the KCCH №12 MFD №2 from 2012 to 2014. The average age of patients was 28.65 ± 0.43 years, primarily males (77.2%). Isolated lesions of the osteomyelitis in the upper jaw was observed in 17 cases (21.25% of patients), isolated lesions of the mandible – in 38 cases (47.5% of patients), combined lesion of both jaws was reported in 25 cases (31.25% of patients). In 40 cases (50%) the process involved at least half of the alveolar process and the bodies of the upper or lower jaws,

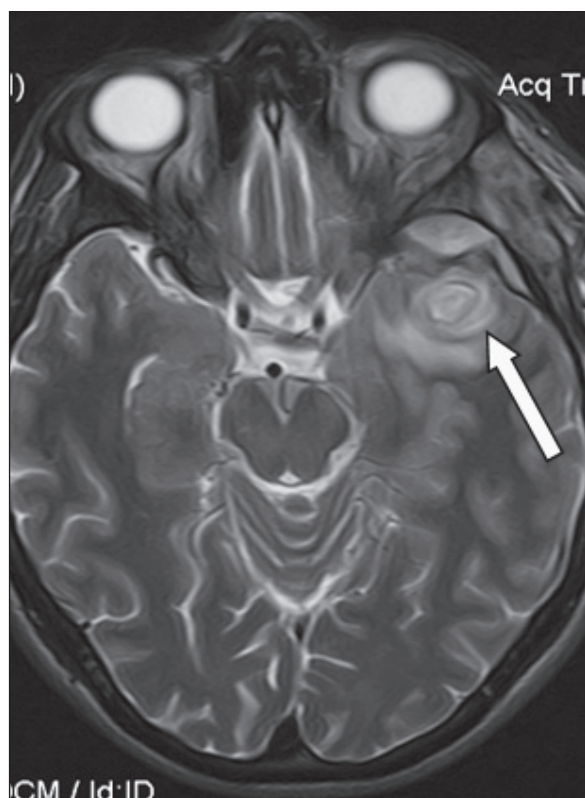


Fig. 1. RI image of patient L., DS: abscess of the left frontal lobe of the brain in its formative stages (arrow shows the abscess).

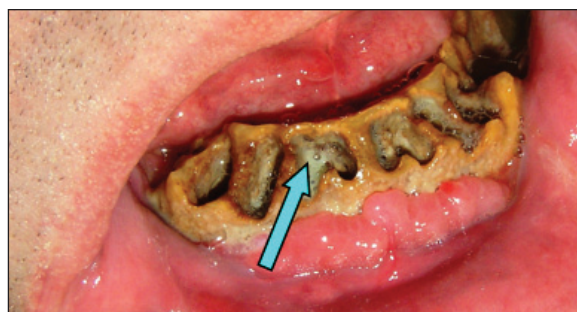


Fig. 2. Patient B., DS: chronic osteomyelitis of the mandible (arrow shows the exposure of alveolar bone).

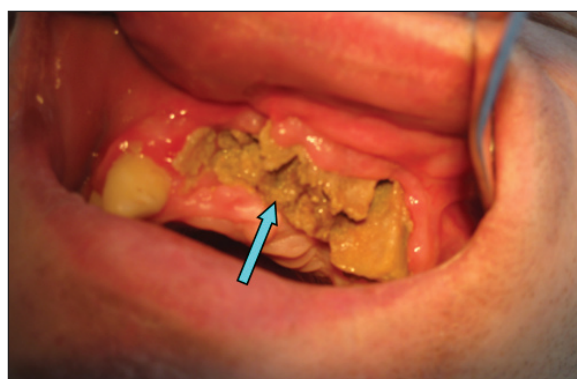

Fig. 3. Patient K., DS: chronic osteomyelitis of the maxilla (arrow shows the exposure of alveolar bone).



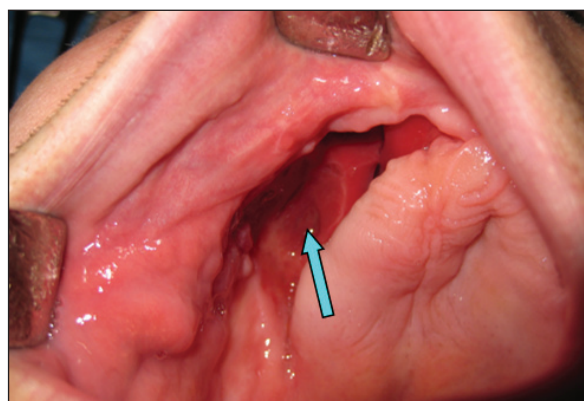


Fig. 4. Patient Z., DS: postoperative defect of the upper right jaw (arrow shows the huge oroantral communication).

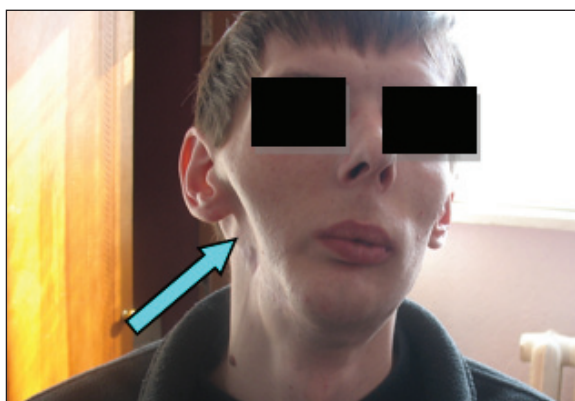

Fig. 5. Patient S., DS: postoperative defect of the right half of the mandible (arrow shows retraction of the soft tissues).

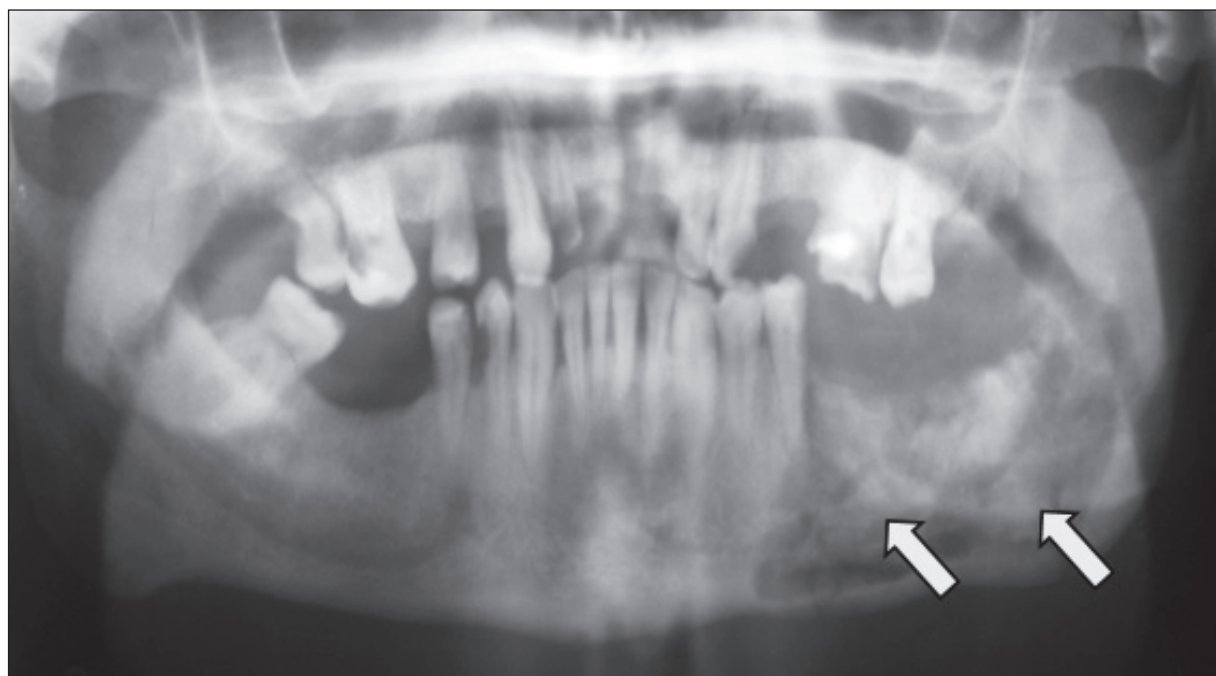


Fig. 6. Orthopantomogram of patient S., DS: diffuse osteomyelitis of the left half of the mandible (the presence of the formation of the body and partially sequester the branches of the lower jaw, resorptive fracture in the left corner (arrows)).

in 16 cases (20%) – areas from 3 to 5 alveolar sockets, in 24 cases (30%) the process spread to branch, angle and body of the mandible.

The duration of the disease varied from 4 to 48 months, on average – 19.25 ± 2.275 months.

From the medical history it was known that 60 patients (75%) had previously suffered from viral hepatitis (B, C), 10 patients (12.5%) had been HIV-infected earlier. In 20 cases (25%) some severe chronic somatic diseases were revealed (peptic ulcer, chronic bronchitis and pneumonia,

renal failure). All the examined patients reported that they were smokers (100%).

The duration of taking addictive substances among the surveyed persons averaged 3.45 ± 0.321 years. All the patients reported the use of the drug from the group of amphetamines – Pervitin (“Vint”), however, half of the patients (50%) pointed out that they also used other drugs, including “shirka” (opiates) and “methadone” (derivative of heroin).

During hospitalization, all patients underwent



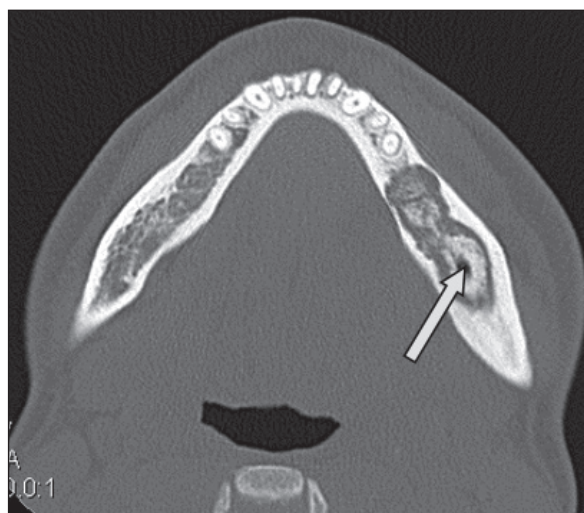


Fig. 7. CT of patient S, DS: chronic osteomyelitis of the left half of the mandible (arrows shows formed sequestration).

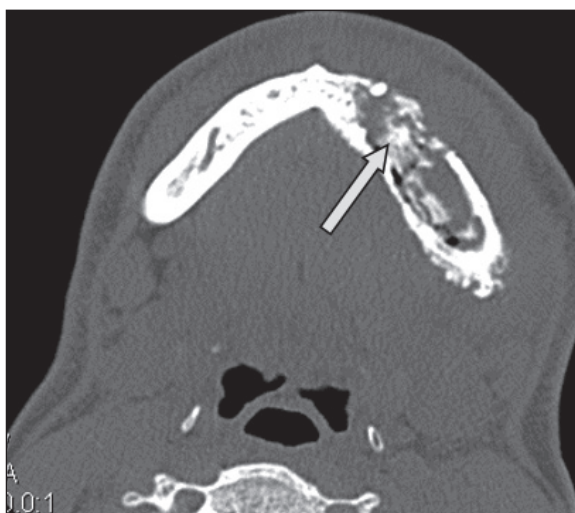

Fig. 8. CT of patient D., DS: chronic osteomyelitis of the left half of the mandible (arrows show formed sequestration and the area of necrosis to be removed).

a standard general medical examination, radiological evaluation (CT scanning with 3-D visualization).

All patients underwent the surgical intervention—sequestrectomy, sequestrectomy, necrectomy, resection of the affected part of the jaw.

The results of research

The conducted surveys allowed establishing the basic principles of surgical treatment of osteomyelitis of the jaws in cases of drug addiction:

1. If the demarcation zone around the mandibular sequestration is clearly formed, which is confirmed clinically and radiographically (according to data of 3D-CT), it is recommended to perform standard sequestrectomy and to tamponade the wound with a swab with iodoform and partial closure of the wound with coaptation sutures on soft tissue (Fig. 6, 7).
2. If some sequestration areas are not totally formed except the formed one on the lower jaw, the necrotic bone should be removed reaching the clinically healthy bone tissue, in other words, performing sequestrectomy of the mandible. In this case, there is a possibility of recurrence and progression, since a demarcation of the damaged bone has not been completed yet (Fig. 8).
3. If the signs of sequestration are not clinically and radiologically observed, but the lower jaw or a part of it shows all signs of non-viability, necrectomy should be performed reaching the borders of clinically healthy bone. In this case, the issue of preserving or removing the edge of the mandible is solved during the operation, according to the risk of the resorptive fracture of the mandible (Fig. 9).
4. The tactic of expectation (i.e., the period when the sequestration will be formed completely) can last from 3 to 12 months, depending on several factors: the state of the immune system, circulatory system, the level of sequestration formation, the type of the tissue that it consists of (spongy, cortical or spongy bone and cortical layer), whether the surgery had been performed in this area before, and the extent of the operation, the term of duration of drug addiction and the last time the patient had taken drugs.
5. If the sequestration zone occupies a small area and is located within the body or the alveolar process of mandible, the risk of the process spreading along the branches to the articular process and then to the base of the skull is smaller than in the case of centre of infection located in the area of the branch or articular

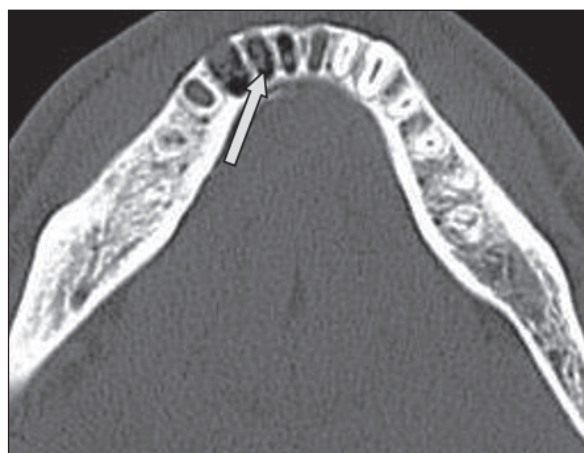

Fig. 9. CT of patient P., DS: chronic osteomyelitis of the mandible (arrow shows focus of destruction of bone tissue without clear demarcation signs).

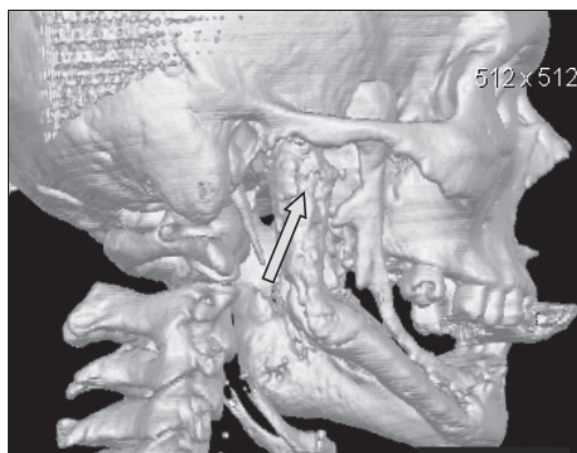


Fig. 10. 3D CT of patient K., DS: chronic osteomyelitis of the mandible (arrow shows affected branches of the mandible with articular process).

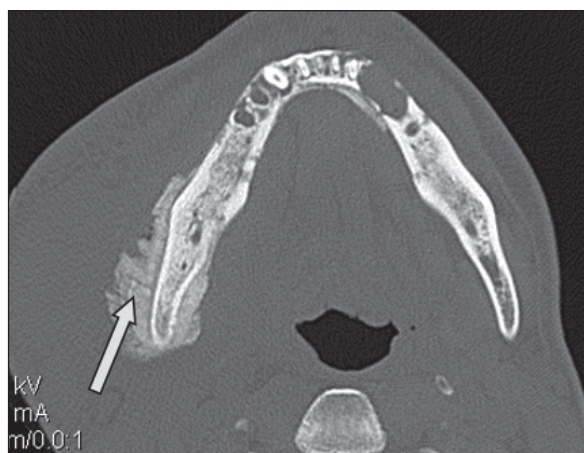

Fig. 11. CT of patient with chronic osteomyelitis of the mandible (arrow shows fimbriated periosteal layers).

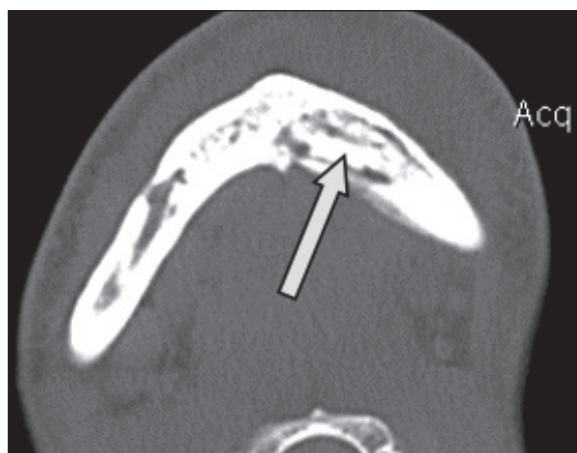

Fig. 12. CT patient R., DS: chronic osteomyelitis of the left half of the mandible (arrow shows area of osteosclerosis and restructuring sequestration, which is not to be removed).

process and the area of formed sequestrum will be smaller than the primary necrotic bone area.

6. In the case of bone affecting the branches of the mandible reaching the zone of the articular process there is a risk of the infection spreading to the bones of the skull basis and the development of septic complications (sepsis, brain abscess, meningitis). That is why in such a situation the surgery should be performed as soon as possible, even though the sequestrum is not yet fully formed (Fig. 10).
7. Some areas of osteonecrosis beyond the sequestrum in the mandible can be reconstructed and form the osteosclerosis areas with clear

demarcation signs according to the radiographic exam. These areas of bone are safe for the patient, although they are closely connected with a vital bone tissue. The need for their removal arises only in the cases of reconstructive operations of the lower jaw (Fig. 12).

8. In the case of multiple exacerbations of inflammatory process, a periosteal regenerate is being formed, that has protective and regenerative functions. However, in most cases it is secondary necrotic (fimbriated form) and causes the relapse in the future. Therefore, it should be removed (Fig. 11).
9. When a partial resection of the affected area

of the lower jaw is performed, there is a risk of relapse because of the lack of a clear demarcation zone.

10. Due to the anatomical features of the upper jaw and circulation, the surgical intervention, unlike within the lower jaw, does not require the tactic of expectation. At any stage of the formation of sequestrum it is necessary to perform the most radical surgery with removal of necrotic tissue.

After the surgical intervention within the upper jaw there usually occurs a wide oro-antral communication with the maxillary cavity, which cannot be closed immediately due to the lack of soft tissue in the area of intervention and a large amount of infected tissues around the operative area (osteonecrotic area that is being reconstructed). These oro-antral communications are being conducted under iodoform swab till the epithelialization of mucosal surface, and their plastic removal is usually performed after 4-8 months if there is no progression of the process on the respective half of the upper jaw.

Discussion

The surgical treatment of osteomyelitis of the mandible remains a difficult problem. This is due to several factors: long-lasting demarcation, diffuse spread of the process to previously undamaged areas of the jaw, significant postoperative defect that causes significant dysfunction (chewing, speech), cosmetic and psychological disorders. As basic types of surgery we use sequestrectomy, sequestrnecrectomy, necrectomy, resection of the jaws (*Saberov, Drobishev, 2011., Morozova et al., 2013*). In most cases the surgery of choice is sequestrectomy, which involves the removal of necrotic bone fragments of the jaw with signs of demarcation including pyogenic and granulation membranes. In this case, the pathological process does not extend beyond the sequestrum capsule (box). Next, the process of bone recovery begins. The surgical treatment of classic types of osteomyelitis of the mandible (odontogenic, post-traumatic, contact) is usually performed in this way.

The surgical treatment of osteomyelitis of the mandible of drug-addicted patients involves

the use of many techniques (sequestrectomy, sequestrnecrectomy, necrectomy, resection of the jaw). The use of more radical methods of surgical treatment involves the removal of a significant amount of dead tissues to reach the vital bone where the circulation is present. Besides the full or partial separation of sequestrum and membranes that surround it, we also remove secondarily infected periosteal layers. The consequences of such surgery do not always provide a stable result or absence of recurrence in the postoperative period. The result of these surgeries is a reduction of chronic intoxication of necrotic bone issue of the jaw, pain symptom and bad breath. In most cases, in the next 6-8 months we perform planned sanitation operations (like sequestrectomy) that lead to the final arrest of the spread of pathological process in the bone of the jaws. Resection of the mandible is performed in cases of a negative result of previous surgery (usually 2-3), or if the process has spread to the branch of the mandible and articular process increasing the risk of septic complications (meningitis, sepsis, brain abscess). The volume of excision of bone tissue is previously determined by CT (computer tomography), but it can vary intraoperatively. After the resection in most cases the spread of the pathological process is arrested. The postoperative defect of the mandibular bone tissue leads to dysfunction of chewing, swallowing, sleep disruption and aesthetic disadvantages (Fig 4, 5). The restoration of the lower jaw is possible after 1.5-2 years after the last surgery.

For surgical treatment of osteomyelitis of the maxilla we use the same techniques as for the lower jaw. The feature of surgical treatment of the osteomyelitis of the upper jaw is fewer recurrences in the postoperative period that requires usually only one surgery to remove the necrotic bone tissue. Additionally, the surgeon performs a radical sinusotomy (symptomatic sinusitis) that leads to a wide oroantral communication. The closing of this defect is not performed simultaneously with the surgery in question. The wound is closed under iodoform swab till the full healing, and 6 months later a plastic closure of oroantral communication may be performed using the local tissues.



Conclusions

1. Our research which examined drug addicted patients with osteomyelitis of the jaws has confirmed that the effectiveness of surgical treatment depends on the size of jaw lesion, the duration of taking addictive substances and withdrawal of the drug use, timely oral cavity sanitation, the history of previous surgeries and concomitant somatic diseases.
2. The surgical treatment of osteomyelitis of the jaws with history of drug addiction depends on the anatomical and topographical conditions, in particular the stage of formation of sequestrum.
3. Our research on cases of patients with osteomyelitis of the jaws with history of drug addiction showed that the lower jaw surgery is a complicated process – if there is no clear demarcation zone, the ramus of the mandible is affected and there are secondary-infected periosteal layers (fimbriated form of periostitis) and areas of osteosclerosis with a clear demarcation, one-time surgery cannot always arrest the further spread of the process, even if the necrotic bone is removed reaching healthy structures.
4. The experience of treatment of osteomyelitis of the jaws in patients with history of drug addiction shows that surgery of the upper jaw is characterized by a possibility of performing early sanitation surgeries without clearly formed demarcation zone, and by the emergence of symptomatic sinusitis with the formation of wide postsurgical oroantral communication.

References

1. Volik AM: “Vint” and its “vintovka”. AIDS J 2000; 4: 8-12.
2. Poghosyan YuM, Hakobyan KA, Poghosyan AYu, Avetisyan EK: Surgical treatment of jaw osteonecrosis in «Krokodil» drug addicted patient. J Craniomaxillofac Surg 2014; 42: 1639-1643. doi: 10.1016/j.jcms.2014.05.005.
3. Malanchuk VA, Kopchak AV, Brodetskiy IS: [Clinical features of osteomyelitis of drug addicted patients]. Ukr med čas 2007; 4: 111-117.
4. Malanchuk VA, Brodetskiy IS, Lipa SV: [Clinical and radiological classification of osteomyelitis of mandible of drug addicted person]. Journal of National Academy of Medical Sciences of Ukraine 2012; 2: 250-258.
5. Poghosyan YuM, Hakobyan KA: Treatment of jaw osteonecrosis in patients who use self-produced drugs. Issues Theor Clin Med 2013; 1: 48-51.
6. Morozova MN, Lupersolsky MU, Boyarintsev S: Experience of surgical treatment of atypical chronic osteomyelitis of the jaws in patients who recovered from drug abuse. J Probl Biol Med 2013; 2: 309-313.

Address: Ukraine, Kiev. National O. Bohomolets Medical University, Shevchenko Boulevard 13.
Tel.: 0632035339
e-mail: i2g3o4@bigmir.net

Received: 19th January 2016

Accepted: 23rd October 2016

