



Received: 2016.08.19
Accepted: 2016.10.06
Published: 2017.06.19

Authors' Contribution:

- A** Study Design
- B** Data Collection
- C** Statistical Analysis
- D** Data Interpretation
- E** Manuscript Preparation
- F** Literature Search
- G** Funds Collection

Endovascular Approach to Glomus Jugulare Tumors

Damian Kocur^{1ABCDEF}, Wojciech Ślusarczyk^{2ABCDEF}, Nikodem Przybytko^{3ABCDE},
Mariusz Hofman^{3BCD}, Tomasz Jamróz^{3BCD}, Krzysztof Suszyński^{4CDE}, Jan Baron^{5ABCDE},
Stanisław Kwiek^{3ABCDE}

¹ Department of Neurosurgery, prof. Gibiński Central Clinical Hospital, Katowice, Poland

² Department of Physiology, Medical University of Silesia, School of Medicine in Katowice, Katowice, Poland

³ Department of Neurosurgery, Medical University of Silesia, School of Medicine in Katowice, Katowice, Poland

⁴ Department of Sports Medicine and Physiology of Physical Effort, Medical University of Silesia, School of Medicine in Katowice, Katowice, Poland

⁵ Department of Radiology and Nuclear Medicine, Medical University of Silesia, School of Medicine in Katowice, Katowice, Poland

Author's address: Damian Kocur, Department of Neurosurgery, prof. Gibiński Central Clinical Hospital, Medyków 14 Str., 40-001 Katowice, Poland, e-mail: damkocur@gmail.com

Summary

Background:

Parangliomas are benign neuroendocrine tumors derived from the glomus cells of the vegetative nervous system. Typically, they are located in the region of the jugular bulb and middle ear. The optimal management is controversial and can include surgical excision, stereotactic radiosurgery and embolization.

Case Report:

We report the endovascular approach to three patients harboring glomus jugulare paragangliomas. In all cases incomplete occlusion of the lesions was achieved and recanalization in the follow-up period was revealed. Two patients presented no clinical improvement and the remaining one experienced a transient withdrawal of tinnitus.

Conclusions:

It is technically difficult to achieve complete obliteration of glomus jugulare tumors with the use of embolization and the subtotal occlusion poses a high risk of revascularization and is not beneficial in terms of alleviating clinical symptoms.

MeSH Keywords:

Embolization, Therapeutic • Glomus Jugulare • Glomus Jugulare Tumor • Paranglioma

PDF file:

<http://www.polradiol.com/abstract/index/idArt/901141>

Background

Glomus tumors, also known as paragangliomas or chemodectomas, are benign neuroendocrine tumors derived from the glomus cells of the vegetative nervous system [1,2]. They can be found in a wide range of locations in the human body [3]. One of the most typical location is the temporal bone in the region of the jugular bulb and middle ear. These types of paragangliomas are termed glomus jugular or jugulotympanic tumors (GJTs) and are the most common tumors that develop in the jugular foramen [4]. Glomus tumors are rare, with an incidence of about 1 per 1 million and a marked predisposition in women [1,3,5]. The majority of these tumors are slow-growing with a clinical manifestation in the sixth to seventh decade of life [1,3]. The typical expansive and locally destructive growth pattern of glomus

jugulare tumors leads to cranial nerve damage with related symptoms (facial palsy, pulsatile tinnitus, hearing loss, difficulty in swallowing and loss of voice) and in larger tumors brainstem compression can be seen [1–3,5]. Despite the fact that these tumors are an urgent and life-threatening condition, only in exceptional situations do they have a negative impact on the quality of life in the mid- or long-term [3]. While clinical signs are essential as an initial clue to a mass located in the temporojugular area, a clinical diagnosis of GJTs based on imaging studies may be established with a high probability [3,6]. Computed tomography (CT), magnetic resonance (MR), time of flight magnetic resonance angiography (TOF MR) and digital subtraction angiography (DSA) are commonly applied. These infiltrative tumors follow the path of least resistance, and in CT scans expansion and erosion of the temporal bone is depicted with a characteristic

“moth-eaten” pattern of destruction [4]. The main MR characteristics of glomus tumors include a low signal intensity on T1, a high signal intensity on T2-weighted images and multiple areas of intralésional high and low signal intensity (“salt and pepper appearance”) representing high and slow flow [6]. The spaces of high flow are depicted as areas of high signal intensity on TOF MR [6]. In both CT and MR studies, vivid and homogeneous contrast enhancement is observed [6]. Angiography is a gold standard for diagnosing glomus tumors, but it is performed only when noninvasive imaging studies are confusing [6,7]. On angiograms, the ascending pharyngeal artery – called “the artery of the paraganglioma”, occipital artery, posterior auricular artery and stylomastoid artery are presented as fundamental tumor-feeding vessels [3,4,6]. Moreover, an enlargement of these arteries, an intense blushing of the tumor and a rapid venous drainage should be shown [6]. As far as treatment of glomus jugulare tumors is concerned, optimal management is still controversial and a few possibilities exist [1,3,6,7]. The aim of the available therapeutic options is to improve a local control of the tumor with minimizing the resultant morbidity [7]. The focus of the current study was to share our experience in the endovascular approach to jugular paragangliomas with special regard to angiographic and clinical outcomes.

Case Report

Case 1

A 47-year-old woman complained of aggravating right-sided hearing deficits, tinnitus, vertigo and imbalance for 2 years. Neurological examination did not reveal any neurological deficits besides right hypoacusia. Magnetic resonance imaging (MRI) depicted right-sided jugulo-tympanic glomus tumor with a maximal size of 1.6 cm. Selective angiograms of the right external carotid artery (ECA) and superficial temporal arteries (STAs) showed a hypervascular mass with an intense tumor blush and early draining veins (Figure 1A). After determining an appropriate position of the microcatheter tip, endovascular occlusion of the paraganglioma vessels was performed under fluoroscopic guidance with micromolecules of polyvinyl alcohol (PVA) (Boston Scientific/Target Therapeutics, Cork Ltd., Cork, Ireland, Cordis J&J Endovascular, Miami, FL, USA) (100 μm) (Figure 1B). As it was impossible to reach smaller arterial feeders to achieve more distal embolization, the occlusion of the lesion was subtotal, which was confirmed by an immediate post-embolization angiogram (Figure 1C). The post-embolization course was unremarkable and the tinnitus entirely withdrew after the procedure. A follow-up angiogram performed 6 months later depicted a minor tumor blush with vascular supply from the occipital artery. Subsequent angiography was performed 20 months after the treatment and revealed significant tumor revascularization (Figure 1D). One year after embolization, the clinical symptoms recurred completely. The patient was referred for stereotactic radiotherapy.

Case 2

A 66-year-old woman presented with a left-sided jugulo-tympanic paraganglioma with a maximal size of 27 mm

(Figure 2). Over 3 years, she had been complaining of progressive left-sided peripheral paresis of the facial nerve, reaching the 5th degree on the House-Brackmann scale, and left-sided hearing deficits. After selective angiography, a partial tumor embolization through 3 feeding arteries was performed with the use of acrylic glue, “Glubran 2” (GEM Srl, Viareggio, Italy) and contrast agent “Lipiodol” (Glubran 2: Lipiodol 1: 1). Further complete embolization was not feasible because of technically challenging catheterization of the small vessels supplying the lesion. The clinical status did not improve. A follow-up angiogram taken one month later showed revascularization of the lesion (Figure 2). The patient did not agree to further treatment.

Case 3

A 45-year-old man was diagnosed with a left jugulo-tympanic paraganglioma. In addition, he had been treated for multiple sclerosis for several years. Over 10 years, the patient had been complaining of left-sided hearing deficits progressing gradually to deafness. Additional neurological symptoms included spasticity of upper and lower limbs, increased deep tendon reflexes, monoparesis of the right lower limb (3rd degree), hypoesthesia (pain, temperature) of the left upper and left lower limbs. Following DSA, a two-staged partial embolization was performed via branches of the ECA with the application of micromolecules of PVA (150–255 μm) and PVA 100. (Figure 3A, 3B). A follow-up DSA performed 13 months later revealed an enlargement of the previously revealed tangle of vessels (Figure 3C). The third stage of embolization with micromolecules of PVA (300 μm) performed via 4 feeding branches also resulted in a subtotal occlusion. The navigation through the smallest arterial feeders was not feasible which resulted in only partial obliteration of the vascular channels of the paraganglioma. The clinical status did not improve. The patient was referred for stereotactic radiotherapy.

Discussion

An optimal management of paragangliomas has not been unequivocally established and the available armamentarium includes surgery, stereotactic radiosurgery and endovascular therapy [1,3]. In addition, observation of the clinical status of patients and radiological tumor follow-up is also an option [1]. Although the natural course of GJTs has not been ultimately recognized, these tumors are likely to grow with a reported tumor doubling time longer than 4.2 years [1,6]. If there is no evolution of clinical symptoms, patients should be followed up with MR imaging up to every two years [6]. Conservative treatment of paragangliomas, however, remains controversial as early surgical resection of smaller lesions is associated with a decreased morbidity and a higher likelihood of radical resection [6]. Moreover, an observational strategy may be inappropriate in young patients with a long life expectancy [8]. Surgical tumor excision results in a 90% control rate of resected lesions, and since tumor shrinkage is not guaranteed following radiotherapy, surgery may be inevitable in case of tumor mass effect and related intracranial hypertension, hydrocephalus or brainstem compression [1,3]. However, neurological consequences of surgical resections are significant and mainly include persistent cranial nerve deficits;

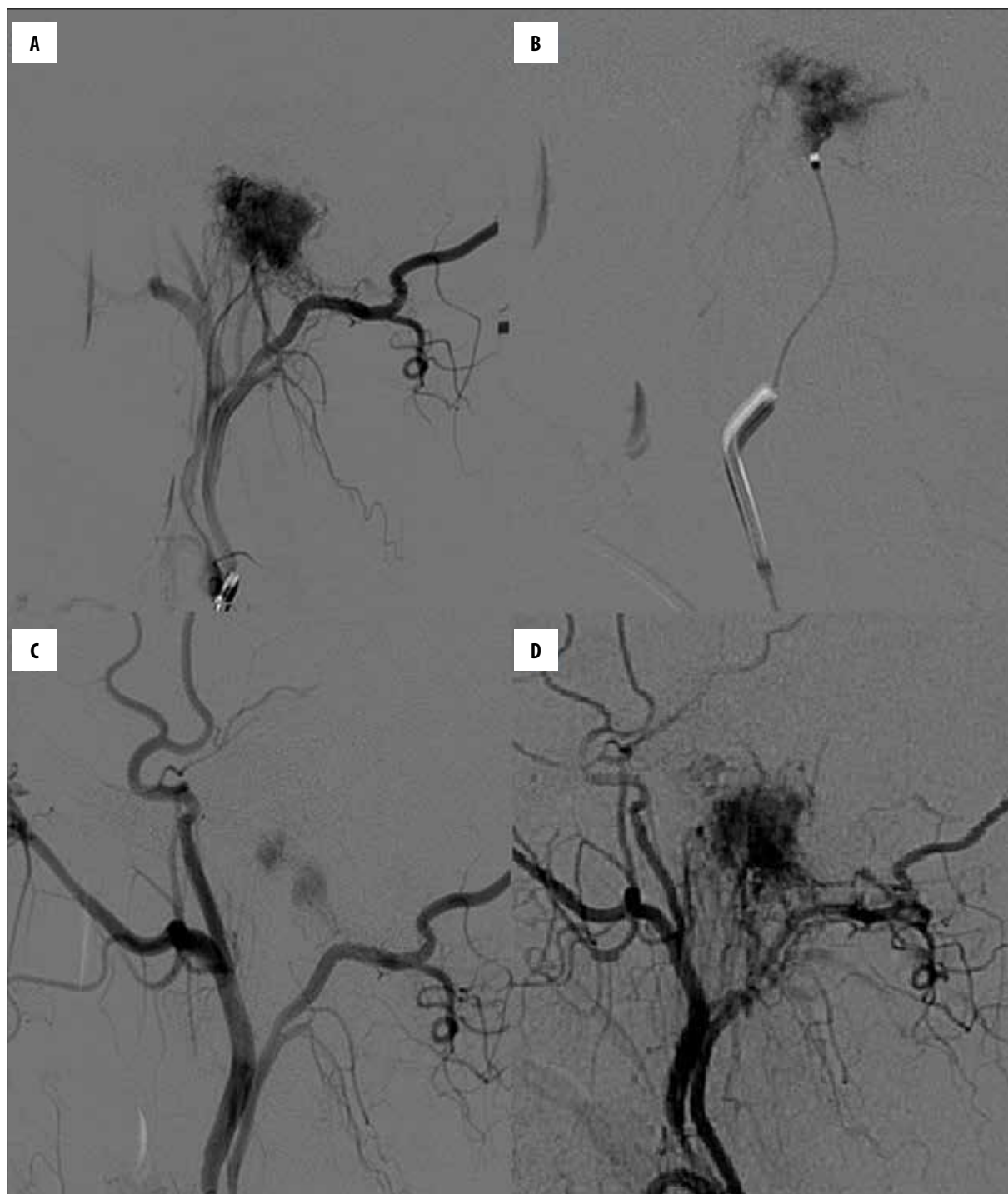


Figure 1. External carotid injection (A) and fluoroscopic working projections (B) show the tumoral blush. On the digital subtraction angiography performed directly after embolization (C) a residual contrast inflow is seen. A control angiogram taken 20 months later revealed significant tumor revascularization (D).

this relates especially to jugular or jugulotympanic paragangliomas [2,3,8]. Even in experienced centers, the results are not satisfactory and the overall mortality rate ranges from 1.2% to 6.4% [3].

Stereotactic radiosurgery may be applied as the treatment of choice [2,3,6,9]. In paragangliomas, this method results in lower morbidity than surgery with a possibility of clinical

improvement [3]. It provides a good long-term tumor control, with 61% of the tumors stable in size [3]. Recent studies have shown a long-term neurological improvement in 42% of patients and aggravation of clinical symptoms in 4% of patients treated with stereotactic radiosurgery [9–11].

As far as endovascular therapy is concerned, it is confined to preparation for surgery and palliative applications, but it

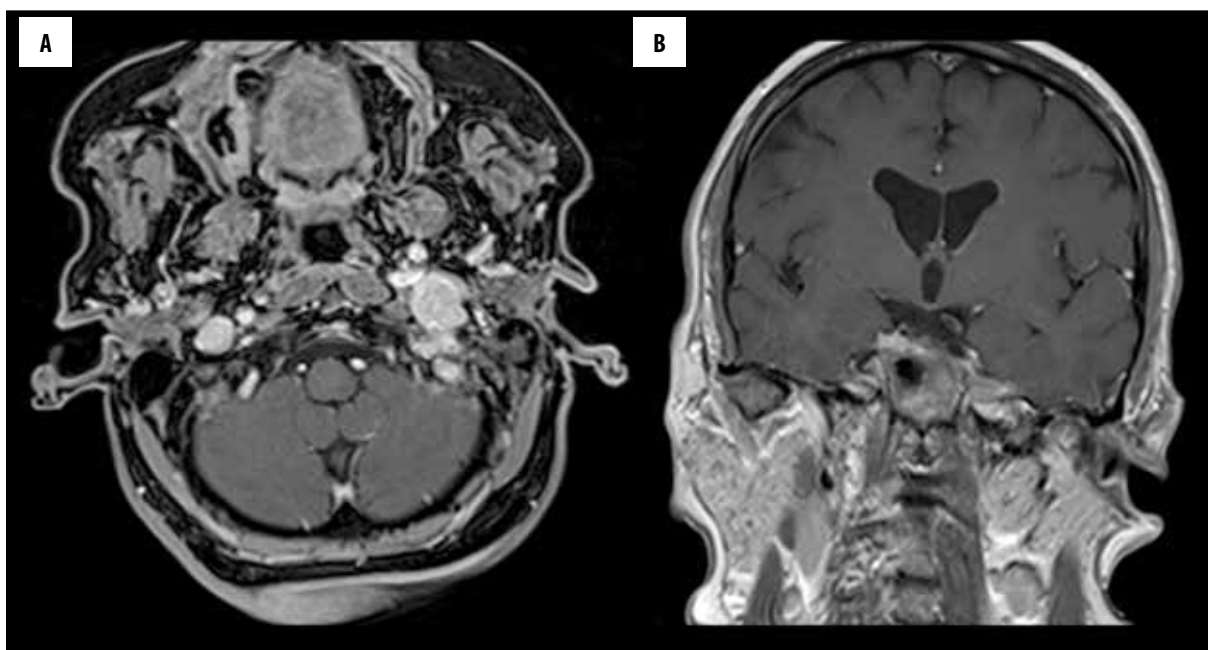


Figure 2. Axial (A) and coronal (B) T1+C magnetic resonance imaging sequences demonstrate a left-sided, homogeneously enhancing glomus jugulare tumor with a maximal diameter of 2.7 cm.

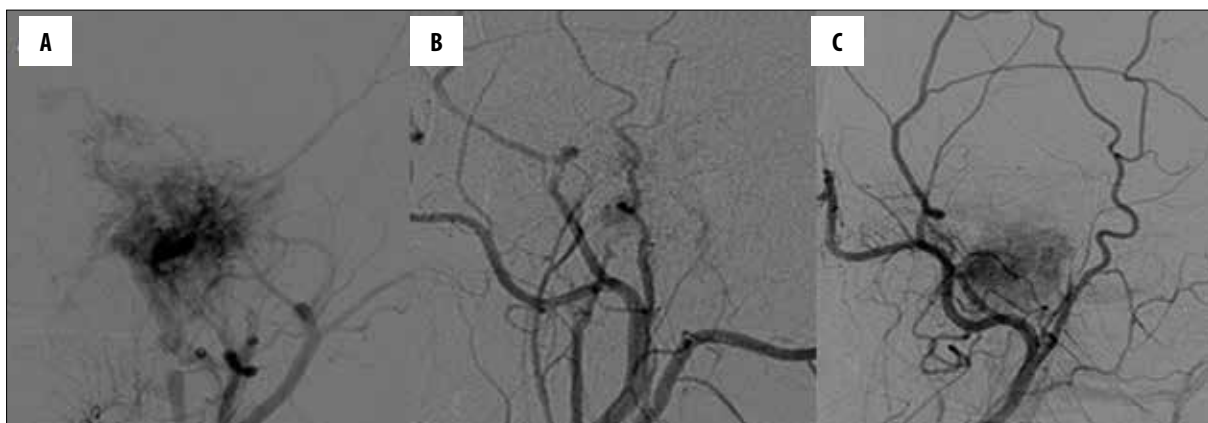

Figure 3. Left external carotid injection (A) presents a jugulo-tympanic paraganglioma tumoral blush. Two-staged embolization was performed with a subtotal effect of vascular occlusion (B). A control angiogram taken 13 months later revealed significant tumor revascularization (C).

is not curative [3,6,12]. As regards preoperative embolization through feeding vessels, its role is to decrease blood loss during surgical procedures and to help perform resections in a more secure manner [12–15]. In case of head and neck paragangliomas, both transarterial embolization with polyvinyl alcohol (PVA) particles and direct percutaneous embolization with n-butyl cyanoacrylate (NBCA) or ethylene vinyl alcohol polymer (Onyx) are used [16]. Either way, the procedure of presurgical adjuvant endovascular embolization is safe and effective, and the application of this form of therapy followed by surgical excision of paragangliomas is widely accepted [3,8,17]. In the literature, symptomatic treatment of paragangliomas is reported to be an alternative [3,6]. Paragangliomas are well-vascularized tumors and as a palliative treatment endovascular occlusion of tumor arterial supply is reported to have a positive impact on clinical symptoms including vertigo and tinnitus [3,13,17]. However, because of the multitude of arterial feeders and

pedicles originating from eloquent branches, a total embolization is difficult to achieve [18], which is confirmed by the current study. Although according to the available reports the therapeutic role of endovascular procedures in the palliative treatment of glomus jugulare tumors may demonstrate a certain clinical effectiveness and radiological stabilization [8,19,20], embolization as a sole treatment for paragangliomas is not advised [2,3,13]. The data published so far are sparse, with various embolic agents, including autologous muscle, Spongostan, PVA particles, coils and glue [18]. Our results are likely to indicate that a complete embolization of GJTs through the transarterial route is technically challenging and a subtotal embolotherapy has a limited impact on clinical symptoms. Moreover, an endovascular occlusion of tumor-feeding vessels is characterized by a high degree of recurrence. One of the reasons may be the application of older intravascular embolization agents such as PVE and acrylic glue. The recent data

concerning a new embolic agent Onyx are promising [18]. Michelozzi et al. reported a series of 10 patients with jugular/jugulotympanic paragangliomas who underwent Onyx embolization alone, and 7 tumors were stable in size during a mean follow-up of 45.7 months [8]. As far as the stabilization of a tumor size is concerned, it seems questionable if there is an advantage of such management over no treatment. Nonetheless, the regression of preoperative clinical symptoms was achieved in eight cases of the above-mentioned ten patients, and there were two recurrences [8]. It should be mentioned, however, that the authors presented patients with cranial nerve deficits that appeared following endovascular treatment of jugulo-tympanic paragangliomas [8]. This shows that endovascular intervention in

jugular/tympanojugular paragangliomas carries a certain risk of complications such as cerebellar/brainstem infarction resulting from embolic material embolism and cranial nerve palsies, as a consequence of tumor swelling and nerve compression or embolic ischemia of the vasa nervorum [3,8].

Conclusions

Endovascular treatment of glomus jugulare tumors is associated with technical difficulties in achieving complete occlusion of the lesions. Subtotal embolization is characterized by a high degree of revascularization and appears not to be beneficial in terms of alleviating clinical symptoms.

References:

- Chen PG, Nguyen JH, Payne SC et al: Treatment of glomus jugulare tumors with gamma knife radiosurgery. *Laryngoscope*, 2010; 120: 1856-62
- Geç A, Bicer A, Abacıoğlu U et al: Gamma knife radiosurgery for the treatment of glomus jugulare tumors. *J Neurooncol*, 2010; 97: 101-8
- Winn HR, Youmans JR (eds.): *Youmans neurological surgery*. 5th ed. Philadelphia, Saunders, 2004
- Vogl T, Bisdas S: Differential diagnosis of jugular foramen lesions. *Skull Base*, 2009; 19: 3-16
- Greenberg MS, Greenberg MS (eds.): *Handbook of neurosurgery*. 7th ed. Tampa, FL, Greenberg Graphics, 2010
- van den Berg R: Imaging and management of head and neck paragangliomas. *Eur Radiol*, 2005; 15: 1310-18
- Semaan MT, Megerian CA: Current assessment and management of glomus tumors. *Curr Opin Otolaryngol Head Neck Surg*, 2008; 16: 420-26
- Michelozzi C, Januel AC, Cuvinciuc V et al: Arterial embolization with ONYX of head and neck paragangliomas. *J NeuroInterventional Surg*, 2016; 8: 626-35
- Liscak R, Urgosik D, Chytka T et al: Leksell Gamma Knife radiosurgery of the jugulotympanic glomus tumor: Long-term results. *J Neurosurg*, 2014; 121(Suppl.): 198-202
- Gandía-González ML, Kusak ME, Moreno NM et al: Jugulotympanic paragangliomas treated with Gamma Knife radiosurgery: a single-center review of 58 cases. *J Neurosurg*, 2014; 121: 1158-65
- Lee C-C, Pan DH-C, Wu J-C et al: Gamma knife radiosurgery for glomus jugulare and tympanicum. *Stereotact Funct Neurosurg*, 2011; 89: 291-98
- Murphy TP, Brackmann DE: Effects of preoperative embolization on glomus jugulare tumors. *Laryngoscope*, 1989; 99: 1244-47
- Tasar M, Yetiser S: Glomus tumors: Therapeutic role of selective embolization. *J Craniofac Surg*, 2004; 15: 497-505
- Harati A, Deitmer T, Rohde S et al: Microsurgical treatment of large and giant tympanojugular paragangliomas. *Surg Neurol Int*, 2014; 5: 179
- Gaynor BG, Elhammady MS, Jethanamest D et al: Incidence of cranial nerve palsy after preoperative embolization of glomus jugulare tumors using Onyx. *J Neurosurg*, 2014; 120: 377-81
- Ozyer U, Harman A, Yildirim E et al: Devascularization of head and neck paragangliomas by direct percutaneous embolization. *Cardiovasc Intervent Radiol*, 2010; 33: 967-75
- White JB, Link MJ, Cloft HJ: Endovascular embolization of paragangliomas: A safe adjuvant to treatment. *J Vasc Interv Neurol*, 2008; 1: 37-41
- Dalfino JC, Drazin D, Nair A et al: Successful onyx embolization of a giant glomus jugulare: Case report and review of nonsurgical treatment options. *World Neurosurg*, 2014; 81: 842.e11-e16
- Harris S, Brismar J, Cronqvist S: Pulsatile tinnitus and therapeutic embolization. *Acta Otolaryngol (Stockh)*, 1979; 88: 220-26
- Merland JJ, Tempier P, Rancurel G et al: [Attempted treatment of a voluminous tympano-jugular and retropharyngeal glomus tumor by embolization]. *Rev Neurol (Paris)*, 1977; 133: 621-26 [in French]