



Received: 2016.08.17
Accepted: 2016.09.08
Published: 2017.06.10

Authors' Contribution:

- A** Study Design
- B** Data Collection
- C** Statistical Analysis
- D** Data Interpretation
- E** Manuscript Preparation
- F** Literature Search
- G** Funds Collection

Stent-Assisted Coil Embolization of Posttraumatic Dissecting Carotid Aneurysm Causing Ophthalmoplegia

Kaan Esen^{1AE}, Huseyin Naim Eriş^{2AE}, Altan Yildiz^{1AE}, Engin Kara^{1E}, Anil Ozgur^{1E}

¹ Department of Radiology, Mersin University, School of Medicine, Mersin, Turkey

² Department of Radiology, Tarsus Medical Park Hospital, Mersin, Turkey

Author's address: Kaan Esen, Department of Radiology, Mersin University, School of Medicine, 33343 Mersin, Turkey, e-mail: kaanessen@yahoo.com

Background:	Ophthalmoplegia secondary to a traumatic dissecting aneurysm in the cavernous segment of internal carotid artery (ICA) is a relatively rare entity. Anticoagulant or antiplatelet therapy is the preferred treatment option for carotid dissections. However, endovascular interventions are noninvasive and alternative methods to surgery, especially in cases of aneurysms that do not respond to medical therapy.
Case Report:	We report of a 19-year-old man presenting with left-sided, total ophthalmoplegia after a traffic accident. Magnetic resonance imaging (MRI) and digital subtraction angiography (DSA) revealed a dissection beginning at the cervical segment of internal carotid artery (ICA) together with a dissecting aneurysm in the cavernous segment. A stent was placed in the narrowed and dissected segment of ICA, and the dissecting aneurysm of the cavernous segment was successfully managed with a stent-assisted coil embolization. After the endovascular treatment of the aneurysm, a full recovery of cranial nerve function was achieved.
Conclusions:	Immediate diagnosis and appropriate therapy of dissecting aneurysms is necessary for good clinical outcomes in cases of ophthalmoplegia.
MeSH Keywords:	Aneurysm, Dissecting • Carotid Artery, Internal • Ophthalmoplegia
PDF file:	http://www.polradiol.com/abstract/index/idArt/901096

Background

Ophthalmoplegia secondary to intracranial aneurysms is a well-described clinical condition. However, a traumatic, dissecting carotid aneurysm in the cavernous segment causing ophthalmoplegia is a relatively rare entity. Different mechanisms have been described for the development of nerve paresis secondary to an aneurysm. Cranial nerve paresis might occur due to a compression of the nerve by the aneurysmal sac or due to the irritant effect of subarachnoid blood after aneurysmal rupture [1,2]. The junction of the ICA and the posterior communicating arteries, cavernous segment/bifurcation of ICA and the basilar tip are the most common locations of aneurysms causing oculomotor nerve paresis [3]. Herein, we report of a rare case of ophthalmoplegia secondary to a traumatic, dissecting aneurysm in the cavernous segment of ICA, which was treated with endovascular interventions.

Case Report

A 19-year-old man was transported to an emergency department after a traffic accident. He was unconscious and unresponsive to painful stimulation. There was no spontaneous respiration and the left pupil was dilated. Following cardiopulmonary resuscitation and intubation, the patient was monitored in an intensive care unit. Cranial computed tomography (CT), which was performed at his first admission, did not reveal any intracranial pathology such as subarachnoid hemorrhage (SAH), infarction or aneurysm. Thoracoabdominal CT was also normal. One week later, a drooping eyelid with limited extraocular movements developed in the left eye of the patient. A diagnosis of total ophthalmoplegia was made, characterized by a complete limitation of all extraocular movements and ptosis. On cranial MRI and MR angiography, an aneurysm (15 mm in diameter) of the cavernosal segment of the left ICA was detected (Figures 1, 2). DSA revealed a focal and

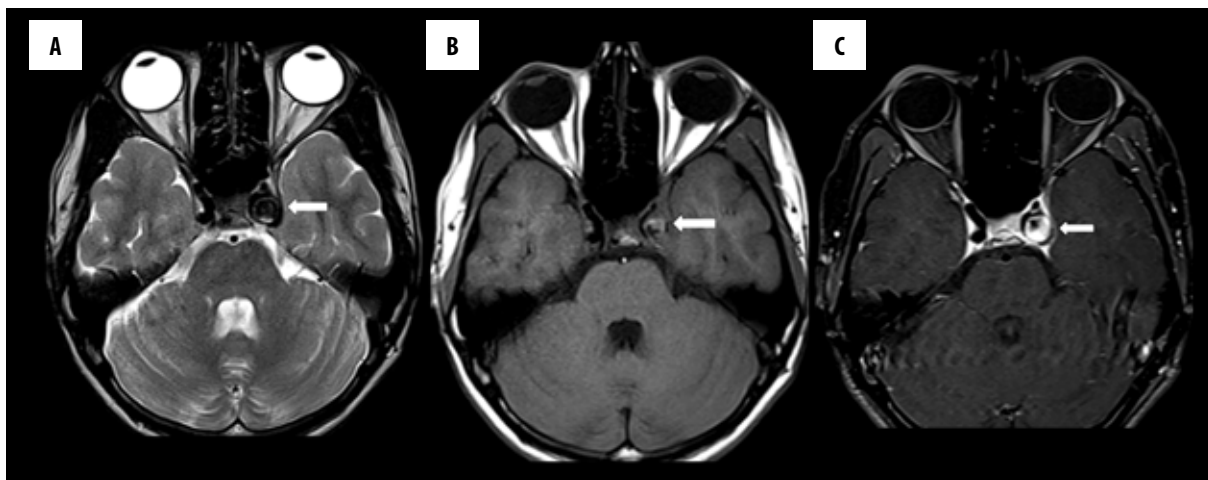


Figure 1. Axial T2-weighted (A), T1-weighted (B), T1-weighted post-contrast fat saturation (C) MR images show an aneurysm in the left ICA cavernous segment (arrows). Note that the lumen of the aneurysm is hyperintense on T1-weighted images and is filling with contrast on post-contrast images.

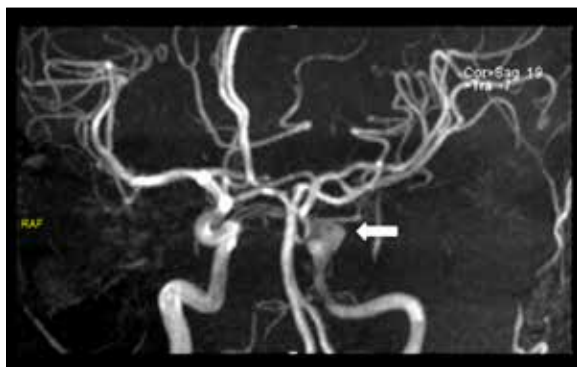


Figure 2. MR angiography reveals the dissecting aneurysm (arrow). Note that the left ICA shows diffuse luminal narrowing in comparison to the right ICA.

serious narrowing in the cervical segment of left ICA with an irregular vessel wall secondary to dissection. A dissecting aneurysm extending into the cavernous sinus was also detected in the cavernosal segment of ICA (Figure 3). The calibration of distal segments was normal.

Based on DSA, an endovascular treatment of the aneurysm was planned. Loading doses of both clopidogrel (450 mg) and aspirin (300 mg) were given orally before the treatment which was performed under general anesthesia. Initially, a 6F guiding sheath was placed into the left common carotid artery. At the beginning of the treatment, a heparin bolus of 5000 IU was delivered intravenously. A 6F guiding catheter was placed coaxially within the cervical segment of left ICA and subsequently a microcatheter was delivered into the aneurysmal sac. A 5×20mm, intracranial neurovascular Solitaire AB stent (Covidien, Irvine, CA, USA) was deployed to cover the aneurysmal neck, after which embolization of the aneurysm was performed through a jailed microcatheter using 10 different featured and sized detachable coils. A 7×40 mm carotid Wallstent (Boston Scientific, Natick, MA, USA) was also delivered into the dissected and narrowed segment of the cervical carotid artery. Dual antiplatelet therapy with daily doses of aspirin (100 mg) and clopidogrel (75 mg) was initiated and continued thereafter. An improvement in

the third nerve paresis was detected 5 days after the embolization. An angiogram, taken after one month, demonstrated a remnant in the aneurysmal neck with an improved luminal patency of the carotid artery. Because of the neck remnant, a second session of endovascular therapy was performed 6 weeks after the first intervention, in which 16 different types of detachable coils were used. After that treatment, all ocular symptoms of the patient disappeared. Follow-up angiograms revealed a near-complete occlusion of the aneurysm and normal distal branches (Figure 4).

Discussion

Dissection is described as a hemorrhage into the medial layer of arterial wall through an intimal tear, which results in narrowing or occlusion of the lumen [4–7]. Carotid artery dissection is an important cause of stroke in young patients and may be spontaneous, traumatic or iatrogenic [4,5,8,9]. As regards appropriate management, traumatic carotid dissection is a different clinical condition compared to spontaneous carotid dissections [10]. Dissection of the extracranial segments of the carotid artery secondary to trauma is more common in comparison to intracranial segments and therefore most of the published studies report of extracranial carotid injury [7,11].

Dissections may cause stenosis, occlusion or manifest as a dissecting aneurysm [6,7]. High-grade stenoses and occlusions are likely to cause ischemic symptoms; however, dissections without luminal narrowing might be asymptomatic or give rise to local signs and symptoms such as headache, Horner syndrome, pulsatile tinnitus and cranial nerve palsy [7]. When the dissection involves the subadventitia, a dissecting aneurysm arises [6]. The major manifestations of a dissecting aneurysm are hemorrhage and ischemia [12]. The cavernosal segment of ICA has a close relationship with the oculomotor nerve, trochlear nerve, trigeminal nerve (ophthalmic and maxillary divisions) and abducens nerve in the cavernous sinus. In addition to a compressive effect of the aneurysm, dissection might affect meningohypophyseal and inferolateral branches of ICA originating from the cavernous segment. The branches

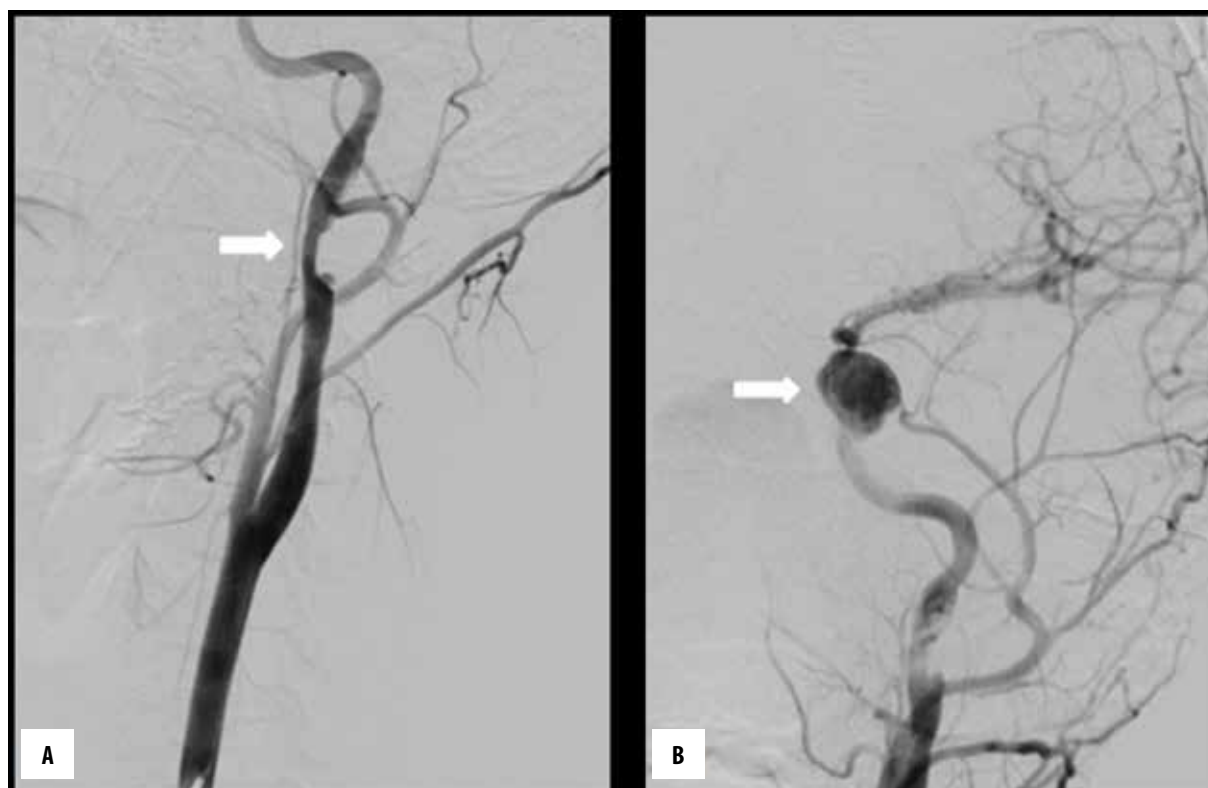

Figure 3. Diagnostic DSA of the left ICA shows focal luminal stenosis (arrow) secondary to dissection at the cervical segment (A) and an aneurysm (arrow) in the cavernous segment (B).

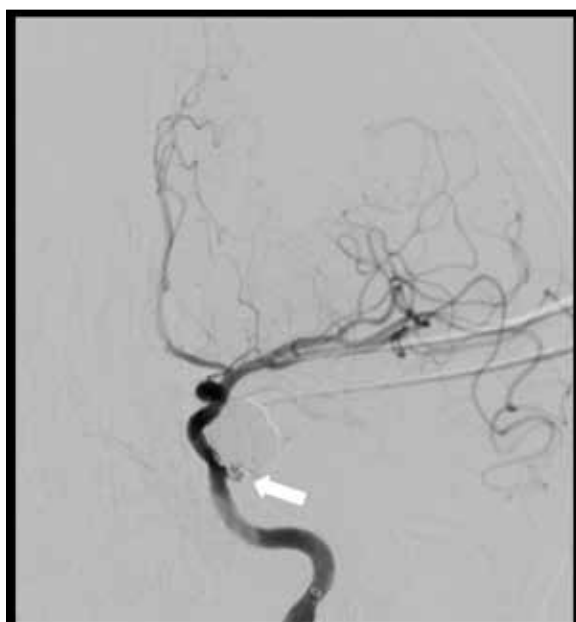


Figure 4. After the second embolization, a near-complete occlusion of the aneurysm with a minimal neck remnant was achieved (arrow).

of the meningohypophyseal trunk supply the oculomotor, trochlear and abducens nerves; hence, ICA dissection might cause ocular cranial nerve paresis [9].

In the diagnosis of dissections and aneurysms, DSA is still accepted as the gold standard; however, MRI can

demonstrate intramural hematomas and arterial wall with different sequences. Intramural hematoma is observed as a high-signal, crescent-shaped lesion surrounding flow-void lumen on T1-weighted MRI sequences obtained with fat saturation, which is a characteristic sign of dissection [7]. Subacute hematomas are visualized better than acute hematomas due to the paramagnetic effects [7]. MR angiography and CT angiography are also useful in the diagnosis of dissections and aneurysms.

Anticoagulant or antiplatelet therapy is the most accepted initial treatment for carotid dissections, especially for the extracranial segments [7]. Rao et al. reported that most cervical carotid dissections can be safely managed by a conservative approach [5]. Lucas et al. suggested anticoagulation treatment at the early stage of dissections, because infarcts occurring in the carotid artery dissections are generally secondary to embolism [13]. The treatment of intracranial carotid artery is controversial. The use of anticoagulants in the intracranial carotid dissections might be hazardous due to the high risk of hemorrhage [7]. There is not enough data to decide whether routine endovascular treatment is superior to medical therapy [5]. Kadkhodayan et al. demonstrated the effect of angioplasty and stent placement in relieving stenosis secondary to dissection, with low rates of ischemic complications [4].

The management of patients with either a dissection or an aneurysm has been described in the literature and the treatment options include anticoagulant therapy, surgery or endovascular interventions. Although the reports on the prognosis and treatment in patients with both of these two

entities and ophthalmoplegia after trauma are not frequent, it has been reported that aneurysms associated with cervical ICA dissections frequently persist [14]. Anticoagulant therapy is effective in preventing ischemic complications; however, it cannot reduce cranial nerve compression caused by the aneurysm. Therefore, a prompt intervention may be needed. Surgical treatment decreases the mass effect caused by the aneurysm and provides decompression of the nerves [3]. Endovascular interventions are less invasive than surgery and are indicated in cases with persistent symptoms despite antithrombotics, to expand dissecting aneurysms and improve compromised cerebral circulation [15]. Santillan et al. showed endovascular coiling to be as effective as surgical clipping for treating the third nerve palsy secondary to small posterior communicating artery aneurysms [16]. Panagiotopoulos et al. reported a complete (50%) and incomplete (40%) recovery in aneurysms treated with endosaccular coiling [3]. The authors also demonstrated that the degree of initial cranial nerve palsy (i.e. complete or partial) was the only parameter that affected the recovery degree of nerve function after endovascular treatment [3]. In another study, Hanse et al. also reported that a complete recovery is more likely with initial partial dysfunction of the nerve [17].

The reported patient was treated for the dissecting aneurysm with stent-assisted coil embolization and for the dissection of cervical ICA with stenting. The risk of aneurysmal hemorrhage and development of oculomotor nerve palsy were the main reasons for preferring the endovascular treatment. Following the treatment, the patient had a complete recovery of cranial nerve function without any significant stenosis. The aneurysm was embolized with a near-complete occlusion and a minimal neck remnant after two interventions performed within 6 weeks.

Conclusions

In conclusion, dissections/dissecting aneurysms that may give rise to total ophthalmoplegia should always be kept in mind after trauma to the head and neck. Appropriate treatment may be planned based on clinical and radiological findings. However, cranial nerve palsy may require a prompt intervention.

Conflict of interest

The authors declare that they have no conflict of interest.

References:

- Giombini S, Farraresi S, Plunchino F: Reversal of oculomotor disorders after intracranial aneurysm surgery. *Acta Neurochir*, 1991; 112: 19–24
- Hyland HH, Barnett HJ: The pathogenesis of cranial nerve palsies associated with intracranial aneurysms. *Proc R Soc*, 1954; 47: 141–46
- Panagiotopoulos V, Ladd SC, Gizewski E et al: Recovery of ophthalmoplegia after endovascular treatment of intracranial aneurysms. *Am J Neuroradiol*, 2011; 32: 276–82
- Kadhodayan Y, Jeck DT, Moran CJ et al: Angioplasty and stenting in carotid dissection with or without associated pseudoaneurysm. *Am J Neuroradiol*, 2005; 26: 2328–35
- Rao AS, Makaroun MS, Marone LK et al: Long-term outcomes of internal carotid artery dissection. *J Vasc Surg*, 2011; 54: 370–74
- Lee DH, Hur SH, Kim HG et al: Treatment of internal carotid artery dissections with endovascular stent placement: Report of two cases. *Korean J Radiol*, 2001; 2: 52–56
- Rodallec MH, Marteau V, Gerber S et al: Craniocervical arterial dissection: Spectrum of imaging findings and differential diagnosis. *Radiographics*, 2008; 28: 1711–28
- Bogousslavsky J, Regli F: Ischemic stroke in adults younger than 30 years of age. Cause and prognosis. *Arch Neurol*, 1987; 44: 479–82
- Andrade GC, Alves HFP, Parente Júnior R et al: Cavernous carotid traumatic dissecting aneurysm and subarachnoid hemorrhage after orthognathic surgery treated with arterial embolization. *J Bras Neurocirurg*, 2012; 23: 246–50
- Galyfos G, Filis K, Sigala F, Sianou A: Traumatic carotid artery dissection: A different entity without specific guidelines. *Vasc Spec Int*, 2016; 32: 1–5
- Seth R, Obuchowski AM, Zoarski GH: Endovascular repair of traumatic cervical internal carotid artery injuries: A safe and effective treatment option. *Am J Neuroradiol*, 2013; 34: 1219–26
- Oyama H, Kito A, Maki H et al: Treatment of a cerebral dissecting aneurysm in anterior circulation: report of 11 subarachnoid hemorrhage cases. *Nagoya J Med Sci*, 2012; 74: 325–38
- Lucas C, Moulin T, Deplanque D et al: Stroke patterns of internal carotid artery dissection in 40 patients. *Stroke*, 1998; 29: 2646–48
- Touzé E, Randoux B, Méary E et al: Aneurysmal forms of cervical artery dissection associated factors and outcome. *Stroke*, 2001; 32: 418–23
- Mohan IV: Current optimal assessment and management of carotid and vertebral spontaneous and traumatic dissection. *Angiology*, 2014; 65: 274–83
- Santillan A, Zink WE, Knopman J et al: Early endovascular management of oculomotor nerve palsy associated with posterior communicating artery aneurysms. *Interv Neuroradiol*, 2010; 16: 17–21
- Hanse MC, Gerrits MC, van Rooij WJ et al: Recovery of posterior communicating artery aneurysm-induced oculomotor palsy after coiling. *Am J Neuroradiol*, 2008; 29: 988–90