



Received: 2016.05.18  
Accepted: 2016.07.25  
Published: 2017.03.19

**Authors' Contribution:**

- A** Study Design
- B** Data Collection
- C** Statistical Analysis
- D** Data Interpretation
- E** Manuscript Preparation
- F** Literature Search
- G** Funds Collection

## A Systematic Review and Meta-Analysis of C-Arm Cone-Beam CT-Guided Percutaneous Transthoracic Needle Biopsy of Lung Nodules

Gao-Wu Yan<sup>1AB\*</sup>, Anup Bhetuwal<sup>1AB\*</sup>, Gao-Wen Yan<sup>2AB\*</sup>, Qin-Quan Sun<sup>1BF</sup>,  
Xiang-Ke Niu<sup>3BF</sup>, Yu Zhou<sup>4BF</sup>, Li-Fa Li<sup>5BF</sup>, Bin-Zhong Li<sup>6D</sup>, Hao Zeng<sup>7BF</sup>, Chuan Zhang<sup>1BF</sup>,  
Bing Li<sup>1D</sup>, Xiao-Xue Xu<sup>1D</sup>, Han-Feng Yang<sup>1AB</sup>, Yong Du<sup>1D</sup>

\* These authors contributed equally to this study

<sup>1</sup> Sichuan Key Laboratory of Medical Imaging and Department of Radiology, Affiliated Hospital of North Sichuan Medical College, Nanchong, Sichuan, P.R. China

<sup>2</sup> Department of Radiology, The First People's Hospital of Suining City, Suining, Sichuan, P.R. China

<sup>3</sup> Department of Radiology, Affiliated Hospital of Chengdu University, Chengdu, Sichuan, P.R. China

<sup>4</sup> Department of Cardio-Thoracic Surgery, Affiliated Hospital of North Sichuan Medical College, Nanchong, Sichuan, P.R. China

<sup>5</sup> Department of Gastrointestinal of Surgery, Affiliated Hospital of North Sichuan Medical College, Nanchong, Sichuan, P.R. China

<sup>6</sup> School of Basic Medical Sciences, North Sichuan Medical College, Nanchong, Sichuan, P.R. China

<sup>7</sup> Department of Radiology, Suining Central Hospital, Suining, Sichuan, P.R. China

**Author's address:** Han-Feng Yang, Sichuan Key Laboratory of Medical Imaging and Department of Radiology, Affiliated Hospital of North Sichuan Medical College, Nanchong 637000, Sichuan Province, China, e-mail: 505254007@qq.com

### Summary

**Background:**

A systematic review and meta-analysis of all available publications was performed to evaluate the diagnostic accuracy of percutaneous transthoracic needle biopsy (PTNB) using a C-Arm Cone-Beam CT (CBCT) system in patients with lung nodules.

**Material/Methods:**

The databases of PUBMED, OVID, EBSCO, EMBASE, and China National Knowledge Infrastructure (CNKI) were systematically searched for relevant original articles on the diagnostic accuracy of CBCT-guided PTNB for the diagnosis of nodules in the lungs. Diagnostic indices including sensitivity, specificity, positive likelihood ratio (PLR), negative likelihood ratio (NLR), diagnostic odds ratio (DOR) and diagnostic score (DS) were calculated. Moreover, summary receiver operating characteristic curves (SROC) were constructed with Stata (version 13.0), Rev Man (version 5.3), and Meta-disc (version 1.4) software. Other clinical indices such as incidence of complications were also recorded.

**Results:**

Eight studies met the inclusion and exclusion criteria for the meta-analysis. The pooled sensitivity, specificity, PLR, NLR, DOR, DS, and SROC with 95% confidence intervals were 0.96 (0.93–0.98), 1.00 (0.91–1.00), 711.15 (9.48–53325.89), 0.04 (0.02–0.07), 16585.29 (284.88–9.7e+05), 9.72 (5.65–13.78), and 0.99 (0.97–0.99), respectively. The incidence of pneumothorax and hemorrhage was 10–29.27% and 1.22–47.25%, respectively.

**Conclusions:**

CBCT-guided PTNB has an acceptable rate of complications and is associated with a reasonable radiation exposure. Moreover, it is a highly accurate and safe technique for the diagnosis of lung nodules and can be recommended to be used in routine clinical practice.

**MeSH Keywords:**

Biopsy • Cone-Beam Computed Tomography • Lung • Review

**PDF file:**

<http://www.polradiol.com/abstract/index/idArt/899626>

## Background

An accurate diagnosis of a pulmonary nodule is of high importance, as the patient may benefit from either conservative, surgical or chemotherapeutic treatment options [1–3]. Percutaneous transthoracic needle biopsy (PTNB) with image guidance has been regarded as a highly safe and accurate diagnostic technique for assessing both benign and malignant lung nodules [4–6]. Generally, PTNB can be performed under various image guidance modalities such as ultrasonography (USG), conventional fluoroscopy, computed tomography (CT) and CT fluoroscopy. PTNB under USG is the quickest, safest and least expensive of all the modalities but is not appropriate for a safe sampling of deep nodular lesions [7]. CT-guided PTNB, considered both accurate and safe [8], is being increasingly used in many medical centers, replacing conventional fluoroscopy as the primary method of guidance. However, conventional CT guidance has its limitations due to the lack of real-time monitoring and gantry tilting for a more accessible needle pathway to the target lesion [9].

CT fluoroscopy, which allows both a real-time monitoring of target lesions and gantry tilting [10], overcomes the disadvantages posed by conventional CT guidance and is considered as the gold standard technique to guide percutaneous biopsies of pulmonary nodules [11]. Nevertheless, limitations in these procedure do exist and include a small gantry bore, limited imaging plane orientation and radiation exposure to operators [12]. In the recent years, we have seen the introduction of C-arm cone-beam CT (CBCT) with a flat-panel detector system into clinical practice, in which a cone-beam x-ray tube and a flat-panel detector are fitted to a C-arm gantry. This allows us to work with a real-time fluoroscopy, angiography, CT images and subsequent 3D reconstructions [13].

We realize that numerous studies have been published on the diagnostic accuracy of PTNB with the use of the CBCT system in patients with lung nodules [14–31]. However, there are no studies in which researchers have investigated the diagnostic accuracy of CBCT-guided PTNB by way of a systematic review or a meta-analysis. Therefore, the purpose of this article was to investigate the value of CBCT-guided PTNB in the diagnosis of pulmonary nodules through a systematic review and meta-analysis.

## Material and Methods

### Literature search

One reviewer identified all available publications. The databases of PUBMED, OVID, EBSCO, EMBASE, and China National Knowledge Infrastructure (CNKI) were comprehensively searched from their inception to December 2015. The literature search in the PUBMED database was conducted with the following search terms:

#1: ("C-Arm Cone-Beam CT" OR "C-Arm Cone-Beam computed tomography" OR "CBCT" OR "C-Arm");

#2: ("lung" OR "lung cancers" OR "lung nodules" OR "lung lesions" OR "lung masses");

#3: ("sensitivity" OR "specificity" OR "true positive" OR "true negative" OR "false positive" OR "false negative" OR "diagnosis" OR "detection" OR "accuracy");

#4: #1 AND #2 AND #3.

Other databases, such as Springer link were also searched for relevant articles. Two observers independently checked the reference list of all documents initially found in the PUBMED, EMBASE and other databases to look for additional articles. Publication date or language was not restricted. The articles were limited to studies in humans. The following publication types were excluded – review articles, commentaries, letters and case reports. The remaining relevant articles were then taken into consideration based upon their title and/or abstract.

### Inclusion and exclusion criteria

Two investigators checked every potential study independently. Disagreements were resolved in consensus with another researcher. The documents with the following characteristics were included in this systematic review and meta-analysis – (a) Focus on the value of CBCT-guided PTNB in the diagnosis of pulmonary nodules; (b) Imaging and/or close clinical follow-up (at least 6 months) and/or careful surgical inspection and/or histopathological analysis were/was used as the reference standard; (c) Both prospective and retrospective studies; (d) Sufficient data [TP (true-positive), TN (true-negative), FP (false-positive), and FN (false-negative)] could be found or calculated from the original study; and (e) Studies having at least 20 subjects.

Studies that did not fulfill the inclusion criteria were not taken into consideration. Moreover, studies with a large number of subjects were considered for evaluation so as to avoid duplication of information. Emails were sent to those authors for missing data if their studies did not report sufficient data.

### Data extraction and quality evaluation

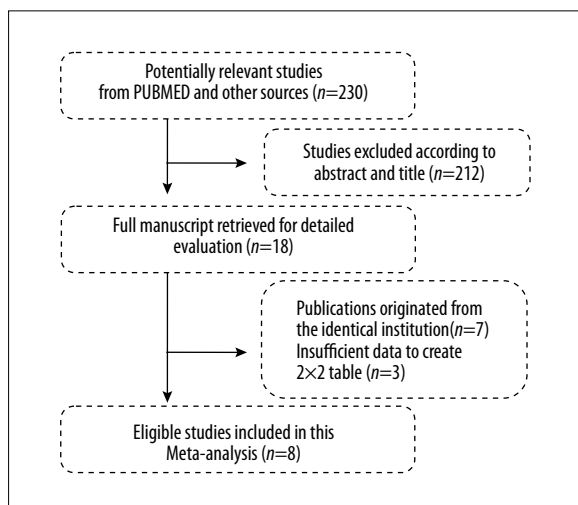
All publications meeting the inclusion criteria were evaluated. Three investigators independently conducted the relevant data extraction and quality assessment. Debates were resolved through discussion.

Methodological quality was assessed independently according to the QUADAS-2 (Quality Assessment of Studies of Diagnostic Accuracy included on Systematic Reviews) guidelines as provided by Whiting et al. [32]. Disagreements were resolved in consensus with another researcher.

For each article, the following data were extracted: (a) study descriptions (first author, publishing year, study design etc.); (b) baseline characteristics of the participants (age, number of nodules, lesion size, etc.); (c) characteristics of the procedures (technical success rate, procedure time, radiation doses, biopsy needle and complications); and (d) data on TP, FP, TN and FN.

### Statistical analysis

Standard methods recommended for meta-analyses of diagnostic tests were used [33]. Pooled estimates of sensitivity, specificity, positive likelihood ratio (PLR), negative likelihood ratio (NLR), diagnostic odds ratio (DOR) and



**Figure 1.** Flow chart of study selection.

diagnostic score (DS) were calculated at a patient level. A constructed summary receiver operating characteristic (SROC) curve was calculated to present the accuracy of CBCT-guided PTNB for lung nodules. A bivariate mixed-effects binary regression modeling framework was used to calculate the pooled estimates of sensitivity, specificity, PLR, NLR, DOR, DS, and area under the curve (AUC). Heterogeneity was evaluated by calculating the  $I^2$  statistic [33,34], ranging from 0% (no heterogeneity) to 100% (great heterogeneity) with less than 50%  $I^2$  statistic across the included studies considered to possess either absent or moderate heterogeneity. The Spearman rank correlation test was applied to assess the threshold effect among the studies. Sensitivity analysis and subgroup analysis were also conducted whenever possible. Analyses of all the statistics in this systematic review and meta-analysis were performed with Stata (version 13.0), Rev Man (version 5.3), and Meta-disc (version 1.4) software. P values of less than 0.05 were considered to be of statistical significance.

## Results

### Literature retrieval and the results

Two hundred and thirty original articles were identified for selection after a thorough computer literature search and a careful verification of references. After screening the titles and abstracts, 212 items were excluded because one or more inclusion criteria were not fulfilled. The remaining 18 studies were evaluated by reading the full text. Of these, 7 were excluded because the subjects enrolled in these studies originated from the same institution or medical center [22–28]; 3 were excluded because of insufficient data to construct  $2 \times 2$  tables of TP, FP, FN, and TN [29–31]. As a result, only 8 articles [14–21] were included in this meta-analysis, having met the inclusion criteria. Figure 1 shows a detailed flowchart of study selection and the results of this systematic review and meta-analysis.

### Document description

All of the 8 studies were published in English and included 1664 subjects altogether. The average number of

participants was 208 (range from 27 to 1108) with age ranging from 9 to 89 years. Seven of the studies [14,16–21] were retrospective whereas one study [15] was prospective. Of these, 4 studies [14,16–28] were conducted in different medical institutions in South Korea, whereas the other 4 studies [15,19–21] were conducted in different institutions all over the world. Information about the technical statements of PTNB using CBCT and other basic descriptions of the 8 articles involved in this systematic review and meta-analysis are listed in Table 1. Figure 2 shows the methodological quality of the included 8 studies as assessed by the QUADAS-2 evidence-based tool.

### Diagnostic accuracy of PTNB using CBCT

The pooled statistical results of this meta-analysis indicated that: sensitivity, specificity, PLR, NLR, DOR, DS and AUC with 95% confidence intervals were 0.96 (0.93–0.98), 1.00 (0.91–1.00), 711.15 (9.48–53325.89), 0.04 (0.02–0.07), 16585.29 (284.88–9.7e+05), 9.72 (5.65–13.78), and 0.99 (0.97–0.99), respectively. A forest plot (Figure 3) lists the sensitivity, specificity, and 95% confidence intervals for each study in detail. The forest plot in Figure 4 summarizes the PLR, NLR, and 95% confidence intervals for each study in detail. The forest plots of the DOR and DS are shown in Figures 5 and 6, respectively. The AUC was 0.99, indicating a very good overall diagnostic accuracy of CBCT-guided PTNB for lung nodules across the 8 studies (shown in Figure 7). A subgroup analysis (data not shown) was also performed on the basis of the country in which the investigations were conducted (South Korean vs. Non-South Korean).

### Heterogeneity, threshold effect and sensitivity analysis

$I^2$  values (%) of sensitivity, specificity, PLR, NLR, DOR and DS were 62.20 (95% confidence intervals: 33.15–91.26), 81.13 (95% confidence intervals: 68.81–93.44), 62.37 (95% confidence intervals: 62.37–92.88), 63.84 (95% confidence intervals: 36.29–91.39), 91.97 (95% confidence intervals: 87.83–96.10), and 47.93 (95% confidence intervals: 5.78–90.09), respectively, which indicated that there were different degrees of heterogeneity across the eight investigations. The Spearman correlation coefficient was equal to 0.119 ( $p=0.77$ ), indicating that there was no threshold effect in this systematic review and meta-analysis. Furthermore, the sensitivity analysis results showed that the data in this systematic review and meta-analysis were in a relatively robust situation (data not shown).

### Radiation exposure dose and complications

The mean total procedure time was documented to be between 12 to 32 minutes, with a mean radiation exposure dose ranging from 2.9 to 14.3 mSv. The incidence of procedure-related pneumothorax was between 10% to 29.27%, and the rate of chest tube drainage was reported to range from 1.22% to 47.25%. The rate of hemorrhage ranged between 1.22% to 47.25%, with one patient requiring bronchial artery embolization, as reported in the study by Lee et al. [18]. In addition, there was one case of subcutaneous emphysema in the study by Choi et al. [17]. Apart from the adverse effects mentioned above, no other complications

**Table 1.** Characteristics of the included studies.

Study	Year	Reference	Country	Design	Number of subjects	Male/Female	Age (years)	Biopsies	Lesion size (mm)	Procedure time (min)
Hwang	2010	14	Korea	Retro	27	9/18	64 (39-84)	27	12±4.3	12±4
Braak	2012	15	Netherlands	Pro	82	57/25	64.6 (24-85)	84	32.5	18
Lee	2012	16	Korea	Retro	91	64/27	62 (26-85)	94	37±23	ND
Choi	2012	17	Korea	Retro	98	58/40	58 (30-88)	99	30±16	11.9±4.0
Lee	2014	18	Korea	Retro	1108	633/475	62.4 (9-89)	1116	27±17	14.9±6.1
Cheng	2015	19	Taiwan	Retro	35	15/20	69±2	35	30 ± 14	32±11
Jiao	2015	20	Chinese Mainland	Retro	100	69/31	53.08 (19-88)	100	12.5±3.9	12.84±3.74
Rotolo	2016	21	Italy	Retro	123	82/41	68 (27-88)	103	19.8±6.5	ND

Study	Radiation dose (mSv)	Needle (G)	Complications (n)	TP	FP	FN	TF
Hwang	4.6	20/21	Pneumothorax (3), pneumothorax requiring drainage (1), haemoptysis (1)	16	1	1	8
Braak	25.9 Gy cm <sup>-2</sup>	18	Pneumothorax (15), pneumothorax requiring drainage (2), haemoptysis (1)	63	0	7	14
Lee	ND	21	Pneumothorax (24), pneumothorax requiring drainage (1), hemorrhage (43)	74	0	2	18
Choi	170.0±67.2 mGy	18	Pneumothorax (16), pneumothorax requiring drainage (4), haemoptysis (2), subcutaneous emphysema (1)	69	0	3	27
Lee	7.3±4.1	18	Pneumothorax (196), pneumothorax requiring drainage (13), haemoptysis (80), bronchial artery embolization (1)	733	0	33	323
Cheng	2.9 ± 1.6	18	Pneumothorax (7), pneumothorax requiring drainage (1), haemoptysis (4)	32	0	1	2
Jiao	7.6±3.1	16	Pneumothorax (10), pneumothorax requiring drainage (2), haemoptysis (12)	77	2	1	19
Rotolo	14.3±10.0	20	Pneumothorax (36), pneumothorax requiring drainage (6), minor pulmonary hemorrhage (27)	64	0	10	29


Pro – prospective; Retro – retrospective; ND – not documented; TP – true positive; FP – false positive; FN – false negative; TN – true negative.

were recorded in these eight studies analyzed in this systematic review and meta-analysis.

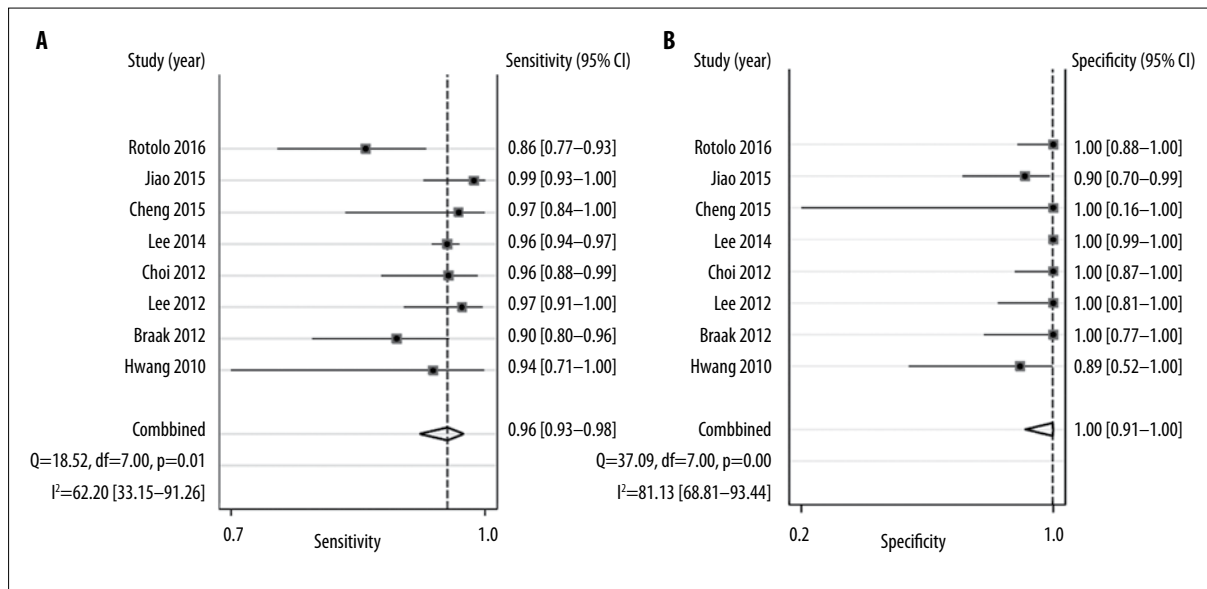
**Discussion**

In clinical practice, patients with suspected lung nodules often require a chest examination by way of radiography or computed tomography (CT) with or without administration of a contrast agent. Even then, the benign or malignant nature of the lung nodules is often difficult to be comprehensively evaluated on the basis of simple morphological changes in the imaging studies such as chest radiography or CT. In such situations, an image-guided percutaneous lung biopsy is often recommended. Among the interventional procedures, PTNB with CBCT has played an essential role in the diagnosis of patients with lung nodules since its introduction [13,35]. With respect to CBCT-guided PTNB, a foundation has already been laid [14-31], with a variety of clinical applications and ongoing investigations being performed using a CBCT system [36,37].

Several previously published systematic reviews or meta-analyses had been conducted with the purpose of obtaining the diagnostic values of conventional fluoroscopy, CT, ultrasonography (US), endoscopic ultrasound (EUS), and endobronchial ultrasound-guided (EBUS) PTNB for the diagnosis of pulmonary lesions [38-41]. Lacasse et al. reported that PTNB can be useful for the diagnosis of solitary or localized lesions in the lung [38]. Micames et al. showed that EUS-guided PTNB is a safe procedure for the invasive staging of lung cancer with an added advantage of increased sensitivity of confirming metastasis to mediastinal lymph nodes seen on CT scans and a potential to prevent unnecessary surgery in a large proportion of cases, which was not possible with CT [39]. Gu et al. found that EBUS-guided PTNB was a cost-effective, safe and accurate modality for the staging of lung neoplasms, and the sensitivity of EBUS-guided PTNB can be enhanced by selecting patients with lymphadenopathy in CT or PET studies [40]. Yang et al. stated that the CT-guided PTNB is a useful tool for the diagnosis and management of ground-glass opacity



**Figure 2.** Quality assessment of diagnostic accuracy studies and criteria for included studies.



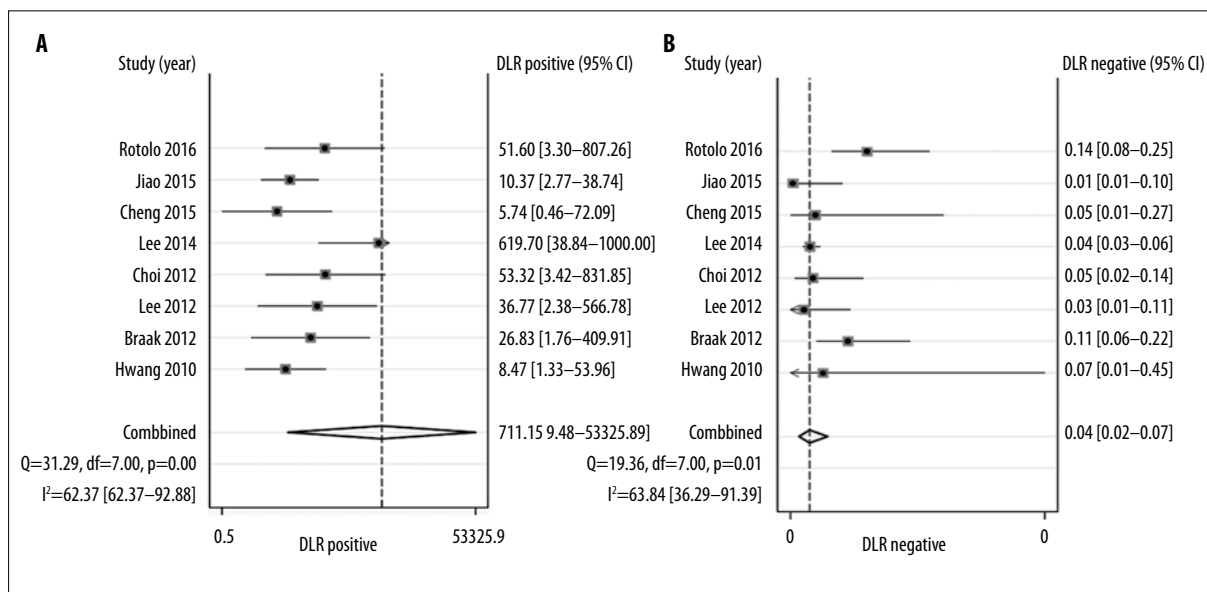
**Figure 3.** Forest plot shows sensitivity (Sen) and specificity (Spe) from the eight studies and pooled estimates. Pooled Sen and Spe were 0.96 (95% CI, 0.93–0.98) and 1.00 (95% CI, 0.91–1.00), respectively.

(GGO) lesions in the lung parenchyma [41]. However, all the four studies mentioned above either focused on the overall accuracy of PTNB or did not calculate the diagnostic accuracy values of CBCT-guided PTNB.

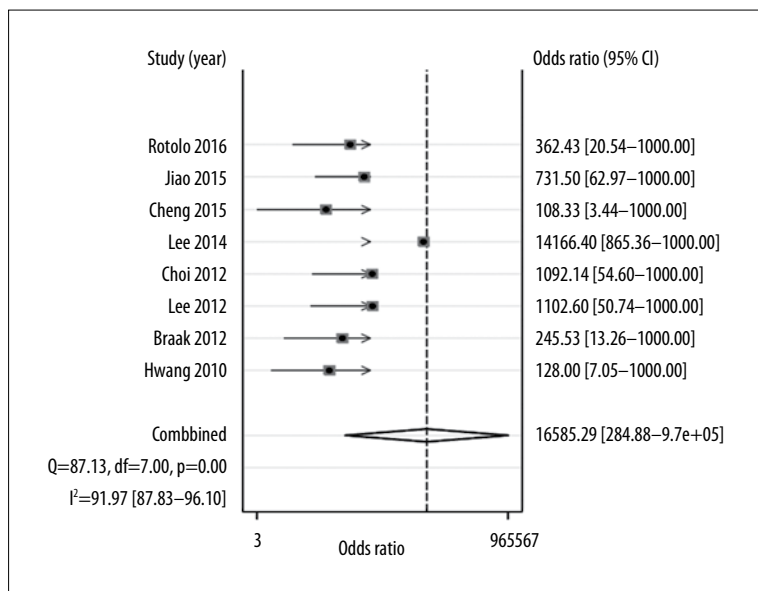
This study was in line with the reporting standards recommended by the meta-analysis of diagnostic and screening tests group [42]. To the best of our knowledge, this is the first study that has evaluated the diagnostic accuracy of CBCT-guided PTNB for lung nodules by way of a systematic review and meta-analysis. The study herein includes 8 eligible studies and found that CBCT-guided PTNB can be used as one of the primary examinations for lung nodules with a relatively high diagnostic accuracy. The systematic review and meta-analysis results reported herein also

showed that CBCT-guide PTNB has an excellent accuracy in the diagnosis of lung nodules, with an AUC of 0.99. Taking the pooled results of sensitivity, specificity, PLR, NLR, DOR, DS, and AUC into account, CBCT-guided PTNB has a potential to raise the accuracy of diagnosing lung nodules.

The reported complications of CBCT-guided PTNB in the lungs include pneumothorax, hemorrhage, haemoptysis, chest pain, air embolism, procedure-related death and needle tract metastasis, among which the most common complications are pneumothorax and hemorrhage [14–31]. Fortunately, there were no severe complications such as air embolism, procedure-related death or needle tract metastasis in the eligible eight studies. The incidence of adverse effects in these studies was considered to be within an acceptable



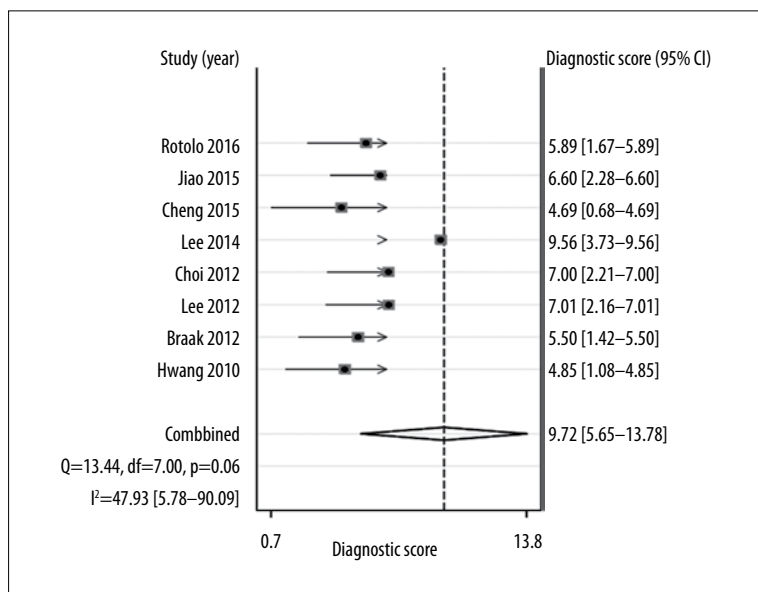
**Figure 4.** Forest plot shows positive likelihood ratio(+LR) and negative likelihood ratio(-LR) from the eight studies and pooled estimates. Pooled +LR and -LR were 711.15 (95CI, 9.48–53325.89) and 0.04 (95CI, 0.02–0.07), respectively.



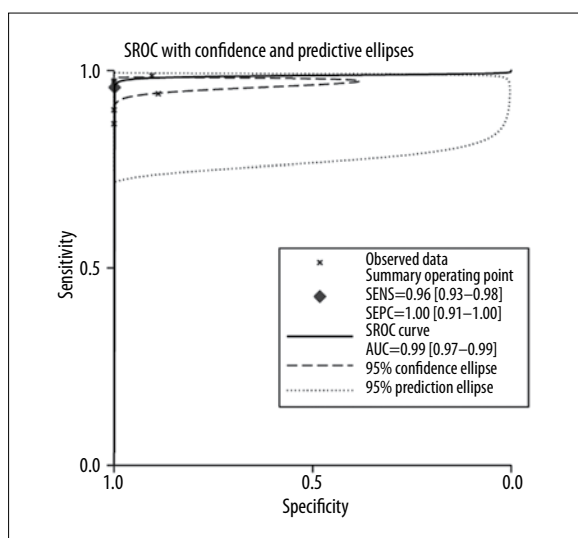
**Figure 5.** Forest plot shows diagnostic odds ratio (DOR) from the eight studies and pooled estimates. Pooled DOR was 16585.29 (95%CI: 284.88–9.7e+05).

range. In terms of CBCT-guided PTNB-related complications, pneumothorax was reported to occur in approximately 17.0% (196) and haemoptysis in 6.9% (80) of all lung biopsy cases in the largest study conducted by Lee et al. [18]. Of the 196 cases of pneumothorax, only 6.6% (1.1% of all 1153 PTNBs) required drainage with catheter insertion [18]. As for hemorrhage, bronchial artery embolization was required in only one patient (1.3%) because of a massive hemorrhage in the same study [18]. The incidence of procedure-related complications was distinctly low in our meta-analysis study. It is reasonable to think that this very low incidence of procedure-related complications was possible as the CBCT system enabled the investigators to select a safer and more accurate targeting route in navigating the needle to the target during PTNB. Furthermore, the coaxial needle technique also played an essential role in the reduction of complications by avoiding repeated pleural punctures or passages [24].

Major risk factors for pneumothorax were gender, age, underlying diseases, use of virtual guidance, lesion size, lesion location, emphysema along the needle pathway, number of pleural passages and procedure time [14–31]. Risk factors for hemorrhage included gender, age, lesion location, nodule type, distance from the pleura to the target lesion, number of tissue samplings, and use of virtual guidance with deeper-located lesions and GGO nodules. [14–31]. Interestingly, the use of virtual guidance was also a significant protective factor for the occurrence of both pneumothorax and hemorrhage [18]. In addition, the needle-pleural angle is a novel predictor of pneumothorax reported by Li et al. [8]. De et al. mentioned that non-calcified density was a positive predictive factor for the diagnosis, whereas the use of MPR (multiplanar reformatting) imaging, an useful method to plan the needle path while performing needle aspiration, can improve the diagnostic accuracy of CT-guided PTNB [43].



**Figure 6.** Forest plot shows diagnostic score (DS) from the eight studies and pooled estimates. Pooled DS was 9.72 (95%CI: 5.65–13.78).



**Figure 7.** Summary receiver operating characteristic (SROC) curve. Area under the SROC curve (AUC) was 1.00 (95%CI: 0.97–0.99).

Another important issue during CBCT-guided PTNB is radiation exposure. The selection of a biopsy procedure with a low radiation dose is important for patient’s safety. From our data extraction, it was revealed that an effective dose for CBCT-guided PTNB had been reported in all of the studies [14,15,17–21] except for the study conducted by Lee et al. [16]. The reported mean estimated effective patient radiation dose ranged between 4.6–14.3 mSv (mean, 7.34 mSv) [14,18–21]. In the study by Jin et al. [22], radiation dose was estimated at 272±116 mGy (range: 36–528 mGy). Braak et al. reported a mean DAP value of 25.9 (range: 3.9–80.5) Gy.cm-2 [15]. The differences between these studies can be explained by the following reasons: (a) Choo et al. [24], Choi et al. [23] and Lee et al. [18] usually performed three CBCT scans (pre-procedure, intra-procedure, and post-procedure) per case, whereas Hwang et al. [14] performed only two CBCT scans foregoing a post-procedural CBCT scan; (b) Choo et al. [24],

Choi et al. [23] and Lee et al. [18] utilized a high-quality CT mode (90 kV, 192 mA) to obtain high-quality CT images, whereas Hwang et al. [14] used a lower-quality angiography mode (92 kV, 28 mA). It has been shown that CBCT-guided PTNB results in a significant reduction of radiation exposure compared to other modalities such as conventional CT and fluoroscopic guidance and it can be a safe and useful procedure for diagnosing pulmonary lesions[44–47]. The decrease in radiation exposure in CBCT-guided PTNB, to both the patient and the operator, has been attributed to the application of a small field of view or collimation [18].

Our research was based upon a comprehensive literature retrieval and meticulous data extraction. However, a few limitations should be taken into account in our analysis. Firstly, most studies included in our meta-analysis had a retrospective design, thus, there may have been a selection bias. Secondly, there was the presence of indeterminate nodules or non-diagnosed patients in the enrolled studies, which may have led to a higher estimate of the diagnostic accuracy of CBCT-guide PTNB for lung nodules. Thirdly, these studies do not compare between the diagnostic accuracy of CBCT-guide PTNB and CT-guided or CT fluoroscopy-guided biopsy. Therefore, we cannot currently recommend which method of is better. Nevertheless, there is a significant reduction in radiation exposure time in CBCT-guided PTNB compared to methods such as conventional CT and fluoroscopic guidance [44–47] which obviously is beneficial to the patient. Finally, our study was based on studies that were published in English only, which hypothetically might have caused the so-called “Tower of Babel” bias [48]. Lastly, further prospective studies need to be performed to compare different methods for diagnosing lung nodules.

### Conclusions

In conclusion, despite the above-mentioned problems, we believe that PTNB under CBCT guidance can be recommended in clinical practice, considering its high diagnostic accuracy and the number of complications and radiation exposure in an acceptable range. For future research, it is



important to improve study design and reporting of accuracy results. When more data become available, an update of this systematic analysis and meta-analysis should be conducted.

### Acknowledgements

The authors would like to thank Morgan B McClure from North Sichuan Medical College's Affiliated Nanchong Central Hospital of China's Sichuan Province for his help in proof reading the article.

### References:

- Lederlin M, Revel MP, Khalil A et al: Management strategy of pulmonary nodule in 2013. *Diagn Interv Imaging*, 2013; 94: 1081–94
- Sayyoub M, Vummidri DR, Kazerooni EA: Evaluation and management of pulmonary nodules: State-of-the-art and future perspectives. *Expert Opin Med Diagn*, 2013; 7: 629–44
- Sim HJ, Choi SH, Chae EJ et al: Surgical management of pulmonary adenocarcinoma presenting as a pure ground-glass nodule. *Eur J Cardiothorac Surg*, 2014; 46: 632–36
- Ohno Y, Hatabu H, Takenaka D et al: CT-guided transthoracic needle aspiration biopsy of small (< or =20 mm) solitary pulmonary nodules. *Am J Roentgenol*, 2003; 180: 1665–69
- Carlson SK, Felmlee JP, Bender CE et al: CT fluoroscopy guided biopsy of the lung or upper abdomen with a breath-hold monitoring and feedback system: A prospective randomized controlled clinical trial. *Radiology*, 2005; 237: 701–8
- Hiraki T, Mimura H, Gohara H et al: CT fluoroscopy-guided biopsy of 1,000 pulmonary lesions performed with 20-gauge coaxial cutting needles: Diagnostic yield and risk factors for diagnostic failure. *Chest*, 2009; 136: 1612–17
- Sheth S, Harper UH, Stanley DB et al: US guidance for thoracic biopsy: A valuable alternative to CT. *Radiology*, 1999; 210: 721–26.
- Li Y, Du Y, Yang HF et al: CT-guided percutaneous core needle biopsy for small (≤20 mm) pulmonary lesions. *Clin Radiol*, 2013; 68: e43–48
- Geraghty PR, Kee ST, McFarlane G et al: CT-guided transthoracic needle aspiration biopsy of pulmonary nodules: Needle size and pneumothorax rate. *Radiology*, 2003; 229: 475–81
- Yamagami T, Kato T, Iida S et al: Percutaneous needle biopsy for small lung nodules beneath the rib under CT scan fluoroscopic guidance with gantry tilt. *Chest*, 2004; 126: 744–47
- Heck SL, Blom P, Berstad A. Accuracy and complications in computed tomography fluoroscopy-guided needle biopsies of lung masses. *Eur Radiol*, 2006; 16: 1387–92
- Prosch H, Stadler A, Schilling M et al: CT biopsy mode guided lung biopsies: Accuracy, complications and radiation dose. *Eur J Radiol*, 2011; 81: 1029–33
- Wallace MJ, Kuo MD, Glaiberman C et al: Three-dimensional C-arm cone-beam CT: Applications in the interventional suite. *J Vasc Interv Radiol*, 2008; 19: 799–813
- Hwang HS, Chung MJ, Lee JW et al: C-arm cone-beam CT-guided percutaneous transthoracic lung biopsy: Usefulness in evaluation of small pulmonary nodules. *Am J Roentgenol*, 2010; 195: W400–7
- Braak SJ, Herder GJ, van Heeswijk JP et al: Pulmonary masses: Initial results of cone-beam CT guidance with needle planning software for percutaneous lung biopsy. *Cardiovasc Intervent Radiol*, 2012; 35: 1414–21
- Lee WJ, Chong S, Seo JS et al: Transthoracic fine-needle aspiration biopsy of the lungs using a C-arm cone-beam CT system: Diagnostic accuracy and post-procedural complications. *Br J Radiol*, 2012; 85: e217–22
- Choi MJ, Kim Y, Hong YS et al: Transthoracic needle biopsy using a C-arm cone-beam CT system: Diagnostic accuracy and safety. *Br J Radiol*, 2012; 85: e182–87
- Lee SM, Park CM, Lee KH et al: C-arm cone-beam CT-guided percutaneous transthoracic needle biopsy of lung nodules: Clinical experience in 1108 patients. *Radiology*, 2014; 271: 291–300
- Cheng YC, Tsai SH, Cheng Y et al: Percutaneous transthoracic lung biopsy: Comparison between C-arm Cone-beam CT and conventional CT guidance. *Transl Oncol*, 2015; 8: 258–64
- Jiao D, Yuan H, Zhang Q et al: Flat detector C-arm CT-guided transthoracic needle biopsy of small (≤2.0 cm) pulmonary nodules: Diagnostic accuracy and complication in 100 patients. *Radiol Med*, 2016; 121: 268–78
- Rotolo N, Floridi C, Imperatori A et al: Comparison of cone-beam CT-guided and CT fluoroscopy-guided transthoracic needle biopsy of lung nodules. *Eur Radiol*, 2016; 26: 381–89
- Jin KN, Park CM, Goo JM et al: Initial experience of percutaneous transthoracic needle biopsy of lung nodules using C-arm cone-beam CT systems. *Eur Radiol*, 2010; 20: 2108–15
- Choi JW, Park CM, Goo JM et al: C-arm cone-beam CT-guided percutaneous transthoracic needle biopsy of small (≤20 mm) lung nodules: Diagnostic accuracy and complications in 161 patients. *Am J Roentgenol*, 2012; 199: W322–30
- Choo JY, Park CM, Lee NK et al: Percutaneous transthoracic needle biopsy of small (≤1 cm) lung nodules under C-arm cone-beam CT virtual navigation guidance. *Eur Radiol*, 2013; 23: 712–19
- Cheung JY, Kim Y, Shim SS et al: Combined fluoroscopy and CT-guided transthoracic needle biopsy using a C-arm cone beam CT system: Comparison with fluoroscopy-guided biopsy. *Korean J Radiol*, 2011; 12: 89–96
- Floridi C, Muollo A, Fontana F et al: C-arm cone-beam computed tomography needle path overlay for percutaneous biopsy of pulmonary nodules. *Radiol Med*, 2014; 119: 820–27
- Jiao de C, Li TF, Han XW et al: Clinical applications of the C-arm cone-beam CT-based 3D needle guidance system in performing percutaneous transthoracic needle biopsy of pulmonary lesions. *Diagn Interv Radiol*, 2014; 20: 470–74
- Jiao DC, Li ZM, Yuan HF et al: Flat detector C-arm CT-guidance system in performing percutaneous transthoracic needle biopsy of small (≤3 cm) pulmonary lesions. *Acta Radiol*, 2016; 57: 677–83
- Busser WM, Braak SJ, Fütterer JJ et al: Cone beam CT guidance provides superior accuracy for complex needle paths compared with CT guidance. *Br J Radiol*, 2013; 86: 20130310
- Hohenforst-Schmidt W, Zarogoulidis P, Vogl T et al: Cone beam computer tomography (CBCT) in interventional chest medicine-high feasibility for endobronchial realtime navigation. *J Cancer*, 2014; 5: 231–41
- Jaconi M, Pagni F, Vacirca F et al: C-arm cone-beam CT-guided transthoracic lung core needle biopsy as a standard diagnostic tool: An observational study. *Medicine (Baltimore)*, 2015; 94: e698
- Whiting PF, Rutjes AW, Westwood ME et al: QUADAS-2: A revised tool for the quality assessment of diagnostic accuracy studies. *Ann Intern Med*, 2011; 155: 529–36
- Deville WL, Buntinx F, Bouter LM et al: Conducting systematic reviews of diagnostic studies: Didactic guidelines. *BMC Med Res Methodol*, 2002; 2: 9
- Higgins JP, Thompson SG, Deeks JJ et al: Measuring inconsistency in meta-analyses. *BMJ*, 2003; 327: 557–60
- Raj S, Irani FG, Tay KH et al: C-arm cone beam computed tomography: A new tool in the interventional suite. *Ann Acad Med Singapore*, 2013; 42: 585–92
- Kim HC: Role of C-arm cone-beam CT in chemoembolization for hepatocellular carcinoma. *Korean J Radiol*, 2015; 16: 114–24

### Conflict of interest

The authors declare that there is no conflict of interest.



37. Erovic BM, Chan HH, Daly MJ et al: Intraoperative cone-beam computed tomography and multi-slice computed tomography in temporal bone imaging for surgical treatment. *Otolaryngol Head Neck Surg*, 2014; 150(1): 107–14
38. Lacasse Y, Wong E, Guyatt GH et al: Transthoracic needle aspiration biopsy for the diagnosis of localised pulmonary lesions: A meta-analysis. *Thorax*, 1999; 54: 884–93
39. Micames CG, McCrory DC, Pavey DA et al: Endoscopic ultrasound guided fine-needle aspiration for non-small cell lung cancer staging: A systematic review and Meta analysis. *Chest*, 2007; 131: 539–48
40. Gu P, Zhao YZ, Jiang LY et al: Endobronchial ultrasound guided transbronchial needle aspiration for staging of lung cancer: A systematic review and meta-analysis. *Eur J Cancer*, 2009; 45: 1389–96
41. Yang JS, Liu YM, Mao YM et al: Meta-analysis of CT-guided transthoracic needle biopsy for the evaluation of the ground-glass opacity pulmonary lesions. *Br J Radiol*, 2014; 87: 20140276
42. Deeks JJ: Systematic reviews in health care: Systematic reviews of evaluations of diagnostic and screening tests. *BMJ*, 2001; 323: 157–62
43. De Filippo M, Saba L, Concari G et al: Predictive factors of diagnostic accuracy of CT-guided transthoracic fine-needle aspiration for solid noncalcified, subsolid and mixed pulmonary nodules. *Radiol Med*, 2013; 118: 1071–81
44. Braak SJ, van Strijen MJ, van Es HW et al: Effective dose during needle interventions: cone-beam CT guidance compared with conventional CT guidance. *J Vasc Interv Radiol*, 2011; 22: 455–61
45. Steinfurt DP, Einsiedel P, Irving LB: Radiation dose to patients and clinicians during fluoroscopically-guided biopsy of peripheral pulmonary lesions. *Respir Care*, 2010; 55: 1469–74
46. Strocchi S, Colli V, Conte L: Multidetector CT fluoroscopy and cone-beam CT-guided percutaneous transthoracic biopsy: Comparison based on patient doses. *Radiat Prot Dosimetry*, 2012; 151: 162–65
47. Ben-Shlomo A, Cohen D, Bruckheimer E et al: Comparing effective doses during image-guided core needle biopsies with computed tomography versus C-arm cone beam CT using adult and pediatric phantoms. *Cardiovasc Intervent Radiol*, 2016; 39(5): 732–39
48. Yan GW, Yan GW, Sun QQ et al: Computed tomography fluoroscopy guided percutaneous lung biopsy for ground-glass opacity pulmonary lesions: A meta-analysis. *World J Meta-Anal*, 2016; 4: 55–62