



Received: 2016.05.05
Accepted: 2016.05.27
Published: 2017.01.15

Authors' Contribution:

- A** Study Design
- B** Data Collection
- C** Statistical Analysis
- D** Data Interpretation
- E** Manuscript Preparation
- F** Literature Search
- G** Funds Collection

Successful Post-Pancreatitis Pseudoaneurysm Coagulation by Percutaneous Computed Tomography (CT)-Guided Thrombin Injection

Laura Spezia^{ABCDEF}, Carlo Sozzi^{ABCDEF}, Alberto Contro^{ABCDEF},
Giancarlo Mansueto^{ABCDEF}

Department of Radiology, G.B. Rossi Hospital, University of Verona, Verona, Italy

Author's address: Laura Spezia, Department of Radiology, G.B. Rossi Hospital, University of Verona, Piazzale L.A. Scuro 10, 37134 Verona, Italy, e-mail: laura.spezia@gmail.com

Summary

Background:

Pseudoaneurysm is a rare but potentially life-threatening vascular complication of acute pancreatitis, with a mortality rate of 20–43% in untreated patients. The treatment usually involves trans-arterial embolization or surgical resection.

Case Report:

A 44-year-old man with a history of acute pancreatitis developed a pseudoaneurysm of the pancreatic tail, diagnosed as a splenic artery pseudoaneurysm by CT. Selective arteriography performed with the purpose of embolization did not reveal the pseudoaneurysm.

The day after, under CT guidance, human thrombin (1,000 IU) was injected inside the aneurysmatic sac with its complete occlusion. A control MRI 6 months later confirmed a complete resolution of the pseudoaneurysm.

Conclusions:

Percutaneous coagulation of a post-pancreatitis pseudoaneurysm is a relatively easy and safe procedure, and it can be considered as an alternative to trans-arterial embolization when the pseudoaneurysm cannot be visualized on selective arteriography.

MeSH Keywords:

Aneurysm, False • Pancreatitis • Radiology, Interventional

PDF file:

<http://www.polradiol.com/abstract/index/idArt/899431>

Background

Pseudoaneurysm is an uncommon but potentially fatal vascular complication of acute pancreatitis, which forms as a result of erosion of the wall of a visceral artery and has a fibrous capsule that tends to grow due to persistently high arterial pressure [1–3].

The arteries involved are in close proximity to the pancreas, including the splenic, hepatic, gastroduodenal and pancreaticoduodenal arteries [4].

The incidence of hemorrhage secondary to pseudoaneurysm is around 10%, with a high mortality rate of 20–43% in untreated patients [5,6].

The percutaneous approach is increasingly used as an alternative to surgery for the treatment of visceral artery

pseudoaneurysms [7,8]. Trans-arterial embolization has high success rates in the treatment of these lesions [9].

Percutaneous injection of thrombin for coagulation of pseudoaneurysms was first described in 1986 [10]. Since then, ultrasound or CT-guided injection of thrombin has become a well-recognized treatment for a variety of peripheral and visceral pseudoaneurysms and is often used following a failed attempt of embolization [11,12].

We report the case of a patient affected by a pseudoaneurysm of the short gastric arteries treated with a CT-guided percutaneous thrombin injection directly into the pseudoaneurysm, with a technical and clinical success after 6 months. This demonstrates that percutaneous coagulation can be an alternative to trans-arterial embolization when the pseudoaneurysm cannot be documented during arteriography.

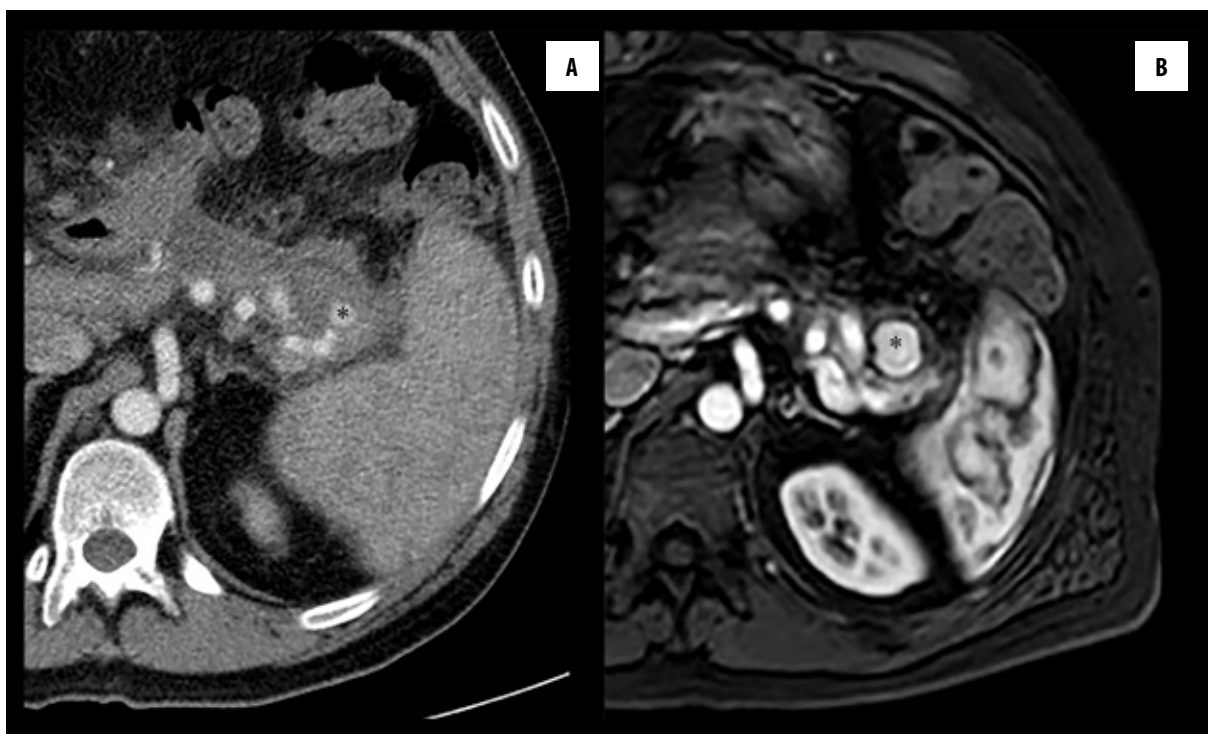


Figure 1. (A) Contrast-enhanced CT scan demonstrates a pseudoaneurysm (asterisk) of the pancreatic tail of 1.2 cm. (B) Contrast-enhanced MRI performed after one month shows an increase in the size of the pseudoaneurysmatic sac.

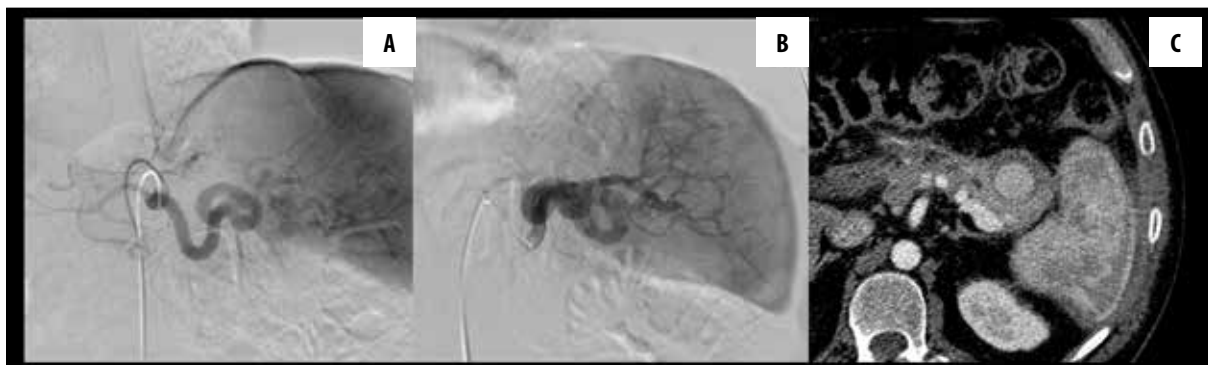

Figure 2. Selective angiography of the celiac trunk (A) and splenic artery (B) does not demonstrate the perfusion of the pseudoaneurysm. (C) CT scan performed immediately after the diagnostic angiography shows the persistence of the pseudoaneurysm.

Case Report

A 44 year-old man with a history of pancreatic disease had his first episode of biliary acute necrotizing pancreatitis followed by pseudocyst formation.

Three months after discharge, he underwent cholecystectomy, which provided temporary symptom relief.

One year later, he underwent endoscopic placement of pancreatic endoprosthesis. Two weeks after the procedure he was admitted because of epigastric pain and worsening anemia. During hospitalization he underwent blood transfusion and endoprosthesis removal. An abdominal CT scan revealed a pseudoaneurysm of 1.2 cm in the pancreatic tail, of probable splenic origin (Figure 1A).

He was referred to our hospital for further evaluation and treatment of the pseudoaneurysm. Magnetic resonance demonstrated an increase in the size of the pseudoaneurysm (Figure 1B). One week later, selective angiography of the celiac trunk, splenic artery and superior mesenteric artery was performed with the aim of embolization; however, the pseudoaneurysm was not demonstrated (Figure 2A, 2B).

A new CT scan was immediately performed and revealed the persistence of the pseudoaneurysm, fed probably by the short gastric arteries arising from the distal portion of the splenic artery, which could not be selectively catheterized and visualized during angiography (Figure 2C).

A percutaneous injection of thrombin into the pseudoaneurysm was planned after patient's consent was obtained. The injection was performed under CT guidance. In the

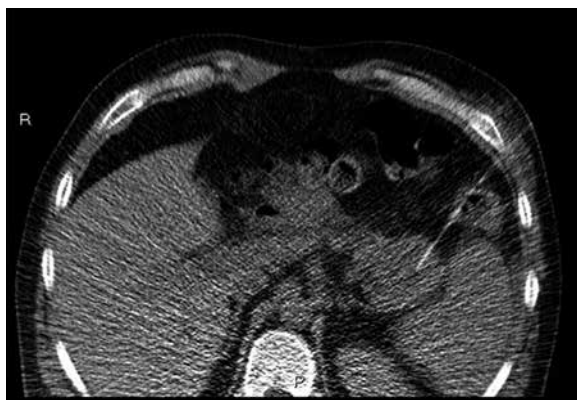

Figure 3. Axial scan during CT-guided procedure shows needle position inside the aneurysmatic sac before the injection of thrombin.

The most common vascular complications include splanchnic vein thrombosis, haemorrhage into a pseudocyst, erosions of the upper gastrointestinal arteries, formation of varices or pseudoaneurysms with a consequent risk of rupture [13–15]. Pseudoaneurysms have been attributed to autodigestion or erosion of a pseudocyst into the arterial wall with interruption of the arterial continuity. The splenic artery (40%), gastroduodenal artery (30%), inferior pancreaticoduodenal (20%), gastric (5%) and hepatic arteries (2%) are the vessels most commonly affected by the erosive process [4].

The incidence of haemorrhage secondary to pseudoaneurysm is around 10% [16] with a mortality rate ranging from 20 to 43% [5,6]. Therefore, treatment is mandatory when a radiological diagnosis of pseudoaneurysm is made, even if the patient is asymptomatic and hemodynamically stable.

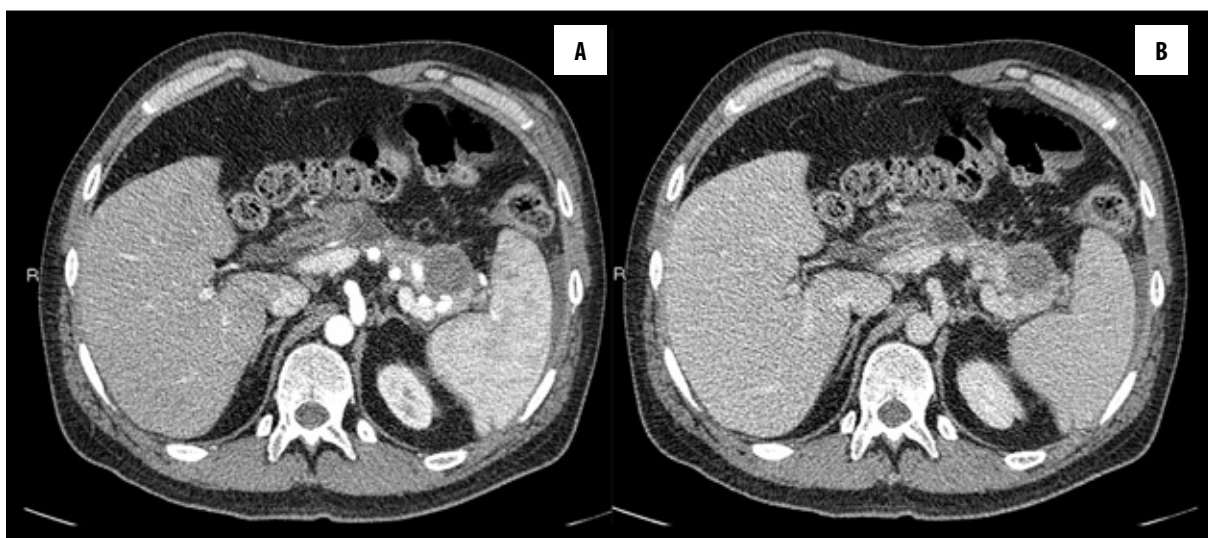


Figure 4. Contrast – enhanced CT scan performed immediately after thrombin injection shows a complete thrombosis of the pseudoaneurysm in both arterial (A) and portal (B) phases.

supine position and under local anaesthesia, Human thrombin (1,000 IU (2 ml)) was injected percutaneously into the pseudoaneurysmal sac with a 22-G needle (Chibell, Biopsy Bell) (Figure 3).

Complete occlusion of the lumen was demonstrated on contrast-enhanced CT performed immediately after the injection (Figure 4A, 4B).

Treatment success with a complete resolution of the pseudoaneurysm was confirmed on a follow-up MRI performed after 6 months (Figure 5).

Discussion

Acute pancreatitis is an acute inflammation of the pancreas that causes sudden and severe abdominal pain and elevated blood levels of pancreatic enzymes.

Major haemorrhagic arterial complications of pancreatitis are rare but life-threatening [13].

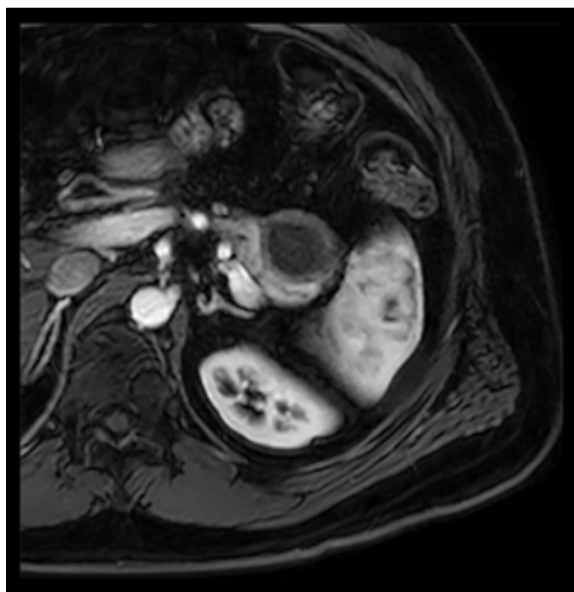


Figure 5. Follow up MRI at 6 months confirms a complete resolution of the aneurysmatic sac.

Since the splenic artery is the most common site of origin for post-pancreatitis pseudoaneurysms, we suggest trans-arterial pseudoaneurysm embolization as the first-line therapeutic approach, as suggested in the literature [17–20].

Interestingly, we demonstrated that percutaneous CT-guided embolization can be performed when the pseudoaneurysm is not seen during angiography. In our opinion, this was due to the origin of the pseudoaneurysm that was arising from the short gastric arteries and not directly from the splenic artery – superselective catheterization of these small vessels was not possible, and selective arteriography of the splenic artery (30 ml of contrast media with a flow rate of 5 ml/s) did not show the pseudoaneurysm.

Therefore, a percutaneous CT-guided injection of human thrombin into the pseudoaneurysm was performed with an immediate technical success (pseudoaneurysm coagulation) and subsequent clinical success as demonstrated by MRI performed 6 months later.

References:

- Verde F, Fishman EK, Johnson PT: Arterial pseudoaneurysms complicating pancreatitis: literature review. *J Comput Assist Tomogr*, 2015; 39(1): 7–12
- Procacci C, Mansueto G, D'Onofrio M et al: Non-traumatic abdominal emergencies: Imaging and intervention in acute pancreatic conditions. *Eur Radiol*, 2002; 12: 2407–34
- Flati G, Andren-Sandberg A, La Pinta M et al: Potentially fatal bleeding in acute pancreatitis: Pathophysiology, prevention and treatment. *Pancreas*, 2003; 26: 8–14
- Woods MS, Traverso LW, Kozarek RA et al: Successful treatment of bleeding pseudoaneurysms of chronic pancreatitis. *Pancreas*, 1995; 10: 22
- Hsu JT, Yeh CN, Hung CF et al: Management and outcome of bleeding pseudoaneurysm associated with chronic pancreatitis. *BMC Gastroenterol*, 2006; 6: 3–8
- Bergert H, Hinterseher I, Kersting S et al: Management and outcome of hemorrhage due to arterial pseudoaneurysms in pancreatitis. *Surgery*, 2005; 137: 323–28
- De Rosa A, Gomez D, Pollock JG et al: The radiological management of pseudo-aneurysms complicating pancreatitis. *JOP*, 2012; 13: 660–66
- Williams M, Alderson D, Virjee J, Callaway M: CT-guided percutaneous thrombin injection for treatment of an inferior pancreaticoduodenal artery pseudoaneurysm. *Cardiovasc Intervent Radiol*, 2006; 29: 669–71
- Spiliopoulos S, Sabharwal T, Karnabatidis D et al: Endovascular treatment of visceral aneurysms and pseudo-aneurysms: Long-term outcomes from a multicenter European study. *Cardiovasc Intervent Radiol*, 2012; 35: 1315–25
- Cope C, Zeit R: Coagulation of aneurysms by direct percutaneous thrombin injection. *Am J Roentgenol*, 1986; 147(2): 383–87
- Barbiero G, Battistel M, Susac A et al: Percutaneous thrombin embolization of a pancreaticoduodenal artery pseudoaneurysm after failing of the endovascular treatment. *World J Radiol*, 2014; 6(8): 629–35
- Ghassemi A, Javit D, Dillon EH: Thrombin injection of a pancreaticoduodenal artery pseudoaneurysm after failed attempts at transcatheter embolization. *J Vasc Surg*, 2006; 43: 618–22
- Ammori BJ, Alexander DJ, Madan M: Haemorrhagic complications of pancreatitis: Presentation, diagnosis and management. *Ann R Coll Surg Eng*, 1998; 80: 316–25
- Balthazar EJ: Complications of acute pancreatitis: Clinical and CT evaluation. *Radiol Clin North Am*, 2002; 40(6): 1211–27
- Boudghène F, L'Herminé C, Bigot JM: Arterial complications of pancreatitis: Diagnostic and therapeutic aspects in 104 cases. *J Vasc Interv Radiol*, 1993; 4(4): 551–58
- White AF, Baum S, Buranasiri S: Aneurysms secondary to pancreatitis. *Am J Roentgenol*, 1976; 127(3): 393–96
- Kim J, Shin JH, Yoon HK et al: Endovascular intervention for management of pancreatitis-related bleeding: A retrospective analysis of thirty-seven patients at a single institution. *Diagn Interv Radiol*, 2015; 21(2): 140–47
- Hyare H, Desigan S, Brookes JA et al: Endovascular management of major arterial hemorrhage as a complication of inflammatory pancreatic disease. *J Vasc Interv Radiol*, 2007; 18: 591–96
- Hsu JT, Yeh CN, Hung CF et al: Management and outcome of bleeding pseudoaneurysm associated with chronic pancreatitis. *BMC Gastroenterol*, 2006; 6: 3
- Okuno A, Miyazaki M, Ito H et al: Nonsurgical management of ruptured pseudoaneurysm in patients with hepatobiliary pancreatic diseases. *Am J Gastroenterol*, 2001; 96: 1067–71

Conclusions

Percutaneous treatment of post-pancreatitis pseudoaneurysms, as an alternative to trans-arterial embolization and to open surgery, is a relatively simple procedure that can be performed without general anesthesia, and it has a good risk-benefit profile.

In our opinion, it can be considered as an alternative to trans-arterial embolization when pseudoaneurysm arises from small vessels, such as the short gastric arteries that cannot be visualized on selective splenic arteriography.

Conflict of interest

The authors have no conflict of interest to disclose.