

## How to deal with an open abdomen?

Jan J. De Waele<sup>1</sup>, Mark Kaplan<sup>2</sup>, Michael Sugrue<sup>3</sup>, Pablo Sibaja<sup>4</sup>, Martin Björck<sup>5</sup>

<sup>1</sup>*Department of Critical Care Medicine, Ghent University Hospital, Ghent, Belgium.*

<sup>2</sup>*Division Trauma and Surgical Critical Care, Albert Einstein Medical Center, Philadelphia PA, USA*

<sup>3</sup>*Department of Surgery, Letterkenny Hospital, Donegal Clinical Research Academy and Galway University Hospital, Ireland*

<sup>4</sup>*Department of Surgery, Surgical Emergency Unit, Hospital México, Costa Rica Social Security Department and University of Costa Rica, postgraduate studies of General Surgery, Costa Rica*

<sup>5</sup>*Department of Surgical Sciences, Vascular Surgery, Uppsala University, Uppsala, Sweden*

### Abstract

Appropriate open abdomen treatment is one of the key elements in the management of patients who require decompressive laparotomy or in whom the abdomen is left open prophylactically. Apart from fluid control and protection from external injury, fluid evacuation and facilitation of early closure are now the goals of open abdomen treatment. Abdominal negative pressure therapy has emerged as the most appropriate method to reach these goals. Especially when combined with strategies that allow progressive approximation of the fascial edges, high closure rates can be obtained. Intra-abdominal pressure measurement can be used to guide the surgical strategy and continued attention to intra-abdominal hypertension is necessary.

This paper reviews recent advances as well as identifying the remaining challenges in patients requiring open abdomen treatment. The new classification system of the open abdomen is an important tool to use when comparing the efficacy of different strategies, as well as different systems of temporary abdominal closure.

**Key words:** open abdomen; laparotomy; damage control; negative pressure therapy

Anestezjologia Intensywna Terapia 2015, tom XLVII, nr 4, 386–392

Open abdomen management — indications, temporary abdominal closure, as well as attitudes and patient management, have changed considerably during the last decade. Due to better insights into intra-abdominal hypertension (IAH) and abdominal compartment syndrome (ACS), increasing experience and improvements in temporary abdominal closure techniques, the outcomes of patients requiring open abdomen management have improved, despite an often increased severity of illness and more underlying abdominal conditions [1].

Open abdomen has always been a surgeon's (and patient's) worst nightmare, mostly because the conditions requiring open abdomen management were difficult to handle from a surgical perspective, often resulting in en-

teroatmospheric fistulae, uncontrolled septic sources and patients with persistent multiple organ dysfunction syndrome (MODS). Recent reports have demonstrated that opening a patient's abdomen and leaving it open no longer means the beginning of a protracted disease leaving the patient with a giant hernia and fistulas requiring complex reconstructive surgery. In this review, we will highlight the recent advances as well as discuss the remaining challenges in patients requiring open abdomen treatment.

### HISTORICAL PERSPECTIVE

When Wendt, as early as 1876, first described the association between raised abdominal pressure and renal impairment, the concept of an open abdomen was con-

Należy cytować wersję: De Waele JJ, Kaplan M, Sugrue M, Sibaja P, Björck M: How to deal with an open abdomen? *Anaesthesiol Intensive Ther* 2015; 47: 372–378. 10.5603/AIT.a2015.0023.

sidered to be medical heresy. While Emerson found that significant rises in intra-abdominal pressure (IAP) caused cardiac failure no physician dreamt of leaving an abdomen open [2]. In the 1940s, Bradley at Massachusetts Memorial Hospital [3] found that increased IAP resulted in a reduction in the renal blood flow in 17 young healthy males, Ogilvie reported what was probably the first open abdomen case [4]. He used gauze soaked in Vaseline as a temporary closure technique. In 1948 Gross advocated an aggressive surgical approach in the treatment of omphalocoel [5].

With the introduction of laparoscopy in the 1960s the hazards of raised IAP were noted in adult patients. In the early 1980s Kron from the University of Virginia introduced the concept of abdominal exploration and decompression to improve outcomes in patients with tense abdomens after surgery [6]. He standardized the measurement of IAP using a urinary catheter. While Pringle had described hepatic packing in 1908 he did not leave the abdomen open [7]; Stone introduced the concept of abbreviated laparotomy and packing in 1983 [8] and this was popularized by Rotondo and Schwab and named damage control [9]. By 1989 Fietsam had, at this stage, coined the term abdominal compartment syndrome [10]. In the 1990s there was an explosion in ACS related research with Sugrue in two large prospective studies showing the causal relationship between IAH and renal failure [11, 12]. Ivatury was one of the first to state that there was a potential survival benefit in prophylactic abdominal decompression [13]. Moreover, the World Society of the Abdominal Compartment Syndrome was formed after the Second World Congress in Noosa, Australia in 2004. The first textbook on ACS was published in 2006. WSACS was in part responsible for changing perceptions and management of a condition that had a mortality over 50% in the 1980s to less than 25% today [1]. The introduction of a consensus classification system of the open abdomen in 2009 was an important step forward to enable comparisons of different cohorts of patients, as well as to guide training [14]. Moreover, there have been great advances in the care of the patients with open abdomen in the last 5 years.

## GOALS IN OPEN ABDOMEN MANAGEMENT

Whereas abdominal cover and avoiding damage to the bowel was the obvious primary goal when open abdomen treatment was initially used, the goals of open abdomen management have significantly changed over the years into a more complex strategy. Fluid control and facilitation of early abdominal closure are two new goals that are now within reach (Table 1). Early closure has become an important tactical goal since most larger cohort studies have shown that serious life-threatening complications occur after two weeks of OA treatment [15]. Apart from fluid control, which prevents recurrent increase in IAP and avoids the accumulation of post-

**Table 1.** Goals of open abdomen management

1. Abdominal cover
Protect bowel from injury
Prevent contamination of abdominal cavity
2. Fluid control
Evacuate residual ascites and postoperative fluids
Avoid recurrent IAH
3. Facilitation of abdominal closure
Avoid lateralization of the abdominal wall musculature
Avoid adhesion between bowels and parietal peritoneum

operative collections, new methods for temporary abdominal closure (TAC) allow for reducing disease severity by further reducing IAP and dampening systemic inflammation, although the latter has so far only been documented in animal models.

Whereas the resulting open abdomen was often impossible to close, and delayed repair of a giant hernia was taken for granted, early delayed abdominal closure is now a realistic option; vacuum assisted wound closure (VAWC), often in combination with some kind of device to prevent lateralization of the bowel wall, results in abdominal closure rates of 80–90% in surviving patients.

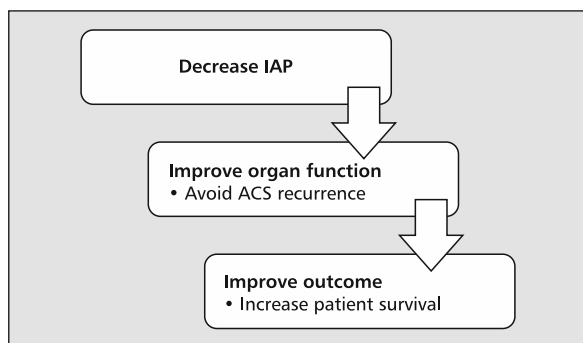
Throughout the course, IAH management remains important, and factors contributing to IAH and ACS should be carefully monitored and prevented proactively. Fluid administration, which is among the main iatrogenic factors of IAH in the critically ill, should be judiciously used in this setting. Continued IAP measurement is of paramount importance, also after abdominal decompression.

In order to advance further in the management of OA it is necessary to develop specific treatment algorithms in different subgroups of patients [16].

## WHEN TO OPEN

Abdominal decompression is considered when IAH is considered the main cause of, or contributor to, organ dysfunction. Typically, IAP is 20–25 mm Hg or higher, and organ dysfunction severe or rapidly deteriorating, with the patient on mechanical ventilation, in shock and expressing oliguria or anuria. An important aspect is that the deterioration in organ function and increase in IAP should be linked in time – this may often be difficult to judge, as the underlying condition may also be responsible for organ dysfunction without any IAH. This is yet another reason to start monitoring IAP early in the course in patients at risk.

This may occur in surgical [postoperative] patients, but also in patients that have not undergone surgery. In the latter, the decision is often deferred, as most surgeons are still reluctant to open an abdomen without any demonstrable resectable disease.



**Figure 1.** Goals of abdominal decompression

The goal of abdominal decompression is to lower IAP, improve organ function and eventually improve patient outcome (Fig. 1). Several studies have documented a profound effect on IAP that is generally in proportion to the increase in IAP before decompression [17]. The effect on organ dysfunction has been described in a number of studies, generally showing a rapid improvement in hemodynamics, respiration and diuresis [18]. So far, however, no adequately powered study to demonstrate an effect on outcomes has been performed.

The effect of decompression depends on other factors such as timing — early decompression is obviously better than decompressing when the patient has been anuric for several days.

Another important consideration is that decompressive laparotomy should only be considered when non-surgical methods have not been successful — except in fulminant ACS with IAPs well above 30–35 mm Hg. Although among these, percutaneous drainage (PCD) e.g. has been found to avoid abdominal decompression in almost 80% of patients [19], other treatment options are also available [20]. It should be acknowledged that in some situations there is not enough time to consider non-surgical measures; for these cases of fulminant ACS abdominal decompression may be life saving.

### TEMPORARY ABDOMINAL CLOSURE

The open abdomen is one of the most important advances in care of the critically ill or injured patients [21]. Successful management of the open abdomen is dependent on controlling IAH, decreasing its systemic effects, and reducing intra-abdominal complications such as fistulas and abdominal wall hernias [22]. The type of temporary abdominal closure is a key element in the management of the open abdomen.

The initial techniques for TAC were static and only contained the abdominal contents. There has been an evolution in the management of the open abdomen with dynamic

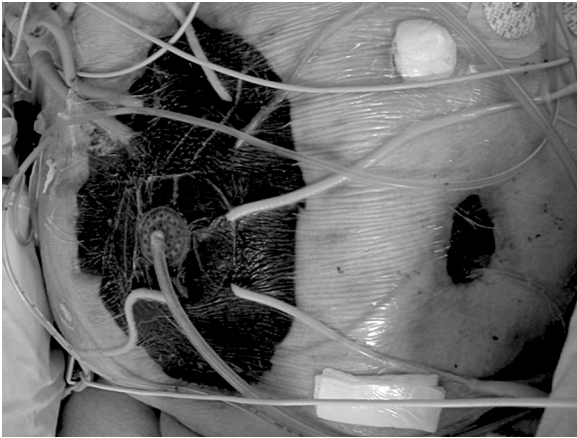
devices that not only control the inflammatory toxic abdominal fluid, but also minimize abdominal wall retraction and improve early closure rates. Studies have shown that control of systemic derangement is imperative in managing the open abdomen [23]. Therefore, TAC should be incorporated in the concept of Total Management of the Opened Abdomen (TMOA). Keys to successful management of the open abdomen include: liberal open abdomen protocols, minimizing IAH, prevention of lateralization of the abdominal wall, decreasing bowel edema, use of early enteral feeding [24], minimizing fistulas, and hernias by early closure.

There are many TAC closure techniques available. The towel clip closure is no longer acceptable because of the high incidence of ACS and skin necrosis. The Bogotá bag, first described in 1984, was designed to contain the abdominal contents using a large plastic bag sewn to the skin. The Bogotá bag was the first technique to allow the abdominal wall to expand and lower the intra-abdominal pressure. There was no control of the toxic intra-abdominal fluid, however. This was associated with a wide variety of complications which include adhesion formation, emergence of enteric fistulas, non-quantified loss of fluids, possibility of evisceration, hemorrhage, contamination by external germs (especially when in proximity to intestinal ostomies), spread of germs into the environment, and a high rate of hernias.

Different methods of TAC have been developed to protect the open abdomen and reduce these complications [25]. As newer devices evolved there — unfortunately — are no randomized controlled trials comparing one form of closure to another. This is due to the heterogeneity of the population and the inability to establish a control technique. There are a number of retrospective studies demonstrating clinical efficacy.

The most commonly used TAC is the Barker VAC Pac technique [26]. This is a “home-made device” that consists of placing a plastic covering over the bowel and placement of suction devices in gauze or surgical towels and applying the system to wall suction. This appeared to improve the function of the Bogotá bag in removing fluid from the abdomen and improving closure rates. Barker in 2000 [26] reported closure rates of 55% using this technique; the enteric fistula rate was 4%. In 2004, Miller *et al.* [27] published a report to examine the success of vacuum-assisted fascial closure (VAFC) under a carefully applied protocol in abdominal closure after open abdomen. It concluded that the use of VAFC under a carefully defined protocol has resulted in significantly higher fascial closure rates, obviating the need for subsequent hernia repair in most patients. The utility of this technique is not limited to the early postoperative period, but it can be successful as much as 3 to 4 weeks after the initial operation.

This technique appeared to be the most effective way of controlling the pathologic process until the application



**Figure 2.** Temporary abdominal closure using negative pressure therapy in a complex patient

of negative pressure in the open abdomen. Negative pressure therapy (NPT) (Fig. 2) allows for more effective drainage of the toxic intra-abdominal fluid, significantly improves closure rates by decreasing abdominal wall retraction, and minimizes complications because of improved closure rates, and reduces bowel edema. Physiologic pressure studies have shown NPT to be effective in extracting fluid from the abdomen because of improved negative pressure distribution when compared to the Barker technique, but not leading to increased rates of enteric fistulas [28, 29]. Frazee *et al.* [30] reported in a retrospective study in comparing ABThera to Barker Vac Pac, ABThera had an 89% closure rate compared to Barker and an odds ratio 7.97 favoring ABThera vs. the Barker technique. A meta-analysis from Roberts *et al.* [31] also showed a benefit of negative pressure therapy when comparing fascial closure techniques. Lower serum lactate levels, improved intra-abdominal pressures, and lower hospital stays were reported in those patients with a negative pressure device vs. a Barker Vac Pac or a Bogotá bag.

In 2010, Kubiak *et al.* [32] hypothesized that peritoneal NPT would reduce systemic inflammation and organ damage. Negative pressure therapy removed a significantly greater volume of ascites than did passive drainage in a porcine experiment. Systemic inflammation (e.g. TNF-1, IL-1, IL-6) was significantly reduced in the NPT group and was associated with significant improvement in intestine, lung, kidney, and liver histopathology. Efficacy was attributed partially due to an attenuation of peritoneal inflammation by the removal of ascites. However, the exact mechanism needs further elucidation.

Two prospective studies have recently added new evidence in this field. Cheatham *et al.* [33] found in a prospective open-label study that NPT compared to the Barker vacuum-pack technique was associated with increased primary fascial closure rates in patients who required OAT

for at least 48h. They also reported lower mortality rates in patients treated with NPT after controlling for several variables. In a small, randomized controlled trial comparing the same techniques as the previous study, Although Kirkpatrick *et al.* [34] could not reproduce the increased primary fascial closure rates [albeit that the study was not powered for this], they did find an improved mortality rate in patients treated with NPT. There was no difference in inflammatory mediators between the two groups.

While the open abdomen technique has been shown to save lives, there are new complications to manage. The method of TAC is a key component in managing a patient with an open abdomen in order to decrease complications and improve clinical outcomes. The best clinical evidence to date suggests that negative pressure therapy has the best outcomes with the highest closure rates, lowest complications including fistula, and mortality when compared to other techniques in different types of patients [35, 36]. While larger studies are needed, the characteristics of NPT seem to match the underlying physiology of the open abdomen. The most important component when using a TAC technique is to develop a definitive plan to manage the open abdomen. Early closure is imperative with the adoption of techniques to minimize the inflammatory response with an overall reduction of IAH.

### COMBINING FASCIAL APPROXIMATION AND NPT — A SOLUTION?

From the very start when an open abdomen treatment is initiated the responsible surgeons and intensivists should have in mind how to close the open abdomen as quickly as possible. Many investigators have reported that the risk of life-threatening complications, in particular of EAF, increase rapidly after two weeks of open abdomen treatment [15]. In Table 2 the problems that need to be addressed during open abdomen are summarized. The introduction of negative pressure therapy with the home-made so called VAC-PAC method was pioneered in Philadelphia [37], and was later developed further into the Abdominal V.A.C system, a commercially available dressing (KCI, San Antonio, TX, USA). This system, also labeled VAWC was associated with high closure rates in cohorts of mostly young trauma victims from the USA [27, 38]. Many researchers who started to use the VAWC system on emergency surgical care patients, often elderly patients suffering from pancreatitis, septic abdomen or vascular catastrophes, found that this system alone was not sufficient to be able to close the abdomen after the often longer periods of treatment with open abdomen that is required in such patients.

Although the VAWC includes a TAC with a non-adhesive layer, preventing the formation of adhesions between the intestines and the bowel wall, the lateralization of the bowel wall

**Table 2.** Problems to address when closing the abdomen (modified from Björck *et al.* [5])

Problem	Action
Prevent adhesions between the intestines and the bowel wall	TAC with a non-adhesive layer
Prevent lateralization of the bowel wall	Apply a device pulling the fascia towards the midline when prolonged treatment is necessary
Prevent loss of fascia and skin	Handle the tissues with care Avoid excessive fluid on skin and desiccation of fascia
Prevent ileus	Early enteral feeding Avoid opioids
Prevent development of EAF	Avoid contact between intestines and suction device or mesh Whenever possible, cover bowel with omentum and bury anastomoses
Prevent malnutrition and impaired healing	Minimize protein loss Optimize nutrition
Prevent mental disorders	Crucial during prolonged treatment

TAC — temporary abdominal closure; EAF — entero-atmospheric fistula

that becomes an increasingly important problem over time, is not prevented with this system. Although several alternative methods to prevent lateralization of the bowel wall have been suggested, there are no randomized studies comparing their efficacy. Thus, we have only results from prospective heterogeneous cohort studies on which to base our knowledge.

One of the oldest described methods of preventing lateralization of the bowel wall is the Wittmann patch [39], a system of non-permeable Velcro patches that has the great advantage of being possible to approximate in the intensive care unit without having to send the patient to the operation room. Although there have been reports on patients suffering enteroatmospheric fistula with this technique, the risk was only 2% in a meta-analysis where 4 studies including 180 patients treated with this technique were included [40].

An alternative method, that includes a permeable Prolene mesh that is sutured to the fascial edges superficially of the Abdominal V.A.C. system protecting the intestines from having contact with the mesh, has been named VAWC and mesh-mediated fascial traction (VAWCM) [41]. This system has been associated with primary delayed fascial closure rates > 85% in different cohorts of emergency surgery patients requiring prolonged treatment with open abdomen [15, 42–45], one of them including > 100 patients [15]. The advantage of this technique seems to be that an effective drainage can be achieved through the permeable mesh, that a forceful tightening of the fascia towards the midline can be achieved. Furthermore, the mesh used is cheap and readily available in most operation rooms, since it is used for elective hernia repair.

A third system for the prevention of lateralization is the abdominal reapproximation anchor (ABRA, Canica, Almonte, Ontario, Canada) system, a series of midline-crossing elastic bands that are surgically inserted through the full thickness of

the abdominal wall, at a distance of approximately 5 cm from the medial fascial margin, and then gradually tensioned to approximate the bowel wall towards the midline. Reports on this technique are mostly single-center with small numbers of patients. Results are nevertheless also promising. In a report from Holland it was possible to close 14/16 (88%) patients with severe peritonitis with this technique [46].

In conclusion different techniques serving to apply tension to the bowel wall in order to prevent lateralization, and allowing gradual approximation to the midline have all shown success in achieving high primary delayed fascial closure rates among patients needing periods of open abdomen treatment longer than 5 days.

## CLASSIFYING THE OPEN ABDOMEN

Patients benefiting from, or even requiring OA treatment in order to survive, are quite heterogeneous. The incidence of ACS varies depending on resuscitation strategies and over time. Thus, one of the main problems in research on OA is that the different cohorts of patients reported on are not comparable. To define the status of the patient in a standardized way, and relate it to treatment strategies, is also of importance for training and continuous learning.

A classification system was developed during a consensus conference, and was published in the *World Journal of Surgery* in 2009 [14]. The classification system is described in Table 3. The system has already been used in many investigations [15, 42, 43, 46–48], and the paper was cited 57 times in March 2015. One of the problems identified with the classification is the definition of fistulae, and it is also felt that the presence of an entero-atmospheric fistula (Grade 3) is a more serious complication to OA treatment than the development of a frozen abdomen, or a laparostomy (Grade 4).



**Table 3.** Classification of the open abdomen [OA] [14]

Grade	Description
1A	Clean OA without adherence between bowel and abdominal wall or fixity [lateralisation of the abdominal wall]
1B	Contaminated OA without adherence/fixity
2A	Clean OA developing adherence/fixity
2B	Contaminated OA developing adherence/fixity
3	OA complicated by fistula formation
4	Frozen OA with adherent/fixated bowel, unable to close surgically, with or without fistula

As a consequence, the classification system is presently undergoing a revision process.

### SYSTEMIC EFFECTS OF NEGATIVE PRESSURE THERAPY

A major consideration in managing the open abdomen is minimizing the systemic effects. While the open abdomen has improved survival rates, significant systemic effects have been noted leading to a complex series of complications. These can range from giant abdominal wall hernias, enteric fistulas, and multisystem organ failure. Studies have shown that the secretion of cytokines in the form of toxic lymph exacerbated by increasing IAP, leads to multi-system organ failure [49]. Control of the secretion and absorption of this fluid can potentially lead to improved outcomes by reducing the local and systemic effects of inflammatory cytokines.

Studies have shown that secretion of intra-abdominal cytokines is a key element in the intra-abdominal response to trauma and sepsis. There have not been adequate devices developed to control the excretion and absorption of toxic cytokines. Kubiak *et al.* [32] showed significant systemic benefits in controlling the systemic uptake in cytokines in swine. By means of a septic reperfusion injury model, using negative pressure therapy in this septic model significantly and systemically lowered inflammatory cytokines in the peritoneum. Tissue histopathology showed preservation of lung and renal parenchyma in those animals receiving negative pressure therapy with a significant survival rate over those animals with passive drainage.

Studies in humans have also shown the benefit of negative pressure therapy. Cheatham *et al.* [50], in a prospective observational study, demonstrated the effectiveness of negative pressure therapy in the open abdomen. Not only were closure rates higher by 2.8 times, but the overall effect was to lower mortality in this complex group by a factor of 4. The authors hypothesized that the improved outcome was due not only to improved closure rates, but a decrease in the overall systemic effects found in patients with open abdomens. These results, in addition to the animal studies, suggest that NPT has a role in the control of the inflammatory response. A recent RCT however could not find any

differences in systemic inflammation between NPT and the Barker Vacuum-pack technique [34].

Future studies should include the analysis of fluid from patients with an open abdomen and correlate it with survival and complications. The goal of treatment in patient with an open abdomen is to minimize IAP with a decrease in the absorption of toxic cytokines. This should lead to a reduction in organ failure and improve long-term mortality rates.

### CONCLUSIONS

In recent years significant advances have been made in open abdomen management. Abdominal NPT has been an important addition to the armamentarium and has contributed to the high fascial closure rates reported in the last two years when combined with a strategy that prevents lateralization of the rectus muscle. Although experimental evidence also suggests that NPT can attenuate systemic inflammation, to date there are no clinical data to support this.

### ACKNOWLEDGEMENTS

1. Financial support and sponsorship: Jan J. De Waele is a Senior Clinical Researcher with the Research Foundation Flanders [Belgium].
2. Conflicts of interest: Jan De Waele has served as a consultant to Smith&Nephew, and Kinetic Concepts Inc. Michael Sugrue has served as a consultant to Smith&Nephew, and Kinetic Concepts Inc. Mark Kaplan has served as a consultant to Kinetic Concepts Inc. For the remaining authors, none were declared.

### References:

1. Cheatham ML, Safcsak K: Is the evolving management of intra-abdominal hypertension and abdominal compartment syndrome improving survival? *Crit Care Med* 2010; 38: 402–407.
2. Emerson H: Intra-abdominal pressures. *Arch Intern Med* 1911; 7: 754–784.
3. Bradley SE, Bradley GP: The effect of increased intra-abdominal pressure on renal function in man. *J Clin Invest* 1947; 26: 1010–1022.
4. Ogilvie WH: The late complications of abdominal war-wounds. *Lancet* 1940; 236: 253–257.
5. Gross RE: A new method for surgical treatment of large omphaloceles. *Surgery* 1948; 24: 277–292.
6. Kron IL, Harman PK, Nolan SP: The measurement of intra-abdominal pressure as a criterion for abdominal re-exploration. *Ann Surg* 1984; 199: 28–30.
7. Pringle JHV: Notes on the arrest of hepatic hemorrhage due to trauma. *Ann Surg* 1908; 48: 541–549.

8. Stone HH, Strom PR, Mullins RJ: Management of the major coagulopathy with onset during laparotomy. *Ann Surg* 1983; 197: 532–535.
9. Rotondo MF, Schwab CW, McGonigal MD et al.: 'Damage control': an approach for improved survival in exsanguinating penetrating abdominal injury. *J Trauma* 1993; 35: 375–382; discussion 382.
10. Fietsam R, Jr., Villalba M, Glover JL, Clark K: Intra-abdominal compartment syndrome as a complication of ruptured abdominal aortic aneurysm repair. *Am Surg* 1989; 55: 396–402.
11. Sugrue M, Jones F, Deane SA, Bishop G, Bauman A, Hillman K: Intra-abdominal hypertension is an independent cause of postoperative renal impairment. *Arch Surg* 1999; 134: 1082–105.
12. Sugrue M, Buist MD, Hourihan F, Deane S, Bauman A, Hillman K: Prospective study of intra-abdominal hypertension and renal function after laparotomy. *Br J Surg* 1995; 82: 235–238.
13. Ivatury RR, Porter JM, Simon RJ, Islam S, John R, Stahl WM: Intra-abdominal hypertension after life-threatening penetrating abdominal trauma: prophylaxis, incidence, and clinical relevance to gastric mucosal pH and abdominal compartment syndrome. *J Trauma* 1998; 44: 1016–1021; discussion 1021.
14. Bjorck M, Bruhin A, Cheatham M et al.: Classification — important step to improve management of patients with an open abdomen. *World J Surg* 2009; 33: 1154–1157. doi: 10.1007/s00268-009-9996-3.
15. Acosta S, Bjarnason T, Petersson U et al.: Multicentre prospective study of fascial closure rate after open abdomen with vacuum and mesh-mediated fascial traction. *Br J Surg* 2011; 98: 735–743. doi: 10.1002/bjs.7383.
16. Bjorck M, Wanhainen A: Management of abdominal compartment syndrome and the open abdomen. *Eur J Vasc Endovasc Surg* 2014; 47: 279–287. doi: 10.1016/j.ejvs.2013.12.014.
17. De Waele JJ, Hoste EA, Malbrain ML: Decompressive laparotomy for abdominal compartment syndrome — a critical analysis. *Crit Care* 2006; 10: R51.
18. De Waele J, Desender L, De Laet I, Ceelen W, Pattyn P, Hoste E: Abdominal decompression for abdominal compartment syndrome in critically ill patients: a retrospective study. *Acta Clin Belg* 2010; 65: 399–403.
19. Cheatham ML, Safcsak K: Percutaneous catheter decompression in the treatment of elevated intraabdominal pressure. *Chest* 2011; 140: 1428–1435. doi: 10.1378/chest.10-2789.
20. De Keulenaer BL, De Waele JJ, Malbrain ML: Nonoperative management of intra-abdominal hypertension and abdominal compartment syndrome: evolving concepts. *Am Surg* 2011; 77 (Suppl 1): S34–S41.
21. Ivatury RR: Update on open abdomen management: achievements and challenges. *World J Surg* 2009; 33: 1150–1153. doi: 10.1007/s00268-009-0005-7.
22. De Waele JJ, Leppaniemi AK: Temporary abdominal closure techniques. *Am Surg* 2011; 77 (Suppl 1): S46–S50.
23. Vidal MG, Ruiz Weissner J, Gonzalez F et al.: Incidence and clinical effects of intra-abdominal hypertension in critically ill patients. *Crit Care Med* 2008; 36: 1823–1831. doi: 10.1097/CCM.0b013e31817c7a4d.
24. Burlew CC, Moore EE, Cuschieri J et al.: Who should we feed? A Western Trauma Association multi-institutional study of enteral nutrition in the open abdomen after injury. *J Trauma Acute Care Surg* 2012; 73: 1380–1387; discussion 1387–1388. doi: 10.1097/TA.0b013e318259924c.
25. Campbell A, Chang M, Fabian T et al.: Management of the open abdomen: from initial operation to definitive closure. *Am Surg* 2009; 75: S1–22.
26. Barker DE, Kaufman HJ, Smith LA, Ciraulo DL, Richart CL, Burns RP: Vacuum pack technique of temporary abdominal closure: a 7-year experience with 112 patients. *J Trauma* 2000; 48: 201–206; discussion 206.
27. Miller PR, Meredith JW, Johnson JC, Chang MC: Prospective evaluation of vacuum-assisted fascial closure after open abdomen: planned ventral hernia rate is substantially reduced. *Ann Surg* 2004; 239: 608–614; discussion 614.
28. Shaikh IA, Ballard-Wilson A, Yalamarthi S, Amin AI: Use of topical negative pressure in assisted abdominal closure does not lead to high incidence of enteric fistulae. *Colorectal Dis* 2010; 12: 931–934. doi: 10.1111/j.1463-1318.2009.01929.x.
29. Carlson GL, Patrick H, Amin AI et al.: Management of the open abdomen: a national study of clinical outcome and safety of negative pressure wound therapy. *Ann Surg* 2013; 257: 1154–1159. doi: 10.1097/SLA.0b013e31828b8bc8.
30. Frazee RC, Abernathy SW, Jupiter DC et al.: Are commercial negative pressure systems worth the cost in open abdomen management? *J Am Coll Surg* 2013; 216: 730–733. discussion 733–735. doi: 10.1016/j.jamcollsurg.2012.12.035.
31. Roberts DJ, Zygun DA, Grendar J et al.: Negative-pressure wound therapy for critically ill adults with open abdominal wounds: a systematic review. *J Trauma Acute Care Surg* 2012; 73: 629–639.
32. Kubiak BD, Albert SP, Gatto LA et al.: Peritoneal negative pressure therapy prevents multiple organ injury in a chronic porcine sepsis and ischemia/reperfusion model. *Shock* 2010; 34: 525–534. doi: 10.1097/SHK.0b013e3181e14cd2.
33. Cheatham ML, Demetriades D, Fabian TC et al.: Prospective study examining clinical outcomes associated with a negative pressure wound therapy system and Barker's vacuum packing technique. *World J Surg* 2013; 37: 2018–2030. doi: 10.1007/s00268-013-2080-z.
34. Kirkpatrick AW, Roberts DJ, Faris PD et al.: Active negative pressure peritoneal therapy after abbreviated laparotomy: the intraperitoneal vacuum randomized controlled trial. *Ann Surg* 2014 ahead of print. doi: 10.1097/SLA.0000000000001095.
35. Ateama JJ, Gans SL, Boermeester MA: Systematic review and meta-analysis of the open abdomen and temporary abdominal closure techniques in non-trauma patients. *World J Surg* 2015; 39: 912–925. doi: 10.1007/s00268-014-2883-6.
36. Bruhin A, Ferreira F, Chariker M, Smith J, Runkel N: Systematic review and evidence based recommendations for the use of negative pressure wound therapy in the open abdomen. *Int J Surg* 2014; 12: 1105–1114. doi: 10.1016/j.ijssu.2014.08.396.
37. Brock WB, Barker DE, Burns RP: Temporary closure of open abdominal wounds: the vacuum pack. *Am Surg* 1995; 61: 30–35.
38. Suliburk JW, Ware DN, Balogh Z et al.: Vacuum-assisted wound closure achieves early fascial closure of open abdomens after severe trauma. *J Trauma* 2003; 55: 1155–1160; discussion 1160.
39. Wittmann DH, Aprahamian C, Bergstein JM: Etappenlavage: advanced diffuse peritonitis managed by planned multiple laparotomies utilizing zippers, slide fastener, and Velcro analogue for temporary abdominal closure. *World J Surg* 1990; 14: 218–226.
40. Boele van Hensbroek P, Wind J, Dijkgraaf MG, Busch OR, Carel Goslings J: Temporary closure of the open abdomen: a systematic review on delayed primary fascial closure in patients with an open abdomen. *World J Surg* 2009; 33: 199–207. doi: 10.1007/s00268-008-9867-3.
41. Petersson U, Acosta S, Bjorck M: Vacuum-assisted wound closure and mesh-mediated fascial traction — a novel technique for late closure of the open abdomen. *World J Surg* 2007; 31: 2133–2137.
42. Rasilainen SK, Mentula PJ, Leppaniemi AK: Vacuum and mesh-mediated fascial traction for primary closure of the open abdomen in critically ill surgical patients. *Br J Surg* 2012; 99: 1725–1732. doi: 10.1002/bjs.8914.
43. Seternes A, Myhre HO, Dahl T: Early results after treatment of open abdomen after aortic surgery with mesh traction and vacuum-assisted wound closure. *Eur J Vasc Endovasc Surg* 2010; 40: 60–64. doi: 10.1016/j.ejvs.2010.02.018.
44. Ferreira F, Barbosa E, Guerreiro E, Fraga GP, Nascimento Jr B, Rizoli S: Sequential closure of the abdominal wall with continuous fascia traction (using mesh or suture) and negative pressure therapy. *Rev Col Bras Cir* 2013; 40: 85–89.
45. Willms A, Gusgen C, Schaafs B, Bieler D, von Websky M, Schwab R: Management of the open abdomen using vacuum-assisted wound closure and mesh-mediated fascial traction. *Langenbecks Arch Surg* 2015; 400: 91–99. doi: 10.1007/s00423-014-1240-4.
46. Verdant FJ, Dolmans DE, Loos MJ et al.: Delayed primary closure of the septic open abdomen with a dynamic closure system. *World J Surg* 2011; 35: 2348–2355. doi: 10.1007/s00268-011-1210-8.
47. D'Hondt M, Devriendt D, Van Rooy F et al.: Treatment of small-bowel fistulae in the open abdomen with topical negative-pressure therapy. *Am J Surg* 2011; 202: e20–e24. doi: 10.1016/j.amjsurg.2010.06.025.
48. Sorelius K, Wanhainen A, Acosta S, Svensson M, Djavani-Gidlund K, Bjorck M: Open abdomen treatment after aortic aneurysm repair with vacuum-assisted wound closure and mesh-mediated fascial traction. *Eur J Vasc Endovasc Surg* 2013; 45: 588–594. doi: 10.1016/j.ejvs.2013.01.041.
49. Deitch EA: Gut-origin sepsis: evolution of a concept. *Surgeon* 2012; 10: 350–356. doi: 10.1016/j.surge.2012.03.003.
50. Cheatham ML, Demetriades D, Fabian TC et al.: A prospective study examining clinical outcomes associated with a negative pressure wound therapy system and Barker's vacuum packing technique. *World J Surg* 2013; 37: 2018–2030. doi: 10.1007/s00268-013-2080-z.
51. Bjorck M, D'Amours SK, Hamilton AE: Closure of the open abdomen. *Am Surg* 2011; 77: S58–S61.

**Corresponding author:**

Prof. Jan J. De Waele  
 Department of Critical Care Medicine  
 Ghent University Hospital  
 De Pintelaan 185  
 9000 Gent, Belgium  
 e-mail: Jan.DeWaele@UGent.be

Received: 6.04.2015

Accepted: 4.05.2015