

Randomized, comparative study of the effectiveness of three different techniques of interscalene brachial plexus block using 0.5% ropivacaine for shoulder arthroscopy

Michał Kolny¹, Michał J. Stasiowski², Marek Zuber¹, Radosław Marciniak², Ewa Chabierska¹, Aleksandra Pluta², Przemysław Jałowicki², Tomasz Byrczek²

¹Department of Anaesthesia, Endoscopic Surgery Clinic "Sport-Klinika", Żory, Poland

²Department of Anaesthesiology and Intensive Therapy, School of Medicine with the Division of Dentistry in Zabrze, Medical University of Silesia, Katowice, Poland, St. Barbara's Memorial Hospital WSS no. 5 Trauma Centre, Sosnowiec, Poland

Abstract

Background: Interscalene brachial plexus block is an effective regional anesthesia technique for shoulder surgeries. The superiority of the popular ultrasound-guided blocks over peripheral nerve stimulator-confirmed blocks remains unclear. In this study the efficacy of these different block techniques was compared.

Methods: This prospective, randomized, clinical study included 109 patients (ASA grades I–III) who receive 20 mL 0.5% ropivacaine with ultrasound-guided blocks (U group), peripheral nerve stimulator-confirmed blocks (N group), or ultrasound-guided and peripheral nerve stimulator-confirmed blocks (dual guidance; NU group) for elective shoulder arthroscopy. Block onset time, duration, and effectiveness on the Lovett rating scale were assessed.

Results: There was no statistically significant intergroup difference in duration of block performance, irrespective of the technique ($P = 0.232$). Onset time of complete warmth sensation loss ($P < 0.001$) and muscle strength abolition ($P < 0.001$) was significantly longer and mean Lovett rating scale score distribution was significantly higher in the N group than in the other groups ($P < 0.001$). These findings show a statistically significant correlation between the performance of the used block technique and the necessity of conversion to general anesthesia because of insufficient block in the N group (58.54%) than in the U (24.44%) and NU (19.57%) groups.

Conclusions: Peripheral nerve stimulator-confirmed needle placement is not necessary to ensure effectiveness of ultrasound-guided blocks, which is expressed as a lack of necessity of conversion to general anesthesia. Nevertheless, the dual guidance technique is recommended to reduce the risk of complications and might be considered the regional anesthesia of choice for shoulder surgery.

Anestezjologia Intensywna Terapia 2017, tom 49, nr 1, 51–56

Key words: brachial plexus; interscalene brachial plexus block; local anaesthetic; Lovett's Rating Scale; ultrasound; peripheral nerve stimulator

Interscalene brachial plexus block (IBPB) is a well-described and efficient method of regional anesthesia for surgery in the shoulder region [1]. The brachial plexus (BP) originates from the C5–Th1 roots and consists of three trunks: upper (C5–C6), middle (C7), and lower (C8–Th1). The BP is placed between the anterior and middle scalene muscles, about 2

cm below the skin. This location makes it easily accessible for regional anesthesia. IBPB is usually performed lateral to the sternocleidomastoid muscle at the level of the C5–C6 nerve roots or at the level of the cricoid cartilage located in the groove between the anterior and middle scalene muscles [2, 3]. Traditionally, regional blocks are performed with

Należy cytować wersję: Kolny M, Stasiowski MJ, Zuber M. et al. Randomized, comparative study of the effectiveness of three different techniques of interscalene brachial plexus block using 0.5% ropivacaine for shoulder arthroscopy. *Anaesthesiol Intensive Ther.* 2017, vol. 49, no 1, 47–52. doi: 10.5603/AIT.2017.0009.

paresthesia or with a peripheral nerve stimulator (PNS) [4]. Recently, ultrasound guidance during nerve block has become an increasingly popular procedure [5]. In particular, the possibility of continuously observing the end of the needle and visualizing the spread of a local anaesthetic (LA) on a monitor can enhance the safety and efficacy of blocks. Some studies have shown that the possibility of reduction of LA dose was higher with an ultrasound-guided technique rather than a neurostimulation-guided technique [6, 7]. Moreover, the reduction of complications like intravascular injections of cardiotoxic and neurotoxic LAs or brachial plexopathy becomes possible because of the availability of Doppler-color visualization during IBPB; this is not possible using a PNS-confirmed technique [8, 9]. Finally, unlike general anesthesia, IBPB produces relevant analgesia in the postoperative period [10, 11].

However, not many studies have compared the efficacy of regional anesthesia with PNS vs. ultrasound-guided techniques in terms of needle placement precision [12, 13]. A dual-guidance method (US-guided and PNS-confirmed) is the contemporary technique of choice; however, more studies are required on the possible complications arising from the dual-guidance method as compared to the PNS-confirmed technique [14].

The current study was performed to compare the efficacy of three different techniques of IBPB: (1) IBPB with PNS confirmation was performed in group N; (2) IBPB with ultrasound guidance was performed in group U; and (3) IBPB with ultrasound guidance and PNS confirmation (dual guidance) was performed in group NU. In all cases, 20 mL of 0.5% ropivacaine was used for IBPB. Ropivacaine is a bupivacaine homologue with less cardiotoxic properties, which makes it the LA of choice for many anaesthesiologists.

METHODS

The prospective, randomized, clinical study was approved by the Bioethics Committee of Silesian University of Medicine in Katowice. Data were obtained from 109 patients with American Society of Anesthesiologists (ASA) grades I–III, who underwent elective shoulder arthroscopy. Patients aged 18–60 years, who gave written informed consent, were randomly allocated to one of three groups (N, U, or NU) by using the sealed envelopes method. Each group underwent IBPB with a different technique. All blocks were performed using 0.5% ropivacaine (Ropimol, Molteni Farmaceutici, Italy). Exclusion criteria were as follows: neurological deficit in the upper arm, allergies to amide LAs, coagulopathy, pregnancy, and withdrawal of formerly given written consent. After the block was performed, duration, onset time, and block effectiveness according to the modified Lovett rating scale (LRS) were studied. When insufficient block occurred, conversion to general anesthesia was performed.

On the morning of surgery, patients were premedicated with 7.5 mg oral midazolam. In the operation room, venous access was placed and 500 mL of crystalloid was infused. All patients received 0.1 mg of fentanyl intravenously to improve comfort during regional anesthesia. Patients' heart rate, oxygen saturation of arterial blood haemoglobin, non-invasive systolic, diastolic and mean arterial pressure, and electrocardiogram were continuously monitored. Data were recorded with a 5-min sampling time in the anesthetic protocol.

In the N group, all blocks were carried out using Meier's modification (needle insertion point was at the level of the thyroid cartilage), and the needle was led at a 30° angle towards the middle part of the clavicle; this modification is known to be as safe and more efficient than the traditional Winnie access [15]. The procedure was started with palpation examination of the scalene muscles in the medial neck triangle and the interscalene groove lying between them. Palpation time was included in the regional block time. After skin sterilization, local anesthesia was performed using 1 mL of 1% lidocaine solution. IBPB was performed using a Contiplex D set (Contiplex D, B. Braun, Germany) connected to a nerve stimulator (Stimuplex HNS12, B. Braun). At the beginning of stimulation, stimulator settings were set as follows: current, 1 mA; impulse time duration, 0.1 ms; and impulse frequency, 2 Hz and they were reduced to 0.3 mA when disappearance of motor response of either the pectoral muscles or the triceps or biceps brachii was considered to indicate proper needle placement at 0.3 mA to rule out intraneural needle placement. Subsequently, 20 mL of 0.5% ropivacaine was administered. A catheter was placed in the region of the anaesthetized BP for postoperative pain treatment with continuous infusion of 0.2% ropivacaine.

In the U group, BP roots were visualized using an ultrasound system (Sonosite M-Turbo, Sonosite) equipped with a 13-MHz linear probe (MicroMaxx HFL38/13-6 MHz, Sonosite). The procedure was initiated with a precise ultrasonographic scan of the lateral neck triangle. Examination time was included in the IBPB time. After skin sterilization, local anesthesia was performed using 1 mL of 1% lidocaine solution. The ultrasound transducer was covered using a sterile cover (Safersonic Conti, Safersonic) and was used together with a sterile hypoallergenic transmission gel (Aquasonic 100, Parker). IBPB was performed using a Contiplex D set (Contiplex D, B. Braun) applying an out-of-plane technique similar to that used in group N. Ultrasound guidance was used to ensure proper needle placement, which was followed by the administration of 20 mL of 0.5% ropivacaine. The spread of the LA around the nerve roots was observed on the ultrasound monitor; subsequently, a catheter was placed for continuous infusion of 0.2 % ropivacaine.

In the NU group, IBPB was performed in a manner similar to that in group U, but the needle was attached to a PNS set

as in group N. In this group, the placement of the needle was confirmed in two ways — visually and by electrostimulation (dual guidance). IBPB time was calculated until the end of the 0.5% ropivacaine injection. Time of catheter placement was calculated from the end of LA administration until the end of sterile catheter dressing placement.

All blocks were performed by experienced anesthesiologists already skilled in both techniques (over 10 years of experience in all IBPB techniques used in the study) w. IBPB's effectiveness and onset times were assessed by anesthesiologists who were unaware of the patients' group allocations and who did not perform the IBPBs in this study. Sensory block examinations were performed at 5-min intervals by using ethanol-sprayed woolen swabs and 22G needle pinpricks. Motor block examinations were performed according to the modified LRS (6: normal muscular force; 5: slightly reduced muscular force; 4: pronounced reduction of muscular force; 3: slightly impaired mobility; 2: pronounced mobility impairment; 1: almost complete paralysis; and 0: complete paralysis) as an indicator of surgical readiness. IBPB duration was calculated as the time interval from satisfactory sensory block until the very first pain perception requiring infusion of LA via the catheter placed in the region of the BP roots.

In the operating room, patients were assisted by anesthesiologists who were not involved in the study. Their role was to administer proper sedation by continuous intravenous infusion of propofol or single doses of intravenous midazolam. In the case of pain perception during surgery, conversion to general anaesthesia was performed. Such cases were labeled as incomplete blocks.

STATISTICAL ANALYSIS

Calculations were done using Statistica 12 (StatSoft, Tulsa, USA) software. All analyzed groups were assessed using the Shapiro-Wilk test for estimating normal distributions. Because most of the distributions were not normal, non-parametric tests were used for statistical analysis. For univariate analysis, the Kruskal–Wallis test and Pearson's χ^2 test were performed. Statistical significance was set at $P < 0.05$. Q_1, Q_2 and Q_3 are respectively lower quartile, median and upper quartile.

RESULTS

Patients included in this study did not differ significantly with respect to sex, height, and weight, and time of the surgery was comparable in all groups. Our study demonstrated that there was no statistically significant difference between the duration of IBPB performance regardless of the technique used (Fig. 1). Onset time of complete warmth sensation loss (minutes) was significantly longer in the N group than in the U and NU groups ($P < 0.001$). The onset time of complete pinprick sensation loss was significantly longer in the N than in the U and NU groups ($P < 0.001$). The

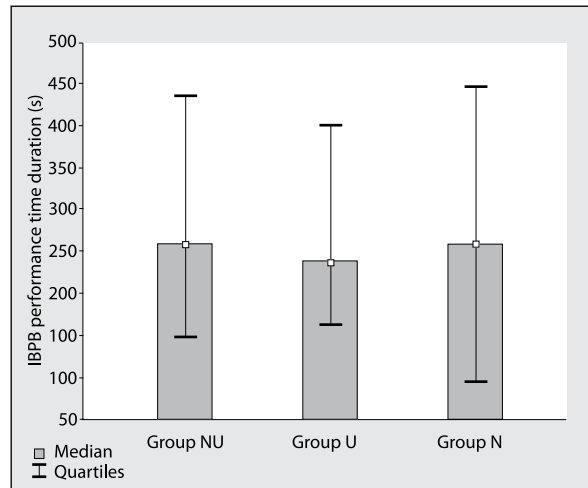


Figure 1. Duration of interscalene brachial plexus block performance (median and quartiles) in the three groups. NU — interscalene brachial plexus block with ultrasound guidance and peripheral nerve stimulator confirmation; U — interscalene brachial plexus block with ultrasound guidance; N — interscalene brachial plexus block with peripheral nerve stimulator confirmation

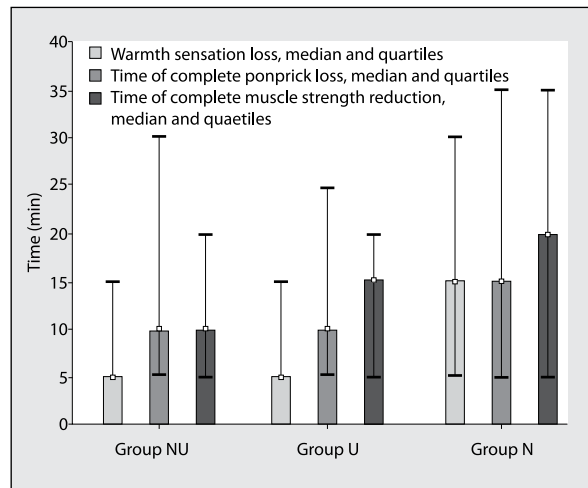


Figure 2. Median and quartiles of time of warmth sensation loss, complete pinprick sensation loss, and muscle strength abolition in the three groups. N — interscalene brachial plexus block with peripheral nerve stimulator confirmation; NU — interscalene brachial plexus block with ultrasound guidance and peripheral nerve stimulator confirmation; U — interscalene brachial plexus block with ultrasound guidance

onset time of complete abolition of muscle strength also was statistically longer in the N group than in the U and NU groups ($P < 0.001$) (Fig. 2).

In the NU and U groups, we noticed an asymmetry of distribution for low numbers in LRS. In the N group, the asymmetry of distribution slightly tended towards higher numbers in LRS and distribution of LRS is flatter which indicates wider differentiation around the expected value of LRS (Fig. 3).

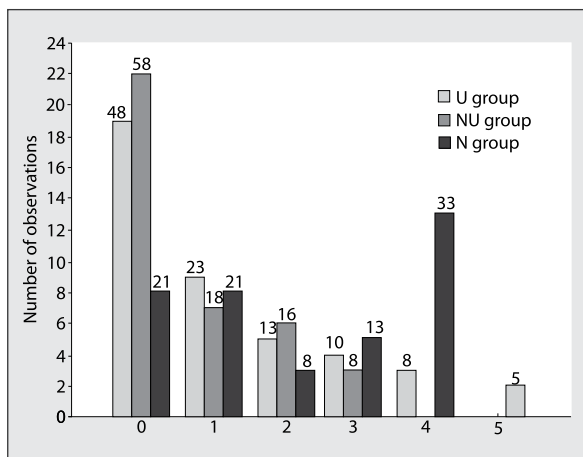


Figure 3. Quality of complete motor block number for number of observations in 6 categories (LRS) for the U (interscalene brachial plexus block with ultrasound guidance), NU (interscalene brachial plexus block with ultrasound guidance and peripheral nerve stimulator confirmation), and N (interscalene brachial plexus block with peripheral nerve stimulator confirmation) groups

In the U group, 80.43% of the patients did not require conversion to general anesthesia as the performed IBPB was sufficient for surgery. Similarly, in the NU group, 75.56% of the patients did not require conversion to general anesthesia. In the N group, however, only 41.46% of the patients were operated under IBPB; the rest of the patients had to undergo general anesthesia because of insufficient intraoperative analgesia. Chi square analysis ($P = 0.0002$) showed a statistically significant correlation between the IBPB technique and necessity of conversion to general anesthesia because of insufficient plexus block (Fig. 4).

DISCUSSION

IBPB is a well-known technique of regional anesthesia for upper arm surgery, especially in the shoulder region. This prospective, randomized study shows that time needed for IBPB performance did not differ regardless of technique used, which was contrary to the finding of Taboada *et al.* [16] who found that ultrasound guidance shortens the time of IBPB performance. In our study, the addition of ultrasound guidance did not prolong the time of the procedure performed by experienced operators, which is especially important in ambulatory, commercial anesthesia. Moreover, excluding PNS assistance did not lead to shorter time of IBPB performance; therefore, shelving nerve stimulators is not necessary.

In this study, the onset time of complete warmth sensation loss, pinprick sensation loss, and abolition of muscle strength was significantly longer in the N group than in the U and NU groups. At the time of surgery, LRS scores were statistically higher in the N group than in the other groups. These

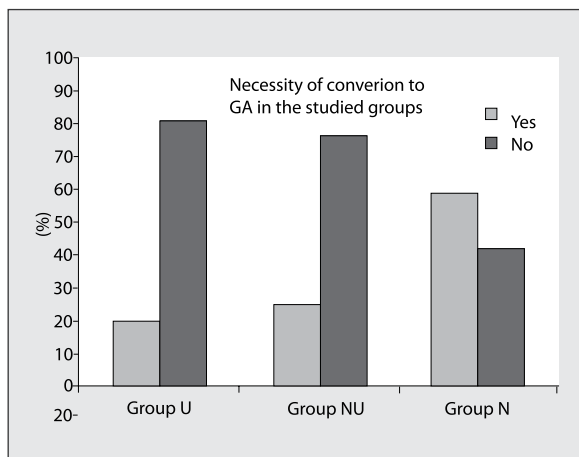


Figure 4. Necessity of conversion to general anesthesia in the U (interscalene brachial plexus block with ultrasound guidance), NU (interscalene brachial plexus block with ultrasound guidance and peripheral nerve stimulator confirmation), and N (interscalene brachial plexus block with peripheral nerve stimulator confirmation) groups

findings are in contrast to those of Liu *et al.* [17] and Taboada *et al.* [16] who found no differences in the abovementioned categories between their study groups. Giancesello *et al.* [7] also found similar block onset times in their study groups, but their patients received ultrasound-guided IBPBs with 20 mL of 0.5% levobupivacaine HCl and PNS-confirmed IBPBs with 40 mL of 0.5% levobupivacaine HCl.

Our findings also show that the addition of ultrasound guidance to PNS confirmation for BP identification increased the success rates of full sensorimotor IBPB effectiveness to 80%, which was almost double the success rate of 41% for IBPBs performed solely with PNS confirmation. These findings are similar to those of Kapral *et al.* [18], who obtained 98% and 91% effective IBPBs with dual guidance and PNS confirmation alone, respectively, by administering 20 mL of 0.75% ropivacaine for trauma-related upper arm surgery. In contrast, Mejía-Terrazas *et al.* [19] observed no difference in success rates between IBPBs performed with PNS assistance or ultrasound guidance. A similar observation was made by Liu *et al.* who found both techniques comparably effective; however, they also found that ultrasound guidance reduced the number of needle passes required to perform sufficient IBPB [17]. Lang *et al.* [20] proved that all 50 patients in their study receiving ultrasound-guided and PNS-confirmed IBPB achieved complete block after 20 min [20]. Unfortunately, they had no control group. Plante *et al.* [21] also reported 96% success rates for US-guided complete IBPBs with C6 and C5 level injections.

The major finding of our study is that excluding PNS assistance does not lower the effectiveness of blockade, because 75.56% of patients who received IBPBs under

ultrasound guidance alone were ready for surgery under regional anesthesia of the interscalene BP only, which was lower than the 80.43% of patients who received IBPBs using dual guidance. A similar observation was made by Yu *et al.* [22] who obtained 98% effective blocks after patients received ultrasound-guided blocks without PNS confirmation of needle placement; however, they did not have a control group either. Sinha *et al.* [23] had comparable findings. They quantified the motor response after ultrasound-guided needle placement for IBPB and observed that motor response below or above 0.5 mA had no impact on the success or duration of upper trunk block. Their conclusion was similar to that of our study, i.e., PNS confirmation of ultrasound-guided needle placement does not influence the success rate of IBPB.

In a majority of studies, ultrasound guidance tends to be superior to PNS assistance for IBPB. Compared to PNS assistance, ultrasound guidance leads to faster onset time of IBPB, lowers the rate of conversions to general anesthesia, and improves LRS scores. IBPB effectiveness also differs according to the performer's experience, technique of neurostimulation, opening injection pressure, volume of LA used, spread of LA, and pattern of nerve roots.

CONCLUSIONS

PNS confirmation of needle placement is no longer a necessity in terms of effectiveness of IBPBs performed under ultrasound guidance, as evidenced by the low rate of conversion to general anesthesia in this study. Nevertheless, the use of dual guidance is still recommended because it might reduce the risk of intraneural injection of LAs and help identify the BP location under difficult sonographic conditions, or in patients with anatomical variations, like for example presence of an scalenus minimum muscle might hinder the spreading of local anesthetic while using nerve stimulation technique only. IBPB under dual guidance (ultrasound guidance and PNS confirmation) should be considered the regional anesthesia of choice for shoulder surgery.

ACKNOWLEDGEMENTS

1. Source of founding: none.
2. Conflict of interests: none.

Piśmiennictwo:

1. Tetzlaff JE, Yoon HJ, Brems J. Interscalene brachial plexus block for shoulder surgery. *Reg Anesth.* 1994; 19(5): 339–343.
2. Winnie AP. Interscalene brachial plexus block. *Anesth Analg.* 1970; 49(3): 455–466, indexed in Pubmed: [5534420](#).
3. Burckett-St Laurent D, Chan V, Chin KJ. Refining the ultrasound-guided interscalene brachial plexus block: the superior trunk approach. *Can J Anaesth.* 2014; 61(12): 1098–1102, doi: [10.1007/s12630-014-0237-3](#), indexed in Pubmed: [25208976](#).

4. Denny NM, Harrop-Griffiths W. Location, location, location! Ultrasound imaging in regional anaesthesia. *Br J Anaesth.* 2005; 94(1): 1–3, doi: [10.1093/bja/aei001](#), indexed in Pubmed: [15583209](#).
5. Yang WT, Chui PT, Metreweli C. Anatomy of the normal brachial plexus revealed by sonography and the role of sonographic guidance in anesthesia of the brachial plexus. *AJR Am J Roentgenol.* 1998; 171(6): 1631–1636, doi: [10.2214/ajr.171.6.9843302](#), indexed in Pubmed: [9843302](#).
6. Takeda A, Ferraro LH, Rezende AH, et al. Minimum effective concentration of bupivacaine for axillary brachial plexus block guided by ultrasound. *Braz J Anesthesiol.* 2015; 65(3): 163–169, doi: [10.1016/j.bjane.2013.11.007](#), indexed in Pubmed: [25925026](#).
7. Giancesello L, Magherini M, Pavoni V, et al. The influence of interscalene block technique on adverse hemodynamic events. *J Anesth.* 2014; 28(3): 407–412, doi: [10.1007/s00540-013-1748-8](#), indexed in Pubmed: [24258467](#).
8. Avellanet M, Sala-Blanch X, Rodrigo L, et al. Permanent upper trunk plexopathy after interscalene brachial plexus block. *J Clin Monit Comput.* 2016; 30(1): 51–54, doi: [10.1007/s10877-015-9681-z](#), indexed in Pubmed: [25744163](#).
9. Baciarello M, Danelli G, Fanelli G. Real-time ultrasound visualization of intravascular injection of local anesthetic during a peripheral nerve block. *Reg Anesth Pain Med.* 2009; 34(3): 278–279, doi: [10.1097/AAP.0b013e31819aabb1](#), indexed in Pubmed: [19436189](#).
10. Kim JY, Song KS, Kim WJ, et al. Analgesic efficacy of two interscalene blocks and one cervical epidural block in arthroscopic rotator cuff repair. *Knee Surg Sports Traumatol Arthrosc.* 2016; 24(3): 931–939, doi: [10.1007/s00167-015-3667-8](#), indexed in Pubmed: [26063452](#).
11. Park SK, Choi YS, Choi SW, et al. A comparison of three methods for postoperative pain control in patients undergoing arthroscopic shoulder surgery. *Korean J Pain.* 2015; 28(1): 45–51, doi: [10.3344/kjp.2015.28.1.45](#), indexed in Pubmed: [25589946](#).
12. Gadsden JC, Choi JJ, Lin E, et al. Opening injection pressure consistently detects needle-nerve contact during ultrasound-guided interscalene brachial plexus block. *Anesthesiology.* 2014; 120(5): 1246–1253, doi: [10.1097/ALN.0000000000000133](#), indexed in Pubmed: [24413417](#).
13. Albrecht E, Kirkham KR, Taffé P, et al. The maximum effective needle-to-nerve distance for ultrasound-guided interscalene block: an exploratory study. *Reg Anesth Pain Med.* 2014; 39(1): 56–60, doi: [10.1097/AAP.0000000000000034](#), indexed in Pubmed: [24310046](#).
14. Abrahams MS, Aziz MF, Fu RF, et al. Ultrasound guidance compared with electrical neurostimulation for peripheral nerve block: a systematic review and meta-analysis of randomized controlled trials. *Br J Anaesth.* 2009; 102(3): 408–417, doi: [10.1093/bja/aen384](#), indexed in Pubmed: [19174373](#).
15. Meier G, Bauereis C, Maurer H, Meier T. [Interscalene plexus block. Anatomic requirements — anesthesiologic and operative aspects]. *Anaesthesist.* 2001; 50(5): 333–341.
16. Taboada M, Rodríguez J, Amor M, et al. Is ultrasound guidance superior to conventional nerve stimulation for coracoid infraclavicular brachial plexus block? *Reg Anesth Pain Med.* 2009; 34(4): 357–360, doi: [10.1097/AAP.0b013e3181ac7c19](#), indexed in Pubmed: [19574869](#).
17. Liu SS, Zayas VM, Gordon MA, et al. A prospective, randomized, controlled trial comparing ultrasound versus nerve stimulator guidance for interscalene block for ambulatory shoulder surgery for postoperative neurological symptoms. *Anesth Analg.* 2009; 109(1): 265–271, doi: [10.1213/ane.0b013e3181a3272c](#), indexed in Pubmed: [19535720](#).
18. Kapral S, Greher M, Huber G, et al. Ultrasonographic guidance improves the success rate of interscalene brachial plexus block. *Reg Anesth Pain Med.* 2008; 33(3): 253–258, doi: [10.1016/j.rapm.2007.10.011](#), indexed in Pubmed: [18433677](#).
19. Mejía-Terrazas GE, Ruiz-Suárez M, Gaspar-Carrillo SP, et al. [Interscalene block for total shoulder arthroplasty: comparative study (ultrasound vs. neurostimulation)]. *Cir Cir.* 2014; 82(4): 381–388, indexed in Pubmed: [25167348](#).
20. Lang RS, Kentor ML, Vallejo M, et al. The impact of local anesthetic distribution on block onset in ultrasound-guided interscalene block.

- Acta Anaesthesiol Scand. 2012; 56(9): 1146–1151, doi: [10.1111/j.1399-6576.2012.02745.x](https://doi.org/10.1111/j.1399-6576.2012.02745.x), indexed in Pubmed: [22845687](https://pubmed.ncbi.nlm.nih.gov/22845687/).
21. Plante T, Rontes O, Bloc S, et al. Spread of local anesthetic during an ultrasound-guided interscalene block: does the injection site influence diffusion? Acta Anaesthesiol Scand. 2011; 55(6): 664–669, doi: [10.1111/j.1399-6576.2011.02449.x](https://doi.org/10.1111/j.1399-6576.2011.02449.x), indexed in Pubmed: [21668938](https://pubmed.ncbi.nlm.nih.gov/21668938/).
22. Yu B, Zhang X, Sun P, et al. Non-stimulation needle with external indwelling cannula for brachial plexus block and pain management in 62 patients undergoing upper-limb surgery. Int J Med Sci. 2012; 9(9): 766–771, doi: [10.7150/ijms.5007](https://doi.org/10.7150/ijms.5007), indexed in Pubmed: [23136539](https://pubmed.ncbi.nlm.nih.gov/23136539/).
23. Sinha SK, Abrams JH, Weller RS. Ultrasound-guided interscalene needle placement produces successful anesthesia regardless of

motor stimulation above or below 0.5 mA. Anesth Analg. 2007; 105(3): 848–852, doi: [10.1213/01.ane.0000271912.84440.01](https://doi.org/10.1213/01.ane.0000271912.84440.01), indexed in Pubmed: [17717249](https://pubmed.ncbi.nlm.nih.gov/17717249/).

Adres do korespondencji:

Michał J. Stasiowski, MD, PhD
Department of Anaesthesiology and Intensive Therapy
Medical University of Silesia
Plac Medyków 1, 41–200 Sosnowiec, Poland
e-mail: mstasiowski.anest@gmail.com

Otrzymano: 20.11.2016 r.

Zaakceptowano: 7.02.2017 r.