

## CASE REPORT

# Miliary tuberculosis with gastrointestinal involvement in a three-year-old child. Difficulties in the treatment

Karolina Ratajczyk-Pekrul, Anna Kunka-Mierzwa, Barbara Czerniecka, Paweł Gonerko

Department I of Paediatrics, Allergology and Pulmonology, Independent Public Specialist Health Centre “Zdroje”, Szczecin, Poland

## ABSTRACT

Miliary tuberculosis and gastrointestinal tuberculosis are now rare forms of tuberculosis. We present a case of a nearly three-year-old boy with disseminated tuberculosis with the involvement of lungs, intestines, abdominal lymph nodes, and complicated gastrointestinal obstruction treated surgically. The article presents the difficulties in the diagnostics and treatment of a patient with disseminated tuberculosis and gastrointestinal involvement, i.e. problems with decision-making regarding surgical treatment, difficulties with determining parenteral treatment in a patient with symptoms of gastrointestinal obstruction, identifying indications for systemic corticosteroid treatment, and diagnosis and procedures in immune reconstruction inflammatory syndrome. Additionally, the article presents the clinical picture of miliary tuberculosis in chest X-ray.

## KEY WORDS:

**disseminated tuberculosis, miliary tuberculosis, tuberculosis of the lymph nodes and intestines.**

## INTRODUCTION

Generalised tuberculosis in the paediatric population is extremely rare. According to Institute of Tuberculosis and Lung Diseases (IGiChP) figures, in 2018, in Poland, the total incidence of tuberculosis was 14.3/100 thousand, which positions the country in the average incidence rate. Tuberculosis in children under the age of 14 represents a small share of the total incidence (0.9%). In total 52 paediatric cases were registered – 35 pulmonary tuberculosis and 17 extrapulmonary cases [1]. We present a case of a three-year-old boy diagnosed with miliary tuberculosis and gastrointestinal tuberculosis.

## CASE REPORT

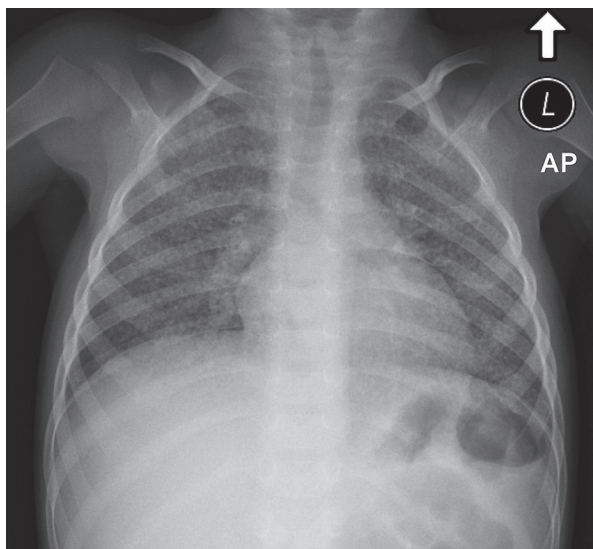
The child was born full term, delivered naturally in a good condition. On the second day of life, the boy was

vaccinated with BCG. The boy had never been seriously ill. The history revealed recurring fever, vomiting, loose stools alternating with constipation, and cough present for a month before admission. In an outpatient clinic, the boy was diagnosed with respiratory tract infection and treated with amoxicillin. Despite treatment, the symptoms persisted and, as a consequence, the boy was transferred to a district hospital. The father of the patient was suffering from alcoholism and died suddenly 15 months earlier, probably due to gastrointestinal haemorrhage; a post-mortem examination was not performed.

Upon admission, a chest X-ray was taken, revealing disseminated multiple micro-nodular lesions in the lungs (Fig. 1). The inflammatory markers were elevated. The diagnosis was pneumonia, and treatment was initiated – initially with cefuroxime, then, due to the lack of improvement, with cefotaxime, clarithromycin, and amikacin. Despite treatment, fever, cough, and elevated in-

## ADDRESS FOR CORRESPONDENCE:

Karolina Ratajczyk-Pekrul, Department I of Paediatrics, Allergology and Pulmonology, Independent Public Specialist Health Centre “Zdroje”, 4 Mączna St., 70-780 Szczecin, Poland, ORCID: 0000-0002-9382-7204, e-mail: krpekrul@wp.pl



**FIGURE 1.** Chest X-ray taken early on in the illness. Chest postero-anterior radiograph shows small nodules evenly distributed on both lung fields – typical picture of miliary tuberculosis

Inflammatory markers persisted. Interferon gamma release assay (IGRA) QuantiFERON-TB Gold test was made, and, having received a positive test result, the patient was transferred to the pulmonological department with suspicion of tuberculosis.

On admission, the boy was in a good general state of health. Upon physical examination the following deviations from standards were found: fever, body weight at the third centile, tense abdominal wall, palpable liver 3 cm below the costal margin, and dental caries. There was no post-BCG vaccination scar on the left arm. Laboratory abnormalities revealed elevated inflammatory markers – CRP (138.99 mg/l) and procalcitonin (6.3 ng/ml), microcytic anaemia, moderate lymphopaenia (1500 lymphocytes/ml), high GGTP levels, and titre of *Mycoplasma pneumoniae* IgM antibodies. In immunoassay, the patient tested negative for Epstein-Barr virus (EBV), cytomegalovirus (CMV), human immunodeficiency virus (HIV), adenovirus, and rotavirus infections. The QuantiFERON-TB Gold test was repeated during the first days of hospitalisation and the result was negative. Abdominal ultrasonography revealed no abnormalities. On day 1 of hospitalisation, bronchofiberoscopy was performed and a gastric lavage was taken to be tested for tuberculosis. Bronchial washing bacterioscopy as well as gastric lavage tested for *Mycobacterium tuberculosis* were positive (all bacteriological tests were performed in Laboratorium Mikrobiologiczne “Diagnostyka”, 1 Sokołowskiego St., Szczecin). Bronchial washing showed the presence of *M. tuberculosis* complex (GeneXpert MTB/RIF). Bronchial aspirate culture for typical pathogenic bacteria was negative. On the grounds of clinical signs, abnormalities revealed in lung X-ray, inefficient antibiotic therapy, and genetic testing, miliary tuberculosis was diagnosed. Lumbar puncture was performed, and involvement of the central nervous system was excluded.

Quadruple antituberculous pharmacotherapy was initiated: isoniazid (INH) 10 mg/kg, rifampicin (RMP) 15 mg/kg, pyrazinamide (PZA) 35 mg/kg, ethambutol (EMB) 20 mg/kg, and prednisone 1.5 mg/kg. Initially, cefotaxime was continued and azithromycin was introduced in the treatment. There was an improvement in the general condition, fever subsided, and levels of inflammatory markers decreased. After seven days, systemic corticosteroids were discontinued. The results of the bronchial washing and gastric lavage culture, obtained at a later point in time, confirmed the presence of *M. tuberculosis* with full susceptibility to anti-tuberculosis drugs. After two weeks of treatment the fever returned, inflammatory markers were elevated, and the general condition of the patient worsened – the child was grumpy, sore, had loose stools, complained of abdominal pain, pain in the right lower limb (the patient ceased walking), his cervical lymph nodes were markedly enlarged, and abdominal bloating persisted. Ultrasonography of the knee and hip joints showed no abnormalities. Ultrasonography of the neck area revealed numerous enlarged lymph nodes along the sternocleidomastoid muscle and in the supraclavicular fossae. Abdominal cavity ultrasound showed thickening of the intestinal wall in the area of the cecum and the ileocecal valve, and hyperechogenic lymph node (2.3 cm × 1.6 cm). These signs and symptoms suggested immune reconstitution inflammatory syndrome (IRIS), thus prednisolone in dose 1.5 mg/kg was introduced again. These resulted in a quick improvement – reduced cervical lymph nodes, lower pain in the right lower limb and the abdomen, the patient started walking again, and the inflammatory markers decreased.

After five days, corticosteroids were discontinued. After a week, the patient showed signs of gastrointestinal obstruction. The diagnosis was confirmed in a plain abdominal X-ray and abdominal ultrasound. Following surgical consultation, the conservative treatment decision was made: oral feeding was discontinued, oral medication was substituted with intramuscular streptomycin (SM) 16 mg/kg, intravenous levofloxacin 8.5 mg/kg, and RMP 16 mg/kg. The patient’s health condition improved – abdominal pain and vomiting subsided, and there were normal stools every 1–2 days. After a week of treatment, medications and oral feeding were introduced with good tolerance. In the fifth and sixth week of the treatment, the result of gastric lavage bacterioscopy, obtained three times, was negative.

One week after the initiation of oral feeding, the symptoms of gastrointestinal obstruction recurred. Parenteral nutrition and, once again, anti-tuberculosis medication and systemic corticosteroids were introduced (19 days). The symptoms of gastrointestinal obstruction subsided. The oral feeding and medication were introduced. The patient felt well, had a good appetite, and passed normal stools. The patient was discharged in a good condition after two months of treatment. Due to a complicated course

of illness, intensive treatment with three medicines (INH, RMP, and PZA) was prolonged. During the patient's stay at home, there was vomiting and lack of appetite. In the following two weeks, the patient was again admitted to the hospital department showing signs of cachexia.

Abdominal ultrasound revealed the continuous presence of thickening of the ileocecal valve and growth of the distended small intestinal loop with wall thickening. Abdominal cavity X-ray showed characteristics of mechanical gastrointestinal tract obstruction. With a contrast-enhanced examination of the gastrointestinal track using Omnipaque, a picture of subileus at the ileocecal valve was revealed. A chest X-ray showed a significant improvement in lung aeration – disseminated micro-nodular lesions were present to a lesser extent in comparison to the previous tests. The results of repeated bacterioscopy and gastric lavage culture were negative. Oral anti-tuberculosis treatment was continued (RMP and INH), oral feeding was discontinued and parenteral nutrition was initiated, and systemic corticosteroids were introduced into the treatment. The patient was in a good general condition, cheerful, active, and without complaints, gradually gaining weight. After three weeks, the gastrointestinal passage was repeated – the narrowing of the distal fragment of the ileum persisted. Colonoscopy was planned; however, due to aggravated symptoms of gastrointestinal obstruction, the patient was scheduled for surgery.

In the Department of Paediatric Surgery, laparotomy with resection of the distal fragment of the ileum and caecum was performed and the end-to-side ileoascending colon anastomosis was executed. Direct examination of surgical specimens identified acid-fast bacilli, and the genetic tests showed *M. tuberculosis* complex. On day 9 following the surgery, the patient was discharged in good condition with INH and RMP therapy. The patient underwent follow-up visits in the hospital pulmonary clinic. The treatment for tuberculosis was terminated 12 months after the initiation (Fig. 2).

At the time of diagnosis all of the co-residents (mother and siblings) were taken under pulmonological control. Tuberculosis and latent tuberculosis were excluded. The whole family is regularly checked in a pulmonary clinic. The case was reported to the Sanitary Epidemiological Station. The source of infection was not found.

## DISCUSSION

In the presented case, the diagnosis of pulmonary tuberculosis was made on the grounds of clinical data and confirmed with the use of bacteriological and genetic testing for *M. tuberculosis*. The negative result of IGRA test in an acute disease process which, however, does not exclude tuberculosis, was notable [2–4]. The negative result of IGRA test could have been caused by mistakes during obtaining, storing, or transporting the blood/lymphocytes. The outcome of this test depends on strict adherence to

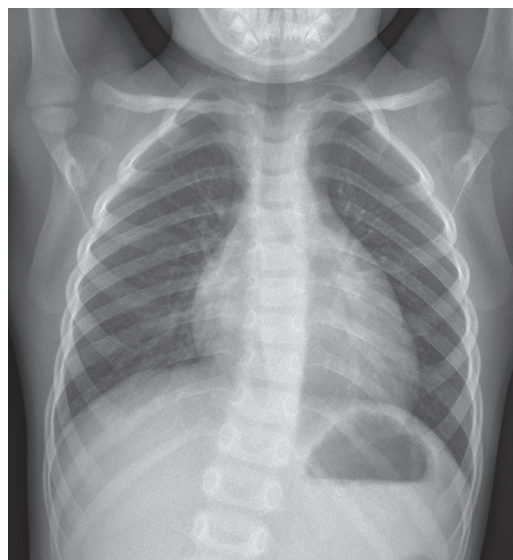


FIGURE 2. Chest X-ray taken at the time of treatment termination. Normal picture of the lungs

the procedures, in accordance with the directions of the manufacturer. Any deviation from the correct technique of test conduction can significantly influence the results [2]. In the presented case, a tuberculin test was not made due to temporary lack of tuberculin. However, in an acute phase of tuberculosis, the result of a tuberculin test may also be negative [2].

The boy was vaccinated with BCG. According to current data, the vaccine is effective in 70 to 80% against the most severe forms of tuberculosis, such as tuberculous meningitis in children [5, 6]. BCG vaccination did not protect the boy from a severe form of disseminated tuberculosis. The possible reasons were: household contact with a patient with pulmonary tuberculosis (e.g. the sputum smear-positive individual, the lack of data on father's illness); mistakes in vaccination – no post-vaccination scar; immunity disorders – HIV infection excluded, earlier interviews did not show heavy immunity problems.

The diagnosis of intestinal tuberculosis was made at the moment of gastrointestinal obstruction appearance. The presented case and literature on the subject underline the necessity of diagnostics for gastrointestinal tuberculosis in each patient with tuberculosis and gastrointestinal symptoms [7].

It was necessary to repeatedly introduce corticosteroids in the treatment – initially on diagnosis of miliary tuberculosis, and then, due to IRIS diagnosed on the grounds of deterioration of general condition, increase in inflammatory markers, and enlarged lymph nodes following the initial improvement while on anti-tuberculosis treatment. The aforementioned syndrome is most prevalent, however, not only in patients with immunodeficiency (particularly HIV-positive patients) treated for tuberculosis. Conducive to the occurrence of the syndrome are extrapulmonary tuberculosis, disseminated forms of tuberculosis, states of lymphopaenia, and malnourish-

ment [8, 9]. It usually develops within several days to six months after the initiation of treatment. Following the use of systemic corticosteroids, there was a rapid clinical improvement [2, 8, 9].

The aim of the repeated corticosteroid treatment was to reduce the inflammatory processes in the abdominal cavity, which contributed to the occurrence of gastrointestinal obstruction. The treatment was continued, with intervals during improvement, for a total length of four weeks, and was gradually discontinued following the surgery. According to the reviewer's opinion, the cause of the therapeutic difficulties with the boy could have been the interrupted use of corticosteroids. In times when acute, spread tuberculosis in children was frequent (the 1960s and 1970s), in the treatment of miliary tuberculosis, meningitis, encephalitis, and pleurisy, prednisone was administered constantly for four weeks. IRIS syndrome was known then as "the Jarisch-Herxheimer and Łukasiewicz reaction", as in the course of treatment of *Treponema pallidum* infection. The use of corticosteroids in antimycobacterial therapy is safe and, for children with acute forms of tuberculosis (meningitis, encephalitis, miliary tuberculosis), necessary.

The symptoms of gastrointestinal obstruction complicating the disease course in the presented case necessitated parenteral treatment. Due to the lack of parenteral forms of INH, EMB, and PZA, the treatment consisted of temporary use of intravenous preparations of RMP and levofloxacin and intramuscular SM.

Surgical treatment was considered several times because it is indicated in cases of ineffective antimycobacterial therapy, treatment of multi-drug-resistant tuberculosis, or particular cases of extrapulmonary tuberculosis. The guidelines recommend the procedure after at least two months of antimycobacterial treatment [2]. In the presented case, the surgical procedure resulted in a radical improvement – pain subsided, the physiological route for feeding was re-established, and the treatment was continued in oral form.

The treatment of a patient with miliary tuberculosis and intestinal tuberculosis proved to be challenging. The rarity of the occurrence of this form of tuberculosis, lack of therapeutic regimen regarding the aforementioned developments, as well as limited experience hindered the choice of optimal therapeutic management.

## DISCLOSURE

The authors declare no conflict of interest.

## REFERENCES

1. Korzeniewska-Kosela M, Głaz P, Mieczkowska B, et al. (eds.). *Gruźlica i Choroby Układu Oddechowego w Polsce w 2018 r.* Biuletyn Instytutu Gruźlicy i Chorób Płuc, Warszawa 2019.
2. Augustynowicz-Kopeć E, Demkow U, Grzelewska-Rzymowska I, et al. Zalecenia Polskiego Towarzystwa Chorób Płuc dotyczące

rozpoznawania, leczenia i zapobiegania gruźlicy u dorosłych i dzieci. *Pneumon Alergol Pol* 2013; 81: 323-379.

3. Borkowska D, Augustynowicz-Kopeć E. Czy testy IGRA mogą okazać się pomocne w diagnostyce gruźlicy płuc i postaci pozapłucnych? *Post Nauk Med* 2015; 4: 289-293.
4. Takwoingi Y, Whitchworth H, Rees-Roberts M, et al. Interferon gamma release assays for Diagnostic Evaluation of Active tuberculosis (IDEA): test accuracy study and economic evaluation. *Health Technol Assess* 2019; 23: 1-152.
5. Bielecka T, Augustynowicz-Kopeć E, Gonerko P, et al. Recommendations for the management of tuberculosis in children – KOMPASS TB. Part 1: Tuberculosis prevention. *Adv Respir Med* 2018; 86: 149-157.
6. <https://www.nhs.uk/conditions/vaccinations/bcg-tuberculosis-tb-vaccine/>
7. Kentley J, Ooi JL, Potter J. Intestinal tuberculosis: a diagnostic challenge. *Trop Med Int Health* 2017; 22: 994-999.
8. Cheng VC, Yam WC, Woo PC, et al. Risk factors for development of paradoxical response during antituberculosis therapy in HIV-negative patients. *Eur J Clin Microbiol Infect Dis* 2003; 22: 597-602.
9. Breen RA, Smith CJ, Bettinson H, et al. Paradoxical reactions during tuberculosis treatment in patients with and without HIV co-infection. *Thorax* 2004; 59: 704-707.