

(38)

# Macular microcirculation blood flow changes after conventional surgery for rhegmatogenous retinal detachment

## Zmiany w mikrokrążeniu plamki po konwencjonalnej operacji odwarstwienia siatkówki

Agnieszka Kubicka-Trzaska, Alina Górniak-Bednarz

Department of Ophthalmology, Clinic of Ophthalmology and Ocular Oncology,  
Medical College, Jagiellonian University, Kraków, Poland  
Head: Ass. Prof. Bożena Romanowska-Dixon, MD, PhD

### Summary:

**Purpose:** To assess the macular microcirculation blood flow in patients after conventional surgery for rhegmatogenous retinal detachment (RRD) with Doppler laser scanning (HRF – Heidelberg retina flowmeter).

**Material and methods:** Thirty patients (13 males and 17 females) in age: 28 – 68 years, mean age: 58.7 years with unilateral RRD without macular involvement were included in a prospective study. According to the type of buckling procedure the patients were divided into 3 groups: I – encircling band (8 cases), II – encircling band with radial or circumferential buckling (12 cases), III – radial or circumferential buckling (10 cases). In all patients the macular blood flow was measured with Heidelberg retina flowmeter (HRF) before and 4 weeks after scleral buckling procedures. Control group consists of the fellow eyes.

**Results:** At the baseline examination in a group of eyes with RRD the mean values of macular blood flow were significantly lower comparing to fellow eyes and reached respectively:  $298.4 \pm 79.2$  AU and  $435.6 \pm 121.0$  AU ( $p=0.001$ ) and correlated with the extent of RRD ( $p<0.05$ ).

Four weeks after surgery eyes that underwent the buckling procedures showed the elevation of macular blood flow as compared to the baseline values ( $p=0.001$ ), however they remain slightly lower as compared to fellow eyes. The macular microcirculation blood flow changes were not influenced by the type of scleral buckling ( $p=0.2$ ).

**Conclusions:** In the eyes with rhegmatogenous retinal detachment without macular involvement the mean macular microcirculation blood flows were lower as compared to fellow eyes. Different buckling procedures for rhegmatogenous retinal detachment influence the macular blood flow, causing its improvement as compared to the preoperative status but they remain lower comparing to fellow eyes.

### Słowa kluczowe:

Odwarstwienie siatkówki, procedura opasania twardówki, badanie Dopplerowskie, mikrokrążenie plamkowe.

### Key words:

Rhegmatogenous retinal detachment, scleral buckling procedures, Doppler laser scanning, macular microcirculation blood flow.

Conventional retinal surgery involves the creation of inward indentation of the sclera. Scleral buckling procedures are the methods of treatment for the most of uncomplicated rhegmatogenous retinal detachments (RRD). In some cases however in spite of a good anatomic success, even in patients without macular involvement, the deterioration of macular function after scleral buckling procedures has been noted. There are some evidences that the pathogenesis of these abnormalities is associated with the disturbances of retinal and choroidal circulation after RRD conventional surgery (1-5).

There are many methods of measurement of the ocular blood flow: colour Doppler ultrasonography, Doppler velocimetry, the laser speckle method, pulsatile ocular blood flow technique and videofluorescence angiography (1-6). However, the evaluation of the macular microcirculation by these techniques is difficult. Heidelberg retina flowmeter (HRF), which combines the technique of laser Doppler flowmetry with laser scanning technology, can measure the blood flow within the macular region.

There are many publication about the haemodynamic parameters changes in the ophthalmic artery, short posterior ciliary arteries, long posterior ciliary arteries, central artery of the retina and choroid in patients before and after scleral buckling procedures for RRD (1-5,7-11). But we found only two studies about the evaluation of retinal microcirculation blood flow using Doppler laser scanning in patients with RRD who underwent the conventional retinal surgery (12,13).

The aim of this study was to assess the behavior of macular microcirculation blood flow in patients before and after conventional surgery for RRD without macular involvement using Heidelberg retina flowmeter.

### Material and methods

Thirty patients with unilateral RRD without macular involvement, who underwent uncomplicated scleral buckling procedures, were included in a prospective study. There were 13 males and 17 females, aged from 28 – 68 years, mean age:  $51.7$  yrs  $\pm$   $15.3$ . The entry criteria for the study were RRD local-

ized to the periphery of the fundus, not involving the macula and clear optic media. Patients presenting eye diseases: glaucoma, diabetic retinopathy, retinal vasculitis and uveitis and systemic disorders such as systemic hypertension and diabetes were excluded. The duration of RRD was from 4 days to one month; the mean time of duration of the symptoms was: 19.6 days.

The diagnosis of RRD was established based on a standard ophthalmic examination which included: best corrected visual acuity, intraocular pressure measurement, anterior segment examination and indirect ophthalmoscopy using a +90 D lens.

The best corrected visual acuity in the affected eyes ranged from 1.0 to 0.6 and in the fellow eyes: 1.0 to 0.5. Refraction of the affected eyes ranged from 0.0 D to -10.0 D and in the fellow eyes from 0.0 D to -8.0 D. The intraocular pressure in the affected eyes was:  $10.7 \pm 2.8$  mmHg and in the fellow eyes:  $13.2 \pm 1.8$  mmHg. Six patients had pseudophakia and two aphakia in the affected eye. The extent of RRD ranged from 3 clock hours to 8 clock hours (mean: 4.5 clock hours). In all cases the retinal breaks were identified; there was a single retinal break in 18 eyes and in 12 eyes, the number of retinal breaks ranged from 2 to 4. In 14 eyes with high myopia the peripheral vitreo-retinal degenerations (lattice and snail-track degenerations) were present. In both pre- and postoperative examinations no pathology within the macula was detected in 26 eyes, while 4 of them demonstrated the presence of discrete pigment mottling.

According to the type of buckling procedure the patients were divided into 3 groups: I – encircling band (8 cases), II – encircling band with radial or circumferential buckling (12 cases), III – radial or circumferential buckling (10 cases). In all cases surgery was performed under local anaesthesia. Scleral buckling procedures included transscleral cryotherapy of the retinal breaks and co-existing retinal degenerations, then in local buckling a silicone sponge No. 504, No. 506, No. 507 (MIRA, Inc., USA) was used. In encircling procedure, a silicone band No.

240 (MIRA Inc., USA) was used. The extent of the explants was consistent with the size and location of retinal breaks and co-existing peripheral degenerations. Subretinal fluid was drained externally in 17 patients. There were no intraoperative complications. At the end of the surgery indirect ophthalmoscopy revealed retinal reattachment.

The tissue blood flow in the macular area was measured using a scanning laser flowmeter (Heidelberg retina flowmeter, Heidelberg, Germany). The measurement area included a zone of  $10 \times 2.5^\circ$ , that equals to  $2.8 \times 0.7$  mm. During each measurement the foveola was located in the central part of the scanned area (Fig. 1). Measurements were performed at least three times for the macular area. The macular blood flow was measured before surgery and 4 weeks postoperatively.

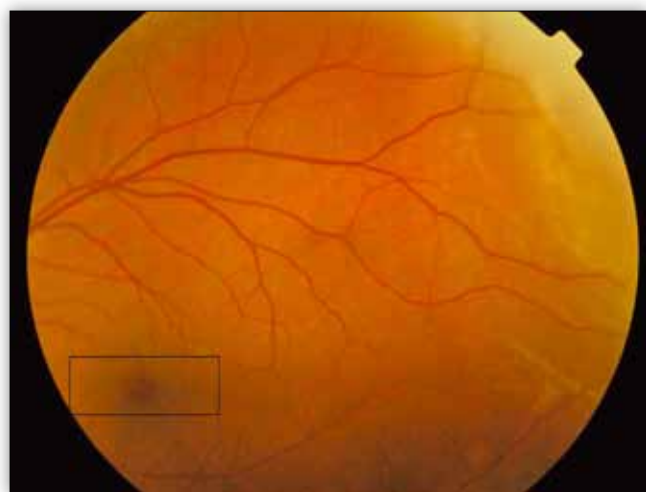The results of microcirculation blood flow were presented in arbitrary units – AU. The calculation of macular capillary blood flow was performed with AFFPIA program (automatic full-field perfusion image analyzer). The differences in macular blood flow between affected and contralateral eyes were statistically analyzed using a unpaired t-Student test for independent trials. Correlations between macular blood flow and clinical factors such as age, duration and extent of RRD were determined by multiple regression analysis. In order to evaluate the influence of surgical factors: type of buckling procedure and drainage of subretinal fluid, unpaired t-Student test was used. A probability value of less than 0.05 was considered to be statistically significant for all statistical analysis.

Control group consists of the fellow eyes, which showed no pathology within the macular region.

**Results**

At the baseline examination in a group of eyes with RRD the mean values of macular blood flow were significantly lower comparing to the fellow eyes and reached respectively:  $298.4 \pm 79.2$  AU and  $435.6 \pm 121.0$  AU ( $p=0.001$ ) (Fig. 2).

We noted that the preoperative macular blood flow had a significant correlation with the extent of RRD ( $p<0.05$ ); the more extent area of RRD the lower macular blood flow was detected (Table I). No significant correlation was found according to the duration of RRD, refraction, number of retinal breaks and patient’s age.



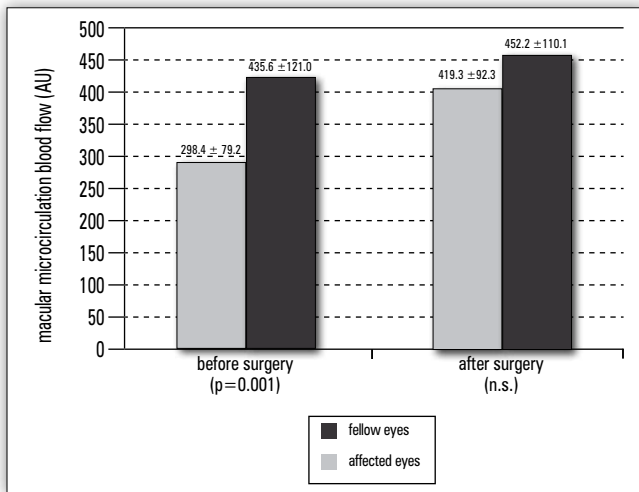
**Fig. 1.** The measurement area included a zone of  $10 \times 2.5^\circ$ , that equals to  $2.8 \times 0.7$  mm. During each measurement the foveola was located in the central part of the scanned area. Retinal detachment is present in a superior-temporal part of the fundus.

**Ryc. 1.** Pomiar pola obejmował obszar  $10 \times 2.5^\circ$ , który odpowiadał  $2.8 \times 0.7$  mm. Podczas każdego pomiaru dołeczek był w centrum badanego pola. Odwarstwienie siatkówki znajduje się w górnej skroniowej części pola widzenia.

Extent of rhegmatogenous retinal detachment	Values of macular microcirculation blood flow in eyes with rhegmatogenous retinal detachment before surgery [AU]
3 clock hours	$330.4 \pm 108.6$
4 clock hours	$316.2 \pm 93.5$
5 clock hours	$304.9 \pm 90.7$
6 clock hours	$291.5 \pm 89.7$
8 clock hours	$270.1 \pm 70.4$

**Tab. I.** The values of preoperative macular microcirculation blood flow and extent of rhegmatogenous retinal detachment ( $p<0.05$ ).

**Tab. I.** Przedoperacyjne wartości przepływu w mikrokrążeniu plamki i rozległość odwarstwienia siatkówki ( $p<0,05$ ).



**Fig. 2.** Macular microcirculation blood flow in affected eyes before and after surgery in correlation to the fellow eyes.

**Ryc. 2.** Przepływ w mikrokrążeniu siatkówki w oczach chorych przed operacją i po operacji w porównaniu do oczu zdrowych.

Four weeks after surgery eyes that underwent the buckling procedures showed elevation of macular blood flow comparing to the preoperative values (p=0.001), however they remain lower as compared to the fellow eyes, but the difference did not reach a statistically significant level (p=0.1) (Fig.2).

After surgery the visual acuity was maintained at baseline levels in 18 cases, improved in 8 (by 1-3 lines on Snellen charts), and deteriorated in 4 patients (by 1 to 2 lines). In eyes with postoperative visual acuity changes we did not find a correlation between the level of visual acuity and the values of macular blood flow.

There was no statistically significant difference between the rates of macular blood flow in three groups of patients classified according to the type of buckling procedure, however the post-

Scleral buckling procedure (No. of eyes)	Macular microcirculation blood flow		Significance (p value)
	Before surgery	After surgery	
Encircling band (n=8)	287.0 ± 89.5 AU	399.5 ± 98.5 AU	0.001
Encircling band with radial or circumferential buckling (n=12)	293.7 ± 99.9 AU	403.6 ± 103.6 AU	0.001
Radial or circumferential buckling (n=10)	302.9 ± 102.1 AU	445.9 ± 106.0 AU	0.001
Significance (p value)	n.s.	n.s.	

**Tab. II.** Correlation between various scleral buckling procedures and macular microcirculation blood flow before and 4 weeks after surgery.

**Tab. II.** Korelacja pomiędzy różnymi metodami opasania twardówki a przepływem w mikrokrążeniu siatkówki przed zabiegiem i po 4 tygodniach po zabiegu.

operative values of macular blood flows were lower in cases underwent encircling procedures alone or with additional local buckling (Table II).

The drainage of subretinal fluid had no influence on macular microcirculation blood flow 4 weeks after surgery.

**Discussion**

Based on literature it has been known that RRD without macular involvement and various scleral buckling procedures influence the ocular blood flow. Reduction of the blood flow in the central retinal artery, main branches of the central retinal artery, the ophthalmic artery, choroid after conventional surgery for retinal detachment has been presented in many publications (1-5,7,9,10). However there is scant information about the evaluation of the macular microcirculation blood flow in patients with RRD. It has been known that in some cases, in spite of good anatomical results of RRD surgery, the vision might be affected. It is postulated that this complication may be associated with haemodynamic changes in ocular circulation followed by RRD conventional surgery. Compression on the peripheral vasculature by indentation caused by the scleral buckle or encircling element might be responsible for the alterations in ocular blood supply (5,7,10,14).

Ohkubo using fluorescein angiography presented signs of reduced retinal perfusion in regions of reattached retina that was indented by scleral buckling (14).

Studies in which the laser Doppler method was used showed that pulsatile retinal arterial blood flows in eyes that underwent RRD surgery were altered, and on average 50% were lower as compared to the fellow eyes (15).

Using bidirectional laser Doppler, Ogasawara et al. reported that in patients after the RRD surgery the blood flow rates in the major temporal retinal arteries were on average 50% lower in treated eyes than in the contralateral eyes (9).

Regillo et al. using colour Doppler imaging indicated that scleral buckling with encircling elements decreased average blood flow velocity in the central retinal artery by 35% and 50%, one day and one week postoperatively, respectively (7).

Nagahara et al. analyzed the effects of scleral buckling and encircling procedures on retinochoroidal circulation within the macula using the laser speckle method (1). The investigators reported that foveal blood flow was normal before and after surgery, however decreased blood velocity in the choroid and retina on buckled area were noted. The data obtained from the foveal region using the laser speckle method was assumed to be affected only by choroidal circulation because the area was free from retinal capillaries and the measuring depth was about 1mm. The measuring depth by the HRF is 300 μm and the measured area is 2.8 x 0.7 mm thus the contribution of the foveola in this method is extremely small (12).

In our group of patients using HRF technique we noticed reduction in the macular blood flow before surgery in the affected eyes. The same observations were published by other investigators. Eshita et al. in a group of 28 patients with unilateral RRD demonstrated that the mean blood flow in macular area before surgery was lower as compared to the fellow eyes (12). The same results were demonstrated by Sanabary; in 20 cases with unilateral RRD the retinal blood flow was significantly lower in detached eyes than in healthy, contralateral eyes (13).

Four weeks after surgery in our group of patients we observed improvement in the macular blood flow as compared to baseline rates, however it remained slightly lower as compared to the fellow eyes. This observation suggests that scleral buckling procedures improve abnormal microcirculation in the macular area in the patients with RRD. This finding is consistent with a report by Eshita et al.; the authors demonstrated the normalization of the preoperative reduction of the macular blood flow one month after surgery (12). In another paper, the analysis of the macular blood flow and perfusion with HRF before and two weeks after surgery, revealed that different buckling procedures can reduce retinal blood flow by about 13-20% (13). The discrepancy between the postoperative retinal blood flow in our study and the results presented in a study by Sanabary might be associated with different time of follow-up periods.

We found the significant correlation between the degree of disturbances of the retinal microcirculation in the macular area and the extent of RRD, whereas no correlation was detected with age, number of retinal breaks and duration of RRD. The same results were presented by Eshita et al.; the authors showed that the preoperative a/f ratio (affected to fellow eye macular blood flow ratio) had a significant correlation only with extent of RRD (12). As presented in our study and also in literature the type of buckling procedure may influence the postoperative rates of macular blood flows. The rates of macular microcirculation blood flows were lower in patients who underwent encircling procedures. This observation might be associated with 360° of extent of scleral encircling band and the more extensive area of compression on the peripheral vasculature as compared to local bucklings which results in more alterations in ocular blood supply in these cases. The results of our study showed that the drainage of subretinal fluid did not influence the values of macular microcirculation after surgery. The same observations were published by others (12).

### Conclusion

Based on results of our study in eyes with RRD without macular involvement the mean macular blood flows before surgery were lower as compared to the fellow eyes. Different buckling procedures for RRD change the macular blood flow, causing its improvement as compared to the preoperative status, but they remain lower comparing to the contralateral eyes.

### REFERENCES:

1. Nagahara M., Tamaki Y., Araie M., Eguchi S.: *Effects of scleral buckling and encircling procedures on human optic nerve head and retinochoroidal circulation*. Br J Ophthalmol 2000, 84, 31-36.
2. Yokota H., Mori F., Nagaoka T., Sugawara R., Yoshida A.: *Pulsatile ocular blood flow: changes associated with scleral buckling procedures*. Jpn J Ophthalmol 2005, 49(2), 162-165.

3. Ito Y., Sasoh M., Ido M., Osawa S., Wakitani Y., Uji Y.: *Effects of scleral buckling without encircling procedures on retrolubar hemodynamics as measured by color Doppler imaging*. Arch Ophthalmol 2005, 123(7), 950-953.
4. Raczyńska K., Grabowska A., Zdybel E., Studniarek M., Dembicka H., Klawiter-Rydz M.: *Przepływ naczyniowy u chorych z odwarstwieniem siatkówki w kolorowej ultrasonografii dopplerowskiej*. Klin Oczna 2003, 105(1-2), 24-26.
5. Hanioglu-Kargi S., Yazar Z., Ziraman I., Guesel E.: *Effects of scleral buckling on the retrolubar haemodynamic changes*. Eye 2000, 14, 165-171.
6. Satoh Y.: *Retinal circulation in rhegmatogenous retinal detachment demonstrated by videofluorescence angiography and image analysis*. Acta Soc Ophthalmol Jpn 1989, 93, 1002-1008.
7. Regillo C.D., Sergott R.C., Brown G.C.: *Successful scleral buckling procedures decrease central retinal artery blood flow velocity*. Ophthalmology 1993, 100(7), 1044-1049.
8. Jukic T., Katusic D., Cikara I., Kordic R., Sikic J., Vukojevic N., Saric B.: *Ocular blood flow parameters in patients with rhegmatogenous retinal detachment*. Coll. Antropol. 2005, 29(1), 75-79.
9. Ogasawara H., Fekke G.T., Yoshida A., Milbocker M.T., Weiter J.J., McMeel J.W.: *Retinal blood flow alterations associated with scleral buckling and encircling procedures*. Br J Ophthalmol 1992, 76, 275-279.
10. Santos L., Capeans C., Gonzales F., Lorenzo J., Codesito J., Salorio M.S.: *Ocular blood flow velocity reduction after buckling surgery*. Graefes Arch Clin Exp Ophthalmol 1994, 232, 666-669.
11. Vetrugno M., Gigante G., Cardia L.: *The choroidal circulation after retinal detachment surgery*. Clin Hemorheol Microcirc 1999, 21, 349-352.
12. Eshita T., Shinoda K., Kimura L., Kitamura S., Ishida S., Inoue M., Mashina Y., Katsura H., Oguchi Y.: *Retinal blood flow in the macular area before and after scleral buckling procedures for rhegmatogenous retinal detachment without macular involvement*. Jpn J Ophthalmol 2004, 48, 358-363.
13. Sanabary Z.E.: *Study of retinal blood flow after different buckling procedures*. Bull Egyptian Ophthalmol Soc 2000, 93(4), 387-391.
14. Ohkubo H.: *Fluorescein angiographic findings in the detached and reattached retina*. Jpn J Ophthalmol 1988, 32, 423-428.
15. Yoshida A., Hirokawa H., Ishiko S., Ogasawara H.: *Ocular circulatory changes following scleral buckling procedures*. Br J Ophthalmol 1992, 76, 529-531.

XXVIII Sympozjon Retinologiczny, PTO, Poznań  
12-14.04.2007 r.

Praca wpłynęła do Redakcji 19.02.2007 r. (929)  
Zakwalifikowano do druku 25.03.2007 r.

Adres do korespondencji (Reprint requests to):  
Agnieszka Kubicka-Trzaska MD  
Lea Street 244/7  
30-133 Kraków