

(45)

Malignant glaucoma and Central Retinal Vein Occlusion after Nd: YAG laser posterior capsulotomy

Jaskra złośliwa i zakrzep żyły środkowej siatkówki po kapsulotomii tylnej laserem Nd: YAG

Malukiewicz Grażyna, Stafiej Joanna

Department of Ophthalmology, Ludwik Rydygier Medical College in Bydgoszcz, Nicolaus Copernicus University in Toruń
Head: Ass. Professor Grażyna Malukiewicz, MD, PhD

Summary:

Purpose: The purpose of this paper is to present the case of malignant glaucoma complicated by CRVO occurring after Nd: YAG laser posterior capsulotomy.

Material and methods: A 75 years old woman with pseudophakia and cardiovascular disease had undergone Nd: YAG laser posterior capsulotomy, the day after capsulotomy IOP increased in that eye up to 50 mmHg. Medical treatment alone appeared to be unsuccessful. IOP remained elevated (50 mmHg) and lack of anterior chamber occurred.

In the examination, the eye showed circumcorneal congestion, diffuse corneal edema, uniformly flat anterior chamber with dilated, nonreacting pupil, optic disc edema, retinal hemorrhages, dilated tortuous retinal veins and macular edema. Surgical therapy (pars plana vitrectomy and the anterior chamber reformation with air bubble) was performed in urgent course.

Results: Twenty four hours after surgical intervention anterior chamber remained deep, IOP reduced to 12,2 mmHg, B-scan ultrasonography did not show any aqueous pockets in the vitreous. In the following 10 days, the IOP remained within normal limits with a well-formed anterior chamber. The final best-corrected visual acuity of the eye was 0.3.

Conclusions: Early recognition of malignant glaucoma and proper treatment is the most important step to save the eye from severe consequences and prevent irreversible vision loss.

Key words:

CRVO, malignant glaucoma, Nd: YAG laser, posterior capsulotomy.

Streszczenie:

Cel: przedstawienie przypadku jaskry złośliwej powiklanej zakrzepem żyły środkowej siatkówki po kapsulotomii tylnej laserem YAG.

Material i metody: kobieta z rzekomowoczewkowością (lat 75), obciążona chorobami krążenia, u której w pierwszej dobie po wykonaniu kapsulotomii tylnej laserem YAG ciśnienie wewnątrzgałkowe wzrosło do 50 mmHg. Leczenie zachowawcze okazało się nieskuteczne, ciśnienie wewnątrzgałkowe utrzymywało się na poziomie 50 mmHg i wystąpiło zniesienie komory przedniej. Badanie wykazało okolorąbkowe przekrwienie, rozlany obrzęk rogówki, atalamię, szeroką niereagującą źrenicę, obrzęk tarczy nerwu wzrokowego, wylewy śródsiatkówkowe, poszerzone, kręte naczynia żyłne i obrzęk płamki. W trybie pilnym zastosowano leczenie chirurgiczne (witrektomię tylną korową i odtworzenie komory przedniej powietrzem).

Wyniki: 24 godziny po operacji komora przednia była głęboka, ciśnienie wewnątrzgałkowe wynosiło 12 mmHg. Badanie USG w prezentacji B nie wykazało zbiorników cieczy wodnistej w ciele szklistym. Przez następne 10 dni ciśnienie wewnątrzgałkowe pozostawało w normie i utrzymywała się głęboka komora przednia. Uzyskano ostrość wzroku 0,3 z korekcją.

Wniosek: wczesne rozpoznanie jaskry złośliwej i odpowiednie leczenie mają decydujące znaczenie dla uniknięcia poważnych konsekwencji, które mogą doprowadzić do nieodwracalnej utraty widzenia.

Słowa kluczowe:

CRVO, jaskra złośliwa, laser Nd: YAG, kapsulotomia tylna.

Introduction

Posterior capsule opacification is the most common nonrefractive cause of decreased postoperative visual acuity, with an incidence of 3,3% to 50% (1). Neodymium: YAG (Nd: YAG) laser posterior capsulotomy is relatively safe method of restoring visual acuity in patients with posterior capsular opacification. However, Nd: YAG can also result in variety of significant complications such as: intraocular pressure (IOP) elevation, pupillary block, corneal endothelial decompensation, glaucoma, iritis, hyphema, vitreous prolapse, retinal hemorrhage, central retinal

artery occlusion, macular hole, cystoid macular edema, retinal detachment and endophthalmitis (2). Transient increase of intraocular pressure is frequently observed, the development of acute angle-close glaucoma is uncommon (3). The association of Nd: YAG posterior capsulotomy with malignant glaucoma is extremely rare (4).

Case report

A 75 years old woman was referred to the Ophthalmology Department of the University Hospital Medical College Nicolaus

Copernicus University in Bydgoszcz, Poland with severe pain, redness, and decreased vision in her right eye. She had undergone Nd: YAG laser posterior capsulotomy in this eye with best corrected visual acuity (BCVA) 0.7, four days previously in an ophthalmic dispensary. No pathology of the eye fundus was described at that time. The patient had had an uneventful cataract extraction procedure 19 years ago in this eye. The day after capsulotomy the patient presented to the ophthalmic dispensary with an increase of IOP up to 50 mmHg. Combigan twice a day, Cosopt twice a day and Pilocarpine twice a day were prescribed. Neither gonioscopy nor laser iridotomy were done. She had not been referred to the Ophthalmological Department then. Three days later IOP, despite medical therapy, remained elevated (50 mmHg). It was at that time that the dispensary' doctor referred the patient to our department. During admission, BCVA was 1/50, IOP 40.2 mmHg in the right eye and hand movement (due to long lasting severe keratopathy), IOP 17.3 mmHg in the left eye.

The right eye showed circumcorneal congestion, diffuse corneal edema, uniformly flat anterior chamber with dilated, non reacting pupil. The intraocular lens was well placed in the ciliary sulcus with a large posterior capsule opening of 4 x 5 mm

in the center. Fundus examination by the indirect ophthalmoscopy showed optic disc edema, retinal hemorrhages, dilated tortuous retinal veins and macular edema (Fig. 1).

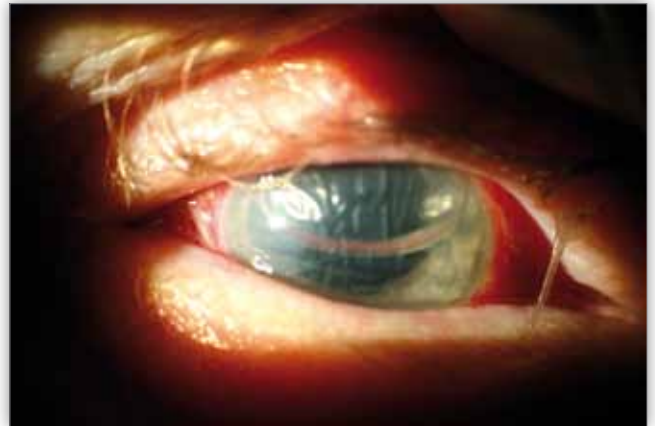

Fig. 3. Anterior segment photograph of the right eye twenty four hours after surgery showing well-formed anterior chamber with air bubble.

Ryc. 3. Przedni odcinek oka prawego 24 godziny po operacji – komora przednia o prawidłowej głębokości z pęcherzykiem powietrza.

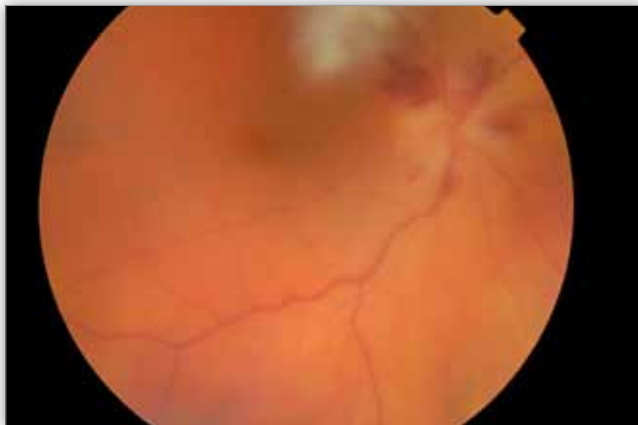

Fig. 1. Eye fundus before surgery with signs of central retinal vein occlusion.

Ryc. 1. Dno oka przed operacją z cechami zakrzepu żyły środkowej siatkówki.

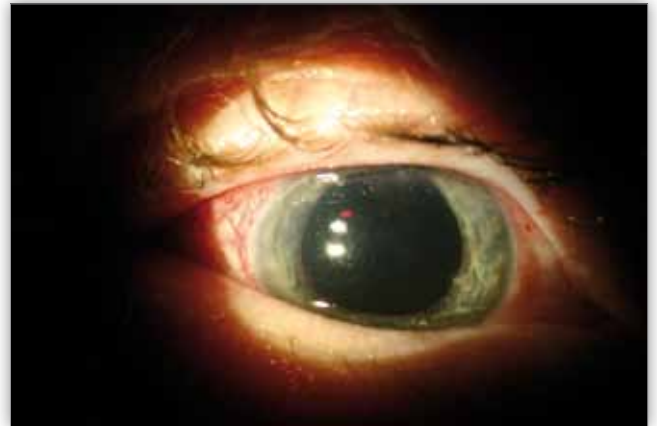


Fig. 4. Anterior segment photograph of the right eye five days after surgical intervention showing still well-formed anterior chamber.

Ryc. 4. Przedni odcinek oka prawego 5 dni po interwencji chirurgicznej – utrzymująca się prawidłowa głębokość komory przedniej.

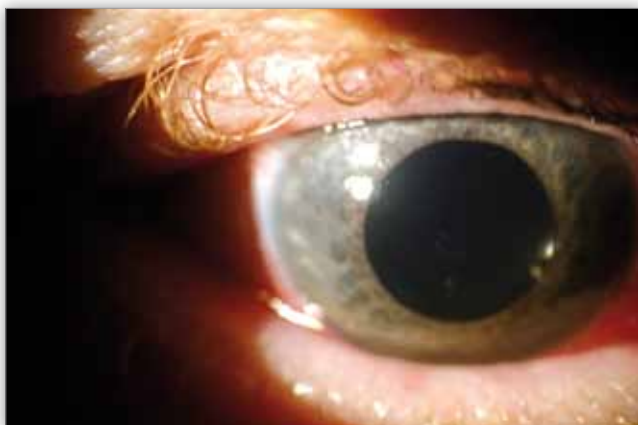

Fig. 2. Anterior segment of the right eye showing diffuse corneal edema, anterior chamber absent, dilated and non reacting pupil.

Ryc. 2. Przedni odcinek oka prawego z rozlanym obrzękiem rogówki, brak komory przedniej, szeroka źrenica niereagująca na światło.

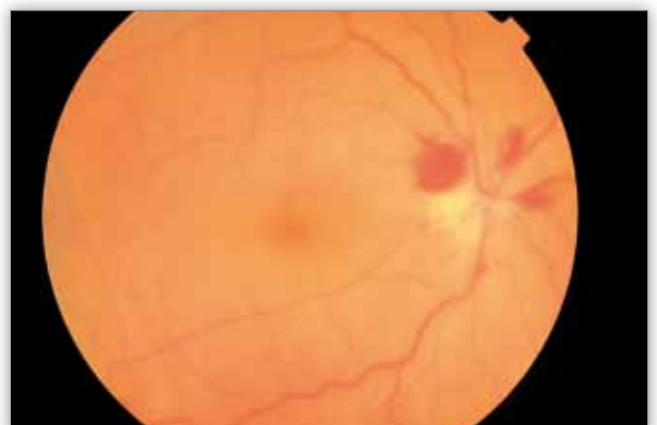


Fig. 5. Eye fundus five days after surgical intervention with signs of CRVO.

Ryc. 5. Dno oka 5 dni po interwencji chirurgicznej – widoczne objawy zakrzepu żyły środkowej siatkówki.

There was no evidence of choroidal detachment on ophthalmoscopy. A clinical diagnosis of malignant glaucoma and central retinal vein occlusion was made. B-scan ultrasonography revealed aqueous pockets within the vitreous space. The patient was administered 250 cc of mannitol intravenously and 70 g Glycerol orally, topical cycloplegics, beta-blockers, aqueous suppressants. Nd: YAG – laser iridotomy was performed. IOP decreased to 17.3 mmHg. The next day IOP was elevated again (37 mmHg) and lack of anterior chamber occurred (Fig. 2).

Posterior core vitrectomy (with BSS infusion) was performed. Anterior chamber was reformed with air injected with a 25-gauge needle through the limbus (Fig. 3).

Twenty four hours after surgical intervention anterior chamber remained deep, IOP reduced to 12.2 mmHg. Antiglaucoma medication was stopped. Anticoagulants were administered. B-scan ultrasonography did not show any aqueous pockets in the vitreous. Five days after PPV fluorescein angiography was performed. Non-ischemic CRVO was determined. In the following 10 days, the IOP remained within normal limits with a well-formed anterior chamber (Fig. 4).

The best-corrected visual acuity of the right eye was 2/50 due to folding of Descemet's membrane in the center of the cornea and the appearance of eye fundus was almost unchanged (Fig. 5).

The patient continues to report for control examinations in our department. Her final BCVA = 0.3 in the treated eye, the IOP remains within normal limits without antiglaucomatous drugs.

Discussion

To the best of our knowledge, our case is the third in which Nd: YAG capsulotomy led to malignant glaucoma, and the first of central retinal vein occlusion that occurred in the course of this complication.

In 1869, von Graefe first used the term malignant glaucoma to describe an entity characterized by elevated intraocular pressure (IOP) with a shallow or flat anterior chamber in the presence of a patent peripheral iridectomy.

A blockage of the normal aqueous flow at the level of the ciliary body, lens, and anterior vitreous face is believed to cause malignant glaucoma. Posterior misdirection of aqueous humor into the vitreous cavity occurs producing a continuous expansion of the vitreous cavity and increased posterior segment pressure. This accumulation of aqueous fluid in the vitreous cavity causes anterior displacement of the lens-iris diaphragm in phakic and pseudophakic eyes or forward displacement of the anterior hyaloid in aphakic patients. Malignant glaucoma has been described following: cataract surgery with or without intraocular implant (aphakic or pseudophakic malignant glaucoma), implantation of a large posterior chamber intraocular lens, cessation of topical cycloplegic therapy, induction of miotic therapy, laser iridotomy, laser capsulotomy, Nd: YAG cyclophotocoagulation, laser sclerotomy, Molteno implantation, Baerveldt glaucoma drainage device implantation, viscoelastic use, intravitreal injection of triamcinolone acetonide. Malignant glaucoma remains a difficult clinical problem that results in irreversible blindness if not promptly treated.

Trope et al. reported that the average age of patients with malignant glaucoma was 70 years which is corresponding with our patient (5).

In the case described here, vitreous prolapse and resulting pupillary block was suspected. The chance of suprachoroidal haemorrhage was also considered due to the possibility of anterior displacement of the lens-iris diaphragm. These options were excluded on the base of ophthalmic and ultrasonographic examinations.

During vitrectomy aqueous pockets in the vitreous were observed. This finding confirmed the diagnosis of malignant glaucoma.

In our opinion, during Nd: YAG laser posterior capsulotomy the anterior hyaloid face had been ruptured resulting in immediate local vitreous liquefaction (6,7). The aqueous was misdirected posteriorly in the liquefied anterior vitreous, creating aqueous pockets in the vitreous.

An additional predisposing factor in our patient was the presence of sulcus-fixed intraocular lens. It is known that sulcus-fixed intraocular lenses are associated with a more severe increase IOP (8).

It took one day to develop malignant glaucoma symptoms in our case, whereas it took 4 and 11 days in the cases reported previously (4,7). Similarly as Kumar Arya et al. we could not manage our case by medical treatment alone as was done by Masropasqua et al. (4,7). After surgical intervention (Pars Plana Vitrectomy and reformation of anterior chamber with air), the IOP became normal and the ultrasonographic findings showed disappearance of the aqueous pockets.

Visual acuity remained decreased due to central retinal vein occlusion which occurred probably due to existing predisposing cardiovascular factors (arterial hypertension, arteriosclerosis, atrial fibrillation), advanced age and high IOP.

Findings of this case imply the fact that malignant glaucoma can develop after Nd: YAG posterior capsulotomy, especially in patients with systemic risk factors mentioned above. The surgeon should be aware preoperatively of eyes at risk and observe them closely postoperatively. Additional systemic risk factors present in our patient led to an unfortunate sequence of events, complicating malignant glaucoma with central retinal vein occlusion. Early recognition is the most important step to save the eye from severe consequences and prevent irreversible vision loss.

References:

1. Ando H, Ando N, Oshika T: *Cumulative probability of neodymium: YAG laser posterior capsulotomy after phacoemulsification*. J Cataract Refract Surg 2003, 29, 2148-2154.
2. Billote C, Berdeaux G: *Adverse clinical consequences of neodymium: YAG laser treatment of posterior capsular opacification*. J Cataract Refract Surg 2004, 30, 2064-2071.
3. Dardabounis D, Ioannakis K, Detorakis E, Afendoulidis E, Kozobolis VP: *Late onset of acute angle-closure glaucoma following neodymium:YAG laser posterior capsulotomy*. Ophthalmic Surg Lasers Imaging 2007, 38, 56-58.
4. Arya SK, Sonika, Kochhar S, Kumar S, Kang M, Sood S: *Malignant glaucoma as a complication of Nd: YAG laser posterior capsulotomy*. Ophthalmic Surg Lasers Imaging 2004, 35, 248-250.
5. Trope GE, Pavlin CJ, Bau A, Bauman CR, Foster FS: *Malignant glaucoma. Clinical and ultrasound biomicroscopic features*. Ophthalmology 1994 Jun, 101(6), 1030-1035.

6. Ficker LA, Steele AD: *Complications of Nd: YAG laser posterior capsulotomy*. Trans Ophthalmol Soc UK 1985, 104, 529-532.
7. Mastropasqua L, Ciancaglini M, Carpineto P, Lobefalo L, Gallenga PE: *Aqueous misdirection syndrome: a complication of neodymium: YAG posterior capsulotomy*. J Cataract Refract Surg 1994, 20, 563-565.
8. Gimbel HV, VanWestenbrugge JA, Sanders DR, Raanan MG: *Effect of sulcus vs capsular fixation on YAG-induced pressure rises following posterior capsulotomy*. Arch Ophthalmol 1990, 108, 1126-1129.

The study was originally received 16.06.2010 (1235)/

Praca wpłynęła do Redakcji 16.06.2010 r. (1235)

Accepted for publication 14.07.2011/

Zakwalifikowano do druku 14.07.2011 r.

Reprint requests to/ Adres do korespondencji:

Ass. Professor Grażyna Malukiewicz, MD, PhD

Department of Ophthalmology,

Ludwik Rydygier Medical College in Bydgoszcz

ul. Skłodowskiej-Curie 9

85-094 Bydgoszcz, Poland

e-mail: malukiewicz@wp.pl



3. KURS „ELEKTROFIZJOLOGIA NARZĄDU WZROKU” POZNAŃ, 25-26 LISTOPADA 2011

**Patronat naukowy – Sekcja Elektrofizjologii
i Neurookulistyki Polskiego Towarzystwa
Okulistycznego**

Wykładowcy

prof. dr hab. n. med. Maciej Krawczyński,

dr n. med. Izabela Kulińska-Niedziela,

prof. dr hab. n. med. Wojciech Lubiński,

dr Mikołaj Meller, dr hab. n. med. Sławomir Michalak,

dr Marta Pawlak, dr hab. n. med. Dorota Pojda-Wilczek

Kierownik naukowy

dr n. med. Jadwiga Bernardczyk-Meller

Informacje i rejestracja on-line: www.ocuservice.com