

(10) **Syphilitic bilateral neuroretinitis – a case report****Zapalenie nerwu wzrokowego i siatkówki obojga oczu na tle kily – opis przypadku**

Piasecka Katarzyna, Nawrocki Jerzy, Michalewska Zofia

Department of Ophthalmology, III State Hospital by the name of Karol Jonscher in Lodz
Head: Professor Nawrocki Jerzy, MD, PhD

Streszczenie:	<p>Wstęp: kila jest układową chorobą przenoszoną drogą płciową, której częstość występowania znacznie zwiększyła się w ciągu ostatnich dwóch dekad. Objawy oczne w przebiegu kily mogą pojawić się w każdym okresie trwania choroby. Mogą dotyczyć każdej ze struktur oka i pozostawać jedynym objawem toczącego się procesu chorobowego.</p> <p>Opis przypadku: opis przypadku nagłego znacznego pogorszenia wzroku u 37-letniego pacjenta, u którego rozpoznano zapalenie nerwu wzrokowego i siatkówki obojga oczu. Badanie w lampie szczelinowej ujawniło symetryczny obrzęk tarczy nerwu wzrokowego w obojgu oczach oraz nieznaczny obrzęk okolicy plamkowej w oku prawym. W badaniu angiografii fluoresceinowej uwidoczniło zapalenie nerwu wzrokowego i siatkówki obojga oczu. Otrzymano pozytywne wyniki specyficznych dla kily testów serologicznych. W wyniku zastosowanego leczenia (penicylina domięśniowo 2,4 mln j przez 5 dni oraz 1,2 mln j przez kolejne 21 dni) uzyskano poprawę ostrości wzroku i całkowite wycofanie się zmian na dnie oka.</p> <p>Wnioski: w przypadku niewyjaśnionego obniżenia ostrości wzroku u pacjentów z zapaleniem nerwu wzrokowego i siatkówki należy zawsze wykonać badania w kierunku kily. Właściwe rozpoznanie i leczenie mogą prowadzić do wyleczenia.</p>
Słowa kluczowe:	zapalenie nerwu wzrokowego, zapalenie siatkówki, kila, kila oczna.
Summary:	<p>Purpose: Syphilis is a sexually transmitted, chronic, systemic infection of increasing prevalence. Ocular symptoms may develop at any stage of the disease process. This is to present a case of acute severe bilateral visual loss due to neuroretinitis with papillar oedema in an immunocompetent 37 years old patient.</p> <p>Material and methods: Indirect ophtalmoscopy showed symmetrical papillar oedema in both eyes and macular oedema in the right eye. Fundus fluorescein angiogram was performed revealing neuroretinitis in both eyes. Syphilis specific serological test results were positive.</p> <p>The patient was treated with intramuscular injections of penicillin 2.4 mln U per day for 5 days followed by 1.2 mln U per day for total 26 days.</p> <p>Results: His visual acuity improved to 1.0 in both eyes during 6 months follow up period. All pathological changes withdrew.</p> <p>Conclusions: This case shows that patients with unexplained visual loss coexisting with neuroretinitis should be tested for syphilis. With proper antibiotic treatment recovery of visual acuity may be observed.</p>
Key words:	neuroretinitis, ocular syphilis, syphilis.

Introduction

Syphilis is a sexually transmitted disease caused by *Treponema pallidum*. If left untreated it has the potential to cause significant morbidity to any major organ of the body. The prevalence appears to be significantly increasing in the last decade (1,2).

In its systemic intercourse any structure of the eye may be affected at any stage of the disease process, remaining the only sign of the infection (3). There are no pathognomonic signs of ocular syphilis. Frequent manifestations include interstitial keratitis, uveitis, chorioretinitis, retinitis, retinal vasculitis and cranial nerve and optic neuropathies (4). Therefore it is clinically challenging to diagnose syphilis based on ocular findings only.

Case report

A 37 years old male patient was presented to our clinic with acute severe, painless visual loss in the right eye (RE). Except mild anaemia he reported neither systemic complaints nor diseases.

Ophthalmic examination showed visual acuity of 0,1 and disturbed colour vision in the right eye (RE) and 1.0 with normal colour perception in the left eye (LE). Intraocular pressure was 13 mmHg and 15 mmHg respectively. No abnormalities in the anterior segments were noted. In indirect ophtalmoscopy we noted symmetrical papillar oedema in both eyes as well as small retinal oedema in macular region (Fig. 1).

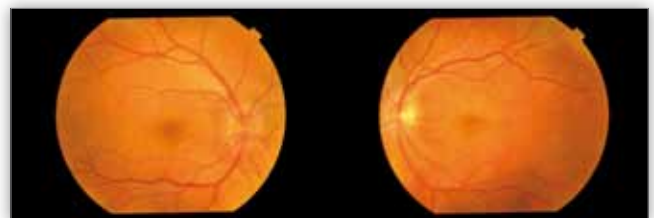


Fig. 1. Fundus photograph of both eyes demonstrating papillar and retinal oedema.

Ryc. 1. Fotografia dna oka z widocznym obrzękiem tarczy nerwu wzrokowego i siatkówki obojga oczu.

To exclude intracranial hypertension computer tomography of the cranium and neurological examination were arranged. Both showed no alterations.

Fundus fluorescein angiogram (FAG) was performed revealing papillary oedema and neuroretinitis in both eyes (Fig. 2).

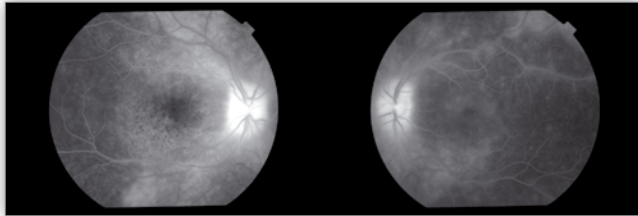


Fig. 2. Late phase of fundus fluorescein angiogram showing evidence of papillary oedema and late staining in both eyes.

Ryc. 2. Obrzęk tarczy nerwu wzrokowego oraz zastój barwnika w późnej fazie angiografii fluoresceinowej obojga oczu.

Screening blood tests and all inflammatory parameters were unremarkable. Most popular infectious agents of neuroretinitis such as *Borrelia burgdorferi*, *Bartonella henselae*, *Francisella tularensis*, *Toxoplasma gondii* were all negative. Non-specific syphilitic serological test (WR) result was also negative.

Topical ocular treatment was introduced (Neomycin, Gramicidin with Fludrocortisone (Dicortineff, Polfa Warszawa), Diclofenac (Naclof, Novartis Pharma), periocular injections of Dexamethasone (Dexaven, Jelfa).

Ten days following the commencement of the antiinflammatory treatment, the vision in the LE decreased to 0.04. Systemic corticosteroids were administered.

In the meantime results of Treponemal-specific tests were obtained. The rapid plasma reagin test (RPR), the fluorescent treponemal antibody absorption tests (FTA, FTA-ABS) and the Treponema pallidum haemagglutination assay (TPHA) were all positive confirming active treponemal infection. Nuclear magnetic resonance of the cranium and orbits and other blood tests, including white blood count (WBC), C-reactive protein (CRP), autoimmune screening tests were negative. On base of these findings a diagnosis of bilateral syphilitic neuroretinitis was made.

During more detailed anamnesis the patient denied having had any skin or mucous lesions that might have been the primary syphilitic changes. He had had some rash on his palms and soles, but it had disappeared without any treatment. Because ocular syphilis tends to be associated with neurosyphilis, his cerebrospinal fluid (CSF) was also examined and showed no alterations. The following blood tests showed the patient was HIV, HBV and HCV negative.

The patient was treated with intramuscular injections of penicillin 2.4 mln U per day for 5 days followed by 1.2 mln U per day for total 26 days and the steroids were gradually tailed off.

The visual acuity improved to 0.6 in RE and 0.5 in LE after only three days of treatment. The papillary oedema remarkably reduced on the tenth day. After 6 months of follow up the visual acuity returned to 1.0 in both eyes. The fundoscopic changes completely resolved so did the pathological staining in the fluorescein angiography.

Discussion

Ocular syphilis may present different clinical forms, among which the most common are interstitial keratitis, uveitis, chorioretinitis, retinitis, retinal vasculitis and cranial nerve and optic neuropathies (4). Among patients with syphilis approximately 5% develop chorioretinitis and 50% of these are seen with bilateral lesions (5). Gass described the typical appearance of acute syphilitic chorioretinitis as large, placoid, yellowish lesions in the macula or mid-periphery of the fundus (6). A similar typical fluorescein angiography pattern of late staining was noted in our case.

Differential diagnosis of neuroretinitis include cat scratch disease, toxoplasmosis, ocular Lyme borreliosis, sarcoidosis, acute posterior multifocal placoid pigment epitheliopathy (AMPPE), birdshot retinochoroidopathy.

In diagnosis process it is essential to obtain positive specific serological test results for *Treponema pallidum*, because negative results of non-specific test do not exclude treponemal infection (7). As ocular syphilis is likely to coexist with neurological infection, therefore it is important to examine CSF once the diagnosis is made (3,4).

It is recommended, that all patients with newly diagnosed syphilis should be tested for HIV, as syphilis remains the most common bacterial eye infection in HIV-positive patients (8). Moreover the risk factors are similar for both diseases (3,4). Other sexually transmitted diseases should be tested as well, including antibodies against hepatitis virus types B and C.

In secondary syphilis after systemic treatment with antibiotic, the prognosis for visual recovery is good, although about 10% of cases have some lasting visual impairment.

As the prevalence of the treponemal infection has increased significantly in the last decade (7,9), it should always be considered in all patients with neuroretinitis.

Conclusions

This case shows how important it is to take syphilis into consideration in differential diagnosis of unexplained neuroretinitis. Treponemal-specific tests should be taken every time, even if non-specific syphilitic serological tests are negative. Once ocular syphilis is diagnosed, patient should be treated with penicillin, which can result in improvement of visual acuity.

References:

1. Kerani RP, Handsfield HH, Stenger MS, Shafii T, Zick E, Brewer D, Golden MR: *Rising rates of syphilis in the era of syphilis elimination*. Sex Transm Dis 2007, 34(3), 154-161.
2. Doris JP, Saha K, Jones NP, Sukthankar A: *Ocular syphilis: the new epidemic*. Eye (Lond) 2006, 20(6), 703-705.
3. Aldave AJ, King JA, Cunningham ET Jr.: *Ocular syphilis*. Curr Opin Ophthalmol 2001, 12(6), 433-441.
4. Kiss S, Damico FM, Young LH: *Ocular manifestations and treatment of syphilis*. Semin Ophthalmol 2005, 20(3), 161-167.
5. Morgan S, Laufer H: *Atypical syphilitic chorioretinitis and vasculitis*. Retina 1984, 4, 225-231.
6. Gass JD, Braunstein RA, Chenoweth RG: *Acute syphilitic posterior placoid chorioretinitis*. Ophthalmology 1990, 97(10), 1288-1297.
7. Gaudio PA: *Update on ocular syphilis*. Curr Opin Ophthalmol 2006, 17(6), 562-566.

8. Tran TH, Cassoux N, Bodaghi B, Fardeau C, Caumes E, Lehoang P: *Syphilitic uveitis in patients with human immunodeficiency virus*. Graefes Arch Clin Exp Ophthalmol 2005, 243(9), 863- 869.
9. Goh BT, van Voorst Vader PC: *European Branch of the International Union Against Sexually Transmitted Infection and the European Office of the World Health Organization*. European gu-

ideline for the management of syphilis. Int J STD AIDS 2001, 12 Suppl. 3, 14-26.

The study was originally received 12. 04.2011 (1299)/
Praca wpłynęła do Redakcji 12.04.2011 (1299)/
Accepted for publication 31.12.2011/
Zakwalifikowano do druku 31.12.2011 r.

Reprint requests to (Adres do korespondencji):

lek. med. Katarzyna Piasecka
ul. Jaracza 36A m. 12
90-252 Łódź
kkasiapiasecka@gmail.com



**STOWARZYSZENIE
ZWYRODNIENIA PŁAMKI ZWIĄZANEGO Z WIEKIEM (AMD)**
zaprasza na

VIII Sympozjum AMD

Termin
20 października 2012 r.
Miejsce
HOTEL MARRIOTT w Warszawie

Temat główny

„NOWE WYZWANIA W DIAGNOSTYCE I TERAPII CHOROÓB PŁAMKI”

- SESJA I WSKAZANIA REJESTRACYJNE DO TERAPII ANTY-VEGF**
- SESJA II PRAKTYCZNE POSTĘPOWANIE DIAGNOSTYCZNO-TERAPEUTYCZNE W WYBRANYCH CHOROBAH PŁAMKI – FORUM DYSKUSYJNE**
- SESJA III SUCHA POSTAĆ ZWYRODNIENIA PŁAMKI ZWIĄZANEGO Z WIEKIEM – NOWE MOŻLIWOŚCI TERAPII**
- SESJA IV DOSWIADCZENIA POLSKIE W TERAPII I DIAGNOSTYCE CHOROÓB PŁAMKI**

Szczegółowe informacje i rejestracja uczestników na stronie internetowej www.amd.org.pl

Biuro organizatora:
Stowarzyszenie AMD, Al. Waszyngtona 146/206, 04-076 Warszawa
mail: stoamd@op.pl, tel./fax: 22 515 80 01

Liczba miejsc ograniczona, decyduje kolejność zgłoszeń.

Prof. dr hab. n. med. Andrzej Stankiewicz


Przewodniczący Komitetu Organizacyjnego i Naukowego

STOWARZYSZENIE ZWYRODNIENIA PŁAMKI ZWIĄZANEGO Z WIEKIEM AMD

Stowarzyszenie AMD, Al. Waszyngtona 146/206, 04-076 Warszawa, tel./faks: (22) 515 80 01, tel. kom. 0 516 062 843,
REGON 015884929, NIP 113-265-85-01
Nr konta bankowego Deutsche Bank o/Warszawa NR 52 1910 1048 2214 9923 9402 0001
zarejestrowane przez Sąd Rejonowy dla m. st. Warszawy w Krajowym Rejestrze Sądowym - Rejestrze Stowarzyszeń,
innych Organizacji Społecznych i Zawodowych, Fundacji oraz Publicznych Zakładów Opieki Zdrowotnej pod numerem 215361