

(33) Imaging of Inflammatory Ocular Conditions with a Thermographic Camera

Obrazowanie stanów zapalnych gałki ocznej za pomocą kamery termograficznej

Anna Modrzejewska¹, Łukasz Cieszyński², Daniel Zaborski³, Mirosław Parafiniuk⁴

¹ First Department of Ophthalmology, Pomeranian Medical University, Szczecin, Poland

² Faculty of Computer Science and Information Technology, West Pomeranian University of Technology, Szczecin, Poland

³ Faculty of Biotechnology and Animal Husbandry, West Pomeranian University of Technology, Szczecin, Poland

⁴ Department of Forensic Medicine, Pomeranian Medical University, Szczecin, Poland

Head: Professor Mirosław Parafiniuk, MD, PhD

Abstract:

The aim of this study was to present our experience with using thermography as a complementary method for the initial diagnosis and differentiation of intraocular inflammation.

Methods: The study group comprised 160 patients with inflammation within the eye and the orbit: orbital inflammation (15), endophthalmitis (21), uveitis (26), keratitis (44) and conjunctivitis (54). Patients with keratitis and conjunctivitis were divided into subgroups with viral or bacterial infection.

A FLIR T640 camera was used to acquire images in the central point of the cornea, eye area and orbital cavity area.

Results: There was a significant difference between the median temperature of the eyes with endophthalmitis and conjunctivitis and normal eyes, and between the temperatures of eyes with all types of inflammation and normal eyes, in the central point of the cornea and the area of the eye. In the area of the orbit there was a significant difference between the median temperature of all orbital inflammations and normal eyes. There was a significant difference between the median temperature in the centre of the cornea of eyes with endophthalmitis and the eyes with keratitis. The greatest temperature difference was between the affected eye and normal eyes in patients with endophthalmitis and the lowest with keratitis.

Conclusions: A thermographic examination can be used as an additional first-line diagnostic tool differentiating intraocular inflammation. It provides objective and reproducible quantitative temperature data, and can be useful for assessing the severity of ocular inflammation, could help distinguish viral from bacterial inflammation, or uveitis from endophthalmitis.

Key words:

thermography, intraocular inflammation, orbital inflammation.

Abstrakt:

Celem tego badania było przedstawienie własnych doświadczeń z wykorzystaniem termografii jako uzupełniającej metody diagnozowania i różnicowania zapalenia wewnątrzgałkowego.

Metody: Badaną grupę stanowiło 160 pacjentów z zapaleniem gałki ocznej i oczodołu w tym: 15 z zapaleniem oczodołu, 21 z zapaleniem wnętrza gałki ocznej, 26 z zapaleniem błony naczyniowej oka, 44 z zapaleniem rogówki i 54 z zapaleniem spojówek. Pacjentów z zapaleniem rogówki i zapaleniem spojówek podzielono na dwie grupy - zakażenie wirusowe lub bakteryjne.

Do rejestrowania obrazów w centralnym punkcie rogówki, okolic oczu i okolic jamy oczodołu zastosowano kamerę FLIR T640.

Wyniki: Istniała znacząca różnica między średnią temperaturą oczu z zapaleniem wnętrza gałki ocznej i zapaleniem spojówek a średnią temperaturą zdrowego oka pacjenta, między temperaturami oczu ze wszystkimi typami zapalenia a oczami zdrowymi w centralnym punkcie źrenicy i okolicy oka. W obszarze jamy oczodołu istniała znacząca różnica między średnią temperaturą zmierzoną dla wszystkich stanów zapalnych oczodołu a normalnymi oczami. Porównanie stopnia i rodzaju zapalenia wykazało istotną różnicę między średnią temperaturą mierzoną w środku źrenicy oczu z zapaleniem wnętrza gałki ocznej a średnią temperaturą oczu z zapaleniem rogówki. Największa różnica temperatur występowała między chorym a normalnym okiem u pacjentów z zapaleniem wnętrza gałki ocznej. Najniższy gradient temperatury stwierdzono dla oczu z zapaleniem rogówki.

Wnioski: Badanie termograficzne oka może być wykorzystane jako dodatkowe narzędzie diagnostyczne pierwszego rzutu różnicujące zapalenie wewnątrzgałkowe. Dostarcza obiektywne i powtarzalne dane ilościowe dotyczące rozkładu i wartości temperatury i może być przydatne do oceny nasilenia zapalenia oka lub pomocne w odróżnieniu zapalenia wirusowego od bakteryjnego lub zapalenia błony naczyniowej oka od zapalenia wnętrza gałki ocznej.

Słowa kluczowe: termografia, zapalenie wewnątrzgałkowe, zapalenie oczodołu.

The authors declare no conflict of interest/ Autorzy zgłaszają brak konfliktu interesów w związku z publikowaną pracą

Introduction

Thermography is an imaging technique that detects infrared radiation emitted by various objects or human tissues. Radiation is emitted at temperatures above -273.15°C or 0°K , i.e. absolute zero (1). The measured temperature depends on the

blood supply and metabolism of the tissue, or the heat generated by the object.

The search for applications for the thermographic camera in medicine started in the early 20th century. Most studies concerned the use of this technique in oncological diagno-

stics (2, 3, 4). Attempts to use the thermographic camera in ophthalmology have been made for the imaging of retinal blood flow disorders (5), age-related macular degeneration (AMD) (6) and dry eye syndrome (7, 8). Tissues affected by these problems are characterized by low thermal emissivity. Scarce reports concern the use of thermal imaging in the diagnosis of conjunctivitis or inflammation of the posterior segment of the eye, characterized by increased ocular temperature (9, 10). The diagnosis of inflammatory ocular conditions relies mainly on the subjective assessment and experience of the investigator. Apart from microbiological tests, there are no other objective methods which can be used to confirm and differentiate inflammatory ocular conditions.

This paper presents our own experience with using thermography as a complementary method for the initial diagnosis and differentiation of inflammatory ocular conditions.

Material and methods

The analyzed group comprised 160 patients with inflammatory ocular conditions diagnosed based on a clinical examination in direct and indirect ophthalmoscopy, and imaging tests (ultrasound, magnetic resonance imaging). Among the examined patients 15 had orbital inflammation (Group 1), 21 had endophthalmitis (Group 2), 26 had anterior uveitis (Group 3), 44 had keratitis (Group 4), and 54 had conjunctivitis (Group 5). The characteristics of the groups are presented in Table I. In addition, keratitis and conjunctivitis were classified depending on the aetiology (bacterial or viral), based on direct ophthalmoscopy and morphological features of pathology.

An ophthalmic interview was conducted with the examined patients. Subjects with ophthalmological conditions such as glaucoma, dry eye syndrome and AMD, potentially distorting thermal emission measured on the eye surface, were excluded from the study. A FLIR T640 thermographic camera was used to acquire facial images (thermographic and optical) of each patient in 3 replications, perpendicularly to the examined area, 3 seconds after blinking, and at a distance of 1 m after resting for 15 minutes in the examination room. Room temperature and air humidity were relatively stable, and the examination room was isolated from external sources of heat, air conditioning or natural light. The protocol has been approved by the Bioethics Committee of the Medical University (Approval No. KB-0012/141/15).

The FLIR T640 camera has a 640×480 pixel detector, thermal sensitivity <30 mK (<0.03°C), spatial resolution 0.68 mrad, and measurement accuracy of ± 2%. Images were processed with ImageJ software for image analysis (https://imagej.nih.gov/ij/) and in the Matlab environment (https://www.mathworks.com). The following regions of interest were analysed: the central point of the pupil in the left and right eyes (point), left and right eyes (area) and left and right orbital cavities (area). The area of the eye was delineated manually after the superimposition of the thermographic image on the optical image, as the surface of the eye between eyelids (Fig. 1). The last area was delineated as an ellipse with a minor axis equal to a double distance between the centre of the pupil and the upper edge of the eye, and the major axis equal to 0.6 of the distance between the centre of the pupil and the left/right margin of the eye (Fig. 2) and superimposed onto the optical image (Fig 3).

For each analysed area we calculated median temperature (the parameter least affected by the minimum and maximum temperatures), and standard deviation. These values were determined for normal and affected eyes. The results of affected eyes were compared with patient’s other healthy eyes. The repeated measures multivariate analysis of variance (MANOVA) was used for data processing. Before the analysis the data were

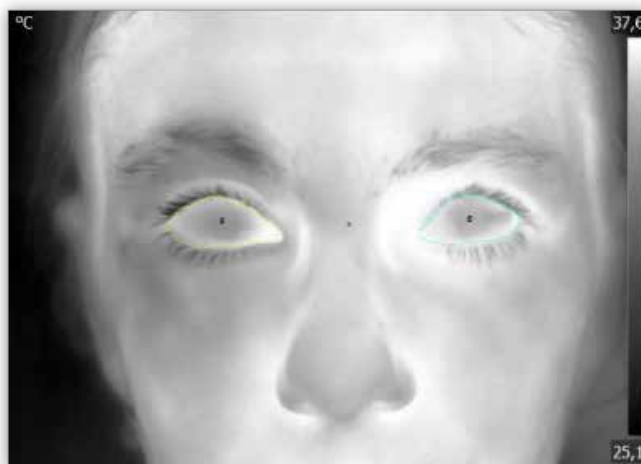


Fig. 1. The analyzed area of the eye was delineated as the surface between eyelids.

Ryc. 1. Badany obszar gałki ocznej obrysowany jako powierzchnia między powiekami.

Group	n	Age		Women		Men	
		Mean	SD	n	%	n	%
Orbital inflammation	15	61.07	18.23	8	53.33	7	46.67
Endophthalmitis	21	73.14	8.17	10	47.62	11	52.38
Uveitis	26	46.73	17.74	18	69.23	8	30.77
Keratitis	44	46.55	16.92	27	61.36	17	38.64
Conjunctivitis	54	47.93	17.55	29	53.70	25	46.30
Total	160	51.89	18.77	92	57.50	68	42.50

* Legend: n = number of patients, SD = standard deviation

Tab. I. Demographic characteristics of examined patients.

Tab. I. Dane demograficzne badanych pacjentów.

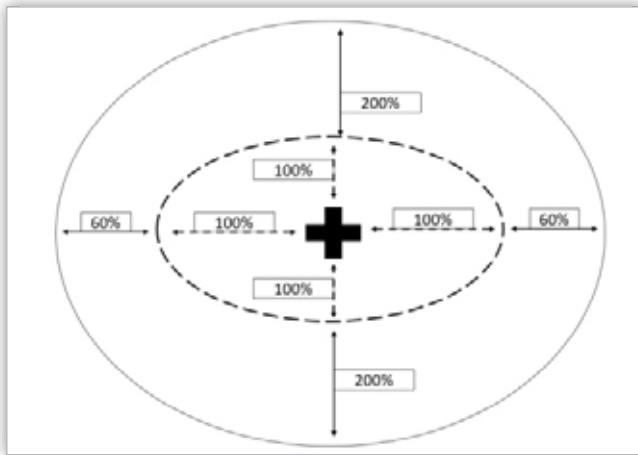


Fig. 2. Margins of the orbital cavity in the form of an ellipsoidal area.
Ryc. 2. Granice obszaru oczodołu w postaci elipsoidalnego pola.

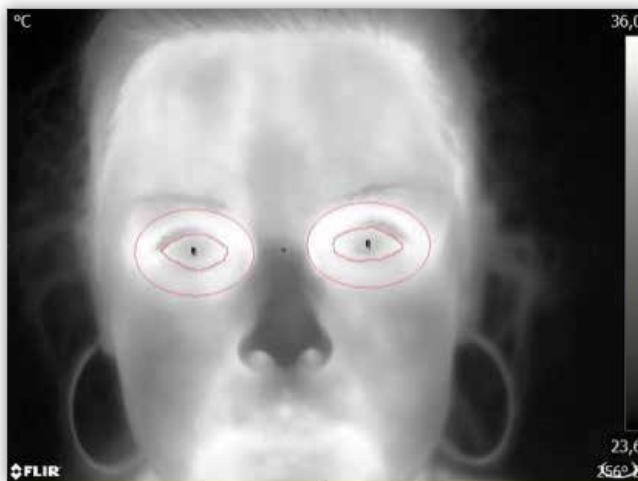

Fig. 3. Area of the orbital cavity was delineated on the optical image and superimposed on the thermal image.
Ryc. 3. Obszar oczodołu wyznaczony na zdjęciu optycznym i nałożony na zdjęcie termiczne.

transformed using the Box-Cox method in order to meet model assumptions (however, untransformed values are presented in the tables and text). Significant differences between groups in terms of the interaction effect (repeated measures \times disease type) were determined by contrast analysis (planned comparisons) and analysis of significance levels corrected according to the Dunn-Sidak method. All calculations were performed using Statistica software (ver.13, Dell Inc., Tulsa, OK, USA). Statistical significance was adopted at $P \leq 0.05$.

Results

Selected thermographic images are presented in Figures 4-8.

There was a significant difference between the median temperature of the eyes with endophthalmitis and conjunctivitis and the median temperature of the patient's normal eye measured in the central point of the pupil and the area of the eye. There was also a significant difference between temperatures of eyes with all types of inflammation and normal eye.

When the area of the orbital cavity was considered, a significant difference was found between the median temperature measured for all orbital inflammations and normal eyes.

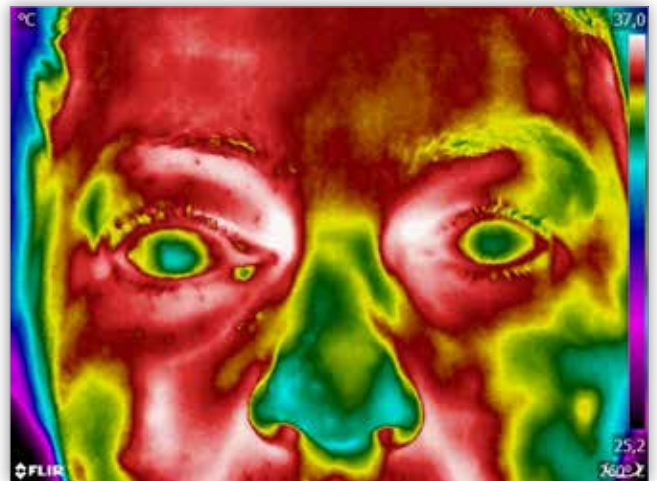


Fig. 4. Orbital inflammation of the right eye (on the left side).
Ryc. 4. Zapalenie prawego oczodołu (na zdjęciu po lewej stronie).

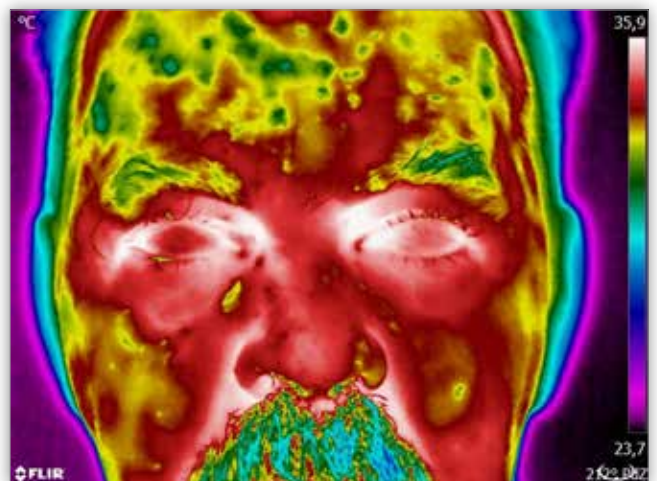


Fig. 5. Endophthalmitis of the left eye (on the right side).
Ryc. 5. Zapalenie wnętrza lewej gałki ocznej (na zdjęciu po prawej stronie).

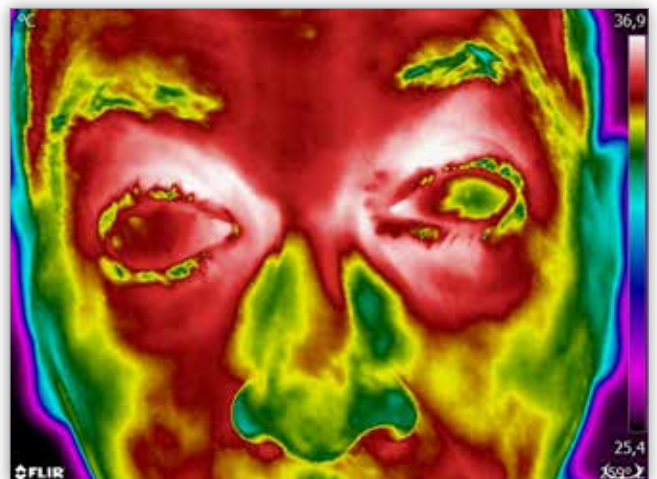


Fig. 6. Anterior uveitis of the right eye (on the left side).
Ryc. 6. Zapalenie przedniej części błony naczyniowej oka prawego (na zdjęciu po lewej stronie).

The comparison of the extent and type of inflammation revealed a significant difference between the median temperature measured in the centre of the pupil of eyes with endophthalmitis and the median temperature of eyes with keratitis (Table II).

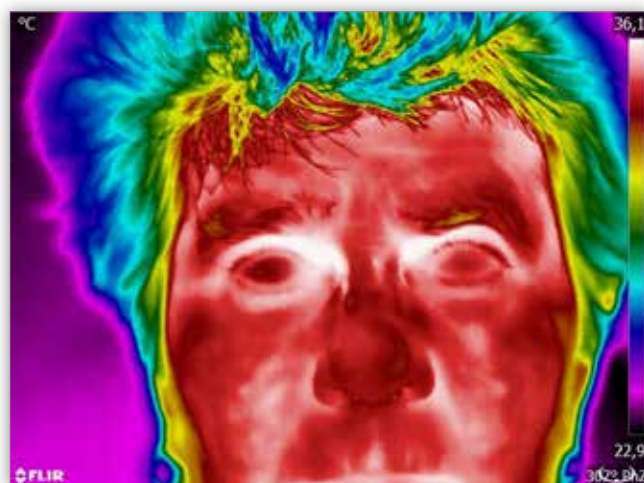


Fig. 7. Keratitis of the right eye (on the left side).
Ryc. 7. Zapalenie rogówki oka prawego (na zdjęciu po lewej stronie).

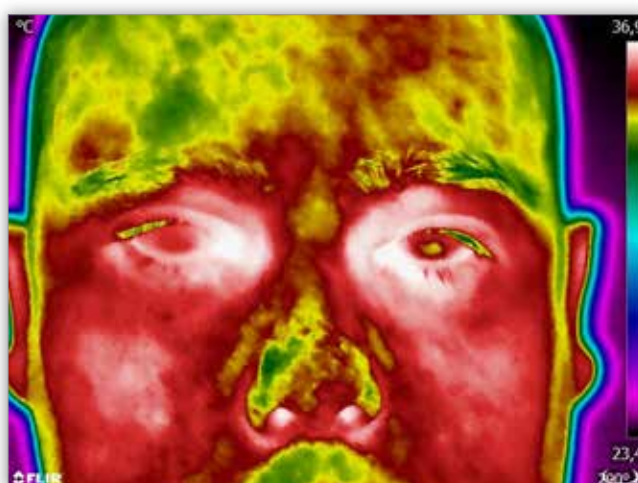


Fig. 8. Conjunctivitis of the right eye (on the left side).
Ryc. 8. Zapalenie spojówek oka prawego (na zdjęciu po lewej stronie).

Group	n	Mean	SD	Mean	SD
		AFFECTED		NORMAL	
Central point of the pupil					
Orbital inflammation	15	33.96	2.09	33.31	1.55
Endophthalmitis	21	35.27^{Aa}	1.24	34.04^B	0.87
Uveitis	26	34.40	1.19	33.80	1.22
Keratitis	44	34.13^b	1.55	34.02	1.44
Conjunctivitis	54	34.72^A	1.35	34.21^B	1.04
TOTAL	160	34.51^A	1.49	33.98^B	1.24
Eye					
Orbital inflammation	15	34.71	1.67	34.21	1.26
Endophthalmitis	21	35.80^A	1.01	34.57^B	0.76
Uveitis	26	35.20	1.02	34.72	1.10
Keratitis	44	34.92	1.31	34.73	1.32
Conjunctivitis	54	35.47^A	1.03	34.83^B	0.86
TOTAL	160	35.24^A	1.21	34.69^B	1.07
Orbital cavity					
Orbital inflammation	15	35.03	1.28	34.40	1.11
Endophthalmitis	21	35.11	0.99	34.34	0.97
Uveitis	26	35.30	0.89	34.89	1.08
Keratitis	44	35.12	0.82	34.83	1.00
Conjunctivitis	54	35.18	0.84	34.71	0.74
TOTAL	160	35.16^A	0.90	34.70^B	0.95

^{a,b} – different small superscript letters in columns denote statistically significant differences at P≤0.05
^{A,B} – different capital superscript letters in rows denote statistically significant differences at P≤0.05
n – number of patients, SD – standard deviation

Tab. II. Mean temperatures measured for normal and affected eyes in the same patient, depending on the area of interest and disease type.
Tab. II. Wartości średnich temperatur w zdrowych i chorych oczach tych samych pacjentów w zależności od regionu zainteresowania i rodzaju choroby.

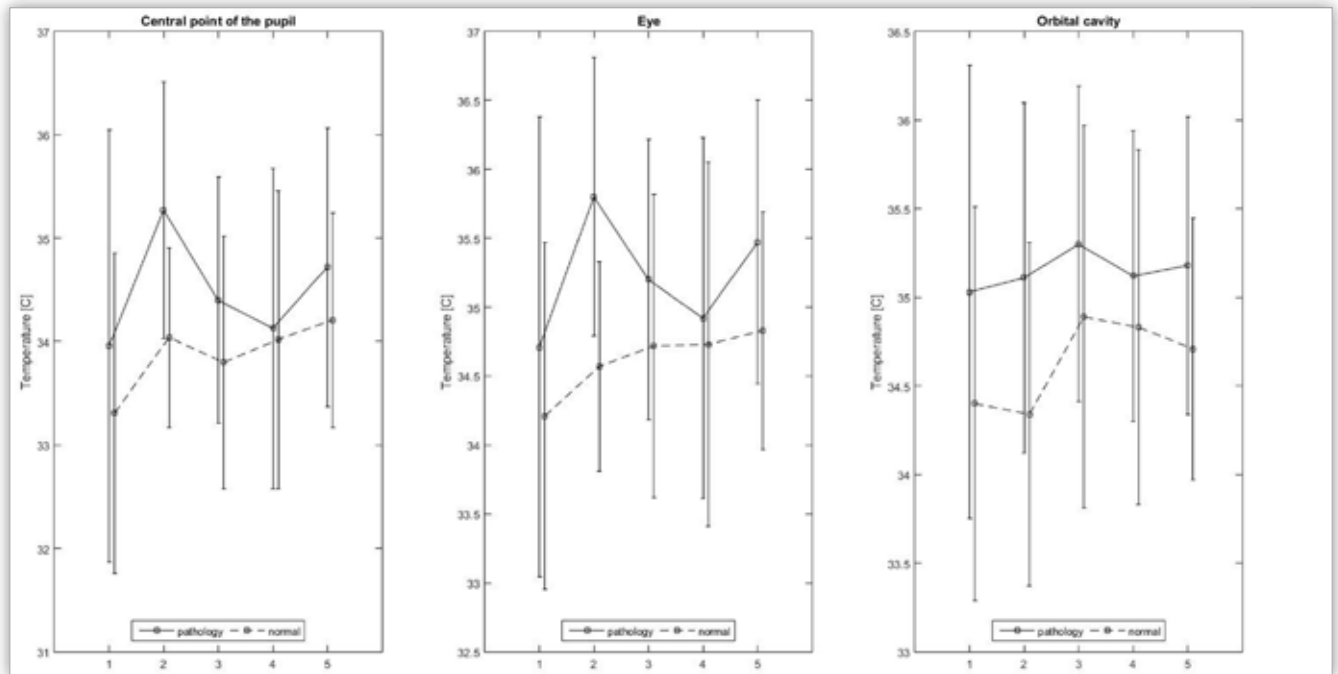


Fig. 9. Differences in temperatures of examined areas.
Ryc. 9. Różnice temperatur w badanych obszarach.

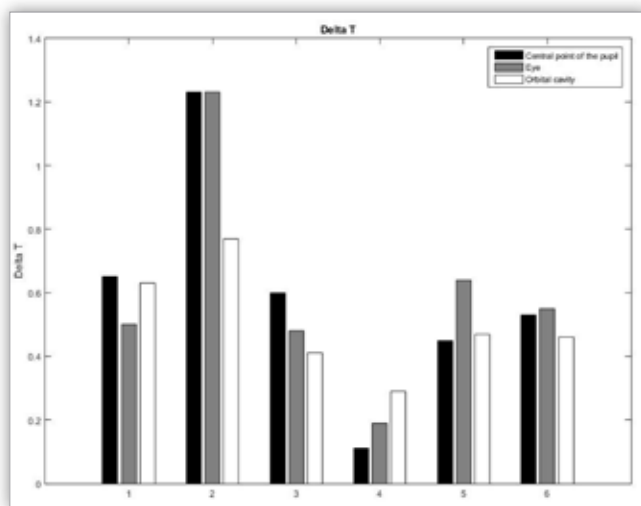


Fig. 10. The difference between mean temperatures of affected eyes and normal eyes (delta T) in particular types of inflammation.
Ryc. 10. Różnica między średnią wartością temperatury oka z patologią w stosunku do oka zdrowego (delta T) w poszczególnych typach zapalenia.

Differences in temperatures of examined areas are presented in Figure 9.

The difference between mean temperatures of affected eyes and normal eyes (delta T) in particular types of inflammation was calculated. There was a marked difference in temperature between the affected eye and normal eye in patients with endophthalmitis (1.23°C in the pupil and the eye area). This was the greatest temperature difference considering all types of inflammation. The lowest temperature gradient was found for the eyes with keratitis (0.11°C for the central point of the pupil, 0.19°C for the area of the eye, and 0.29°C for the orbital cavity) (Fig. 10).

Infectious keratitis and conjunctivitis were classified to those of bacterial and viral aetiology. There were no significant differences between the types of inflammation in individual examined areas (Table III). However, the average median temperature for eyes with bacterial keratitis was higher than that for eyes with viral keratitis, and the average median temperature for eyes with bacterial conjunctivitis was lower than that for viral conjunctivitis.

Group	Median	Bacterial			Viral		
		n	Mean	SD	n	Mean	SD
Keratitis	Central point of the pupil	25	34.29	1.45	19	33.91	1.69
	Eye	25	35.01	1.25	19	34.79	1.40
	Orbital cavity	25	35.19	0.85	19	35.02	0.80
Conjunctivitis	Central point of the pupil	36	34.56	1.50	19	35.03	0.92
	Eye	36	35.36	1.18	19	35.72	0.63
	Orbital cavity	36	35.24	0.97	19	35.18	0.73

n – number of patients, SD – standard deviation
 There was no statistically significant differences ($P \leq 0.05$).

Tab. III. Median temperatures of the affected eye with bacterial vs viral infection.

Tab. III. Porównanie mediany temperatury oka chorego w grupie zakażeń bakteryjnych i wirusowych.

Discussion

An infectious agent triggering inflammation is recognized by macrophages and mast cells, which produce proinflammatory chemokines and cytokines. These mediators promote a local increase in the exudation of fluid and transport of plasma proteins and leukocytes to the inflammatory site (11). Moreover, the increased metabolic activity of the tissue leads to the accumulation of carbon dioxide, prostaglandins and other metabolites, followed by local vasodilatation, increased blood flow and vascular permeability at the site of inflammation (12, 13).

Hyperaemia resulting from the dilation of arterioles and increased tissue catabolism causes a significant increase in local temperature. Thermography allows for the registration of this temperature, and is a tool for the analysis of mechanisms of thermoregulation, detecting areas of tissues with altered metabolism and inflammatory response (14).

Reports on thermographic imaging in ocular inflammations are limited. For example, a study by Rushton et al. investigating changes in the ocular surface temperature in horses with uveitis demonstrated about a 2°C higher temperature of the affected eye compared to the normal eye. The researchers also found that thermographic measurement was less distorted by the ambient conditions compared to measurements taken with a thermometer (15).

Another study concerned a thermographic assessment of corneal ulcers. Klamann et al. reported that the mean temperature measured with a thermographic camera (35.6°C) was approx. 0.8°C higher in the eye with bacterial corneal ulcers compared to the normal eye. A close correlation between the mean temperature at the base of the corneal ulcer and the overall corneal temperature was also found (16).

The present study showed an increase in the surface temperature of the eyes with keratitis, but the gradient of increase was the lowest considering all types of inflammations (0.11°C for the central point of the pupil and 0.19°C for the area of the eye). Compared to other areas of interest, the temperature at the central point of the pupil was also the lowest for keratitis (34.13°C vs 34.92°C at the area of the eye).

Significantly higher temperatures of the eye were also measured in patients with conjunctivitis (mean 34.72°C for the central point of the pupil and 35.47°C for the area of the eye).

The mean temperature of the eye with conjunctivitis was also lower in the central point of the pupil than on the whole ocular surface. Probably, tear film instability in the eyes with conjunctivitis and keratitis, as well as in dry eye syndrome, is responsible for lower corneal surface temperature and lower temperature at the central point of the pupil (7). This implies the important role of viral and bacterial inflammations and toxic metabolites thereof, and topical medications used for the treatment of tear film instability, thereby causing symptoms of dryness and irritation (17). Another possible explanation is the absence of vascularization in the corneal area.

The lowest temperature in our study was measured for the eyes with orbital inflammation. The lack of significant differences and comparable temperatures measured in the orbital cavity in eyes with different inflammations may suggest that there are many other factors influencing the temperature of this ocular area. The soft tissues, fat and orbital bones located un-

der the anatomical structure for which surface temperature is measured can distort the precise temperature of the surface of the eye. Apparently, conclusions on the pathologies of the eye cannot be made based on the analysis of measurements taken for the orbital cavity.

The present study revealed the most significant temperature difference and highest temperatures in all areas of interest in eyes with endophthalmitis. This may be due to the fact that endophthalmitis is usually a serious inflammation that affects all eye membranes and leads to considerable tissue damage. The mean temperature was 35.27°C at the central point of the pupil and 35.8°C on the eye surface, and these values were highest compared to measurements taken for all types of inflammation. The temperature gradient between the affected eye and normal eye of the same patient was also the greatest ($\Delta T = 1.23^\circ\text{C}$) and clearly differed from the temperature gradient found in eyes with anterior uveitis (0.6°C for the central point of the pupil and 0.48°C for the ocular surface).

Endophthalmitis is diagnosed only on the basis of ophthalmoscopic examination, while ultrasonography evaluating the inflammatory exudate in the vitreous body may be used as an additional test. Both these tests are highly subjective and require an experienced investigator. Therefore, the risk of human error exists, and endophthalmitis may be misdiagnosed for anterior uveitis. Thermographic examination allows for an objective and quantitative distinction between these two diseases. This technique can be particularly useful when examining non-translucent optical structures (cloudy or swollen cornea, narrow pupil with adhesions).

Although microbiological culture is recommended in patients with ocular inflammation (18), it is usually not performed as a routine procedure for economic reasons and low availability of equipment, media, as well as lack of access to a microbiological laboratory (19, 20). Diagnosis relies on findings from a direct observation using a slit lamp (21), while recommended treatment is usually based on the subjective interpretation of clinical symptoms of inflammation (22, 23).

A thermographic examination of the eye can be used as an additional first-line diagnostic tool differentiating inflammation within the eye. This non-invasive examination provides objective and reproducible quantitative data on the distribution and value of temperature, and can be useful for assessing the severity of ocular inflammation. At the early stage of disease thermography could help determine whether the recommended treatment is appropriate or should be modified (24, 25), and could also help distinguish viral from bacterial inflammation, or uveitis from endophthalmitis. An increase in temperature is a primary characteristic of ocular inflammation and may be a useful parameter when investigating ocular pathophysiology.

References:

1. Usamentiaga R, Venegas P, Guerediaga J, Vega L, Molleda J, Bulnes FG: *Infrared Thermography for Temperature Measurement and Non-Destructive Testing*. Sensors. 2014; 14(7): 12305–12348.
2. Zadeh HG, Haddadnia J, Ahmadinejad N, Baghdadi MR: *Assessing the Potential of Thermal Imaging in Recognition of Breast Cancer*. Breast Care (Basel). 2015; 16(18): 8619–8623.

3. Madhu H, Kakileti ST, Venkataramani K, Jabbireddy S: *Extraction of medically interpretable features for classification of malignancy in breast thermography*. ConfProc IEEE Eng Med Biol Soc. 2016; 2016: 1062–1065.
4. Stroszczyński C, Hosten N, Bornfeld N, Wiegel T, Schueler A, Foerster P, et al.: *Choroidal Hemangioma: MR Findings and Differentiation from Uveal Melanoma*. AJNR Am J Neuroradiol. 1998; 19: 1441–1447.
5. Mapstone R: *Ocular thermography*. Br J Ophthalmol. 1970; 54: 751–754.
6. Sodi A, Matteoli S, Giacomelli G, Finocchio L, Corvi A, Menchini U: *Ocular Surface Temperature in Age-Related Macular Degeneration*. Journal of Ophthalmology. 2014; 2014: 281010.
7. Żelichowska B, Różycki R, Tłustochowicz M, Kujawa A, Kalicki B, Murawski P: *Przydatność termografii w diagnostyce zespołu suchego oka*. Klin Oczna. 2005; Wyd. 7–9/2005.
8. Azharuddin M, Bera SK, Datta H, Dasgupta AK: *Thermal fluctuation based study of aqueous deficient dry eyes by non-invasive thermal imaging*. Exp Eye Res. 2014; 120: 97–102.
9. Klamann MKJ, Maier AK, Gonnermann J, Klein JP, Bertelmann E, Pleyer U: *Ocular surface temperature gradient is increased in eyes with bacterial corneal ulcers*. Ophthalmic Res. 2013; 49: 52–56.
10. Kawali AA: *Thermography in ocular inflammation*. Indian J Radiol Imaging. 2013; 23(3): 281–283.
11. Medzhitov R: *Origin and physiological roles of inflammation*. Nature. 2008; 24; 454(7203): 428–435.
12. Mosier DA: *Chapter 2 – Vascular Disorders and Thrombosis*. Pathologic Basis of Veterinary Disease (Sixth Edition). 2017; 44–72.
13. Vadas P, Wasi S, Movat HZ, Hay JB: *Extracellular phospholipase A2 mediates inflammatory hyperaemia*. Nature. 1981; 15–21; 293(5833): 583–585.
14. Jiang LJ, Ng EYK, Yeo ACB, et al.: *A perspective on medical infrared imaging*. Journal of Medical Engineering and Technology. 2005; 29(6): 257–267.
15. Rushton JO, Tichy A, Nell B: *Introduction of the use of thermography and thermometry in the diagnosis of uveitis in horses: a pilot project*. Vet Rec Open. 2015; 27; 2(1):e000089.
16. Klamann MK, Maier AK, Gonnermann J, Klein JP, Bertelmann E, Pleyer U: *Ocular surface temperature gradient is increased in eyes with bacterial corneal ulcers*. Ophthalmic Res. 2013; 49(1): 52–56.
17. Huang T, Wang Y, Liu Z, Wang T, Chen J: *Investigation of tear film change after recovery from acute conjunctivitis*. Cornea. 2007; 26(7): 778–781.
18. Jones DB: *Decision-making in the management of microbial keratitis*. Ophthalmology 1981; 88: 814–820.
19. Pepose JS, Wilhelmus KR: *Divergent approaches to the management of corneal ulcers*. Am J Ophthalmol. 1992; 114: 630–632.
20. McDonnell PJ: *Empirical or culture-guided therapy for microbial keratitis? A plea for data*. Arch Ophthalmol. 1996; 114: 84–87.
21. Rietveld RP, ter Riet G, Bindels PJ, et al.: *Predicting bacterial cause in infectious conjunctivitis: cohort study on informativeness of combinations of signs and symptoms*. BMJ, 2004; 329: 206–210.
22. Seal DV, Barrett SP, McGill JI: *Aetiology and treatment of acute bacterial infection of the external eye*. Br J Ophthalmol. 1982; 66: 357–360.
23. Saini JS, Jain AK, Kumar S, et al.: *Neural network approach to classify infective keratitis*. Curr Eye Res. 2003; 27: 111–116.
24. Kawali AA: *Thermography in ocular inflammation*. Indian J Radiol Imaging. 2013; 23(3): 281–283.
25. Mapstone R: *Corneal thermal patterns in anterior uveitis*. Br J Ophthalmol. 1968; 52(12): 917–921.

The paper was originally received 09.11.2019 (KO-00224-2019)/
Praca wpłynęła do Redakcji 09.11.2019 (KO-00224-2018)
Accepted for publication 02.12.2019/
Zakwalifikowano do druku 02.12.2019

Corresponding author (Autor korespondencyjny):

Anna Modrzejewska MD
I Department of Ophthalmology, Pomeranian Medical University
al. Powstańców Wielkopolskich 72
70-110 Szczecin, Poland
Phone: 0048914661296, E-mail: ania_modrzej@o2.pl